

# SURGE



AMERICAN ACADEMY  
OF COSMETIC SURGERY



## Members on a Mission

Answering the Call in Colombia,  
Haiti, and Nicaragua



Procedural Discussion:  
Cosmetic Blepharoplasty Part 2



International Update:  
Cosmetic Surgery in Greece

# Cosmetic Blepharoplasty Part 2

In the previous issue of *SURGE* we discussed upper eyelid blepharoplasty and this issue will cosmetic blepharoplasty of the lower eyelid complex.

## LOWER LID AGING

Midfacial aging becomes noticeable in the later third and early fourth decade. Isolated hereditary lower eyelid fat prolapse can occur much earlier. The lower eyelid complex blends seamlessly with the midface and lower eyelid rejuvenation comprehensively includes midfacial and or nasojugal augmentation.

Lower eyelid aging changes are consistent and similar to upper eyelid aging. Dermatochalasia from aging and actinic damage is manifested by excess and "crinkly" lower eyelid skin. This skin is among the thinnest in the body and can be 0.2 mm thick, making it very susceptible to aging changes. As with the upper lids, the lower orbital septum weakens with age and allows prolapse or protrusion of the three lower fat pads. This in itself produces sausage shaped fat that makes patients look older and tired. The actual protruding fat can cast shadows (especially in overhead light) along the inferior orbital rim which compounds the old and tired look. Compounding the dark circle look are true color changes from actinic or hereditary pigmentation or hemosiderin leakage. The aging changes in skin, fat, muscle and connective tissues produces an accentuated nasojugal groove producing the tear trough deformity. Suspensory laxity changes the position of the canthi and can produce canthal rounding, ectropion and scleral show. Figure 1 shows typical lower lid aging changes.

The submalar regions being closely associated with the lower lids can enhance or detract lower lid aesthetics and I almost always recommend some form of midfacial volumization when performing lower lid blepharoplasty.



## Procedural discussion...

Joseph Niamtu III, DMD

Presurgical considerations are the same as outlined in the previous article on upper blepharoplasty. Patients must be screened from normal platelet and coagulation function. Lower lid tension or laxity is also critical to lower blepharoplasty success. Performing skin or muscle resection or skin on a lax lower eyelid can be disastrous in terms of aesthetics and function and many

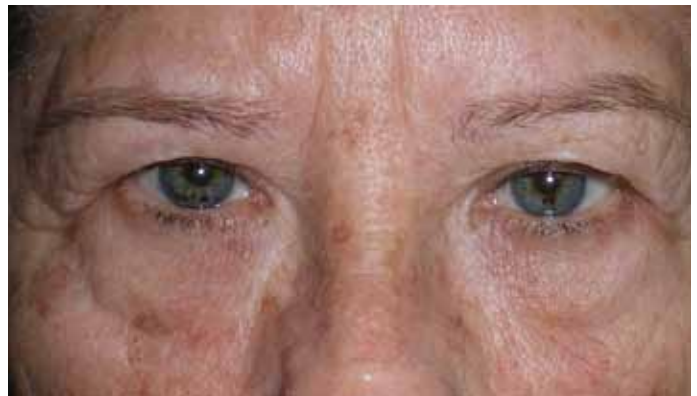

Figure 1. This image shows typical upper and lower eyelid aging changes. Reducing fat protrusion and rejuvenating the damaged skin are the goals of lower lid blepharoplasty.

oculoplastic surgeons spend a large amount of time fixing cosmetic surgical mishaps from surgeons that do not appreciate the importance of lower lid laxity. Lower eyelid laxity is generally evaluated by the "snap" and "Pull" tests. In the snap test the lower lid is pulled inferiorly and should return to normal position within a second (figure 2 Upper). The pull test is performed by retracting the lower lid away from the globe in the horizontal plane. A normal lower lid should not be able to be pulled more than 7mm away from the globe (figure 2 Lower). A retarded return to normal position or a non return to normal position can indicate problems ahead. These patients should absolutely be avoided by surgeons not skilled in canthopexy. Novice surgeons should avoid operating on loose lower eyelids and have skilled referral sources for this population.

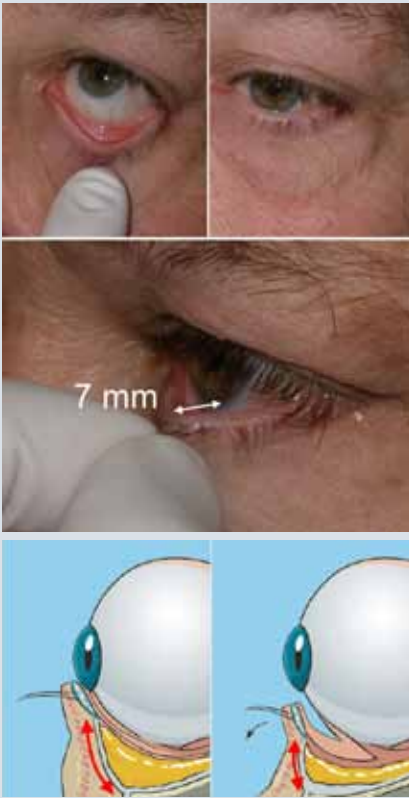


Figure 2. Figure 2 (upper image) shows a normal snap test where the lower lid is pulled inferiorly and returns to normal position within a second. Figure 2 (lower) shows the upper limits of a normal pull test where the lower lid should not be able to be retracted more than 7-8 mm from the globe. Excess in either of these tests may indicate lower lid laxity.

Figure 3. This image shows normal lower lid position and lower lid malposition from septal retraction which can be common in subciliary skin/muscle procedures that violate the orbital septum.

## AS WITH THE PROCEDURAL DECISION MAKING

The basis of traditional lower lid rejuvenation includes

- Subciliary external approach with skin/muscle resection
- Transconjunctival approach with skin resurfacing (chemical peel or laser resurfacing) or skin pinch.
- Transconjunctival approach with periorbital fat repositioning.

Each patient presents a different list of problems that may or may not respond to various treatment. I prefer the transconjunctival for 99% of my lower eyelid procedures because I feel that it is safer and more predictable in terms of preventing lower lid malposition. My only use of subciliary skin muscle approach is in patients with significant orbicularis hypertrophy. Most transconjunctival blepharoplasty is performed in a retroseptal manner which preserves the middle lamella

and lessens the chance of septal contraction which can produce ectropion and scleral show (figure 3).

The transconjunctival (TC) approach requires (in most cases) a separate procedure to address skin excess and quality. My number one recommendation is a combination of TC blepharoplasty with simultaneous CO2 laser resurfacing. The advantage of aggressive laser treatment of the lower lids is that new skin is produced. This means not just stretched skin as seen with skin resection procedures, but new, youthful, tight skin without aging pigment results. The drawback of aggressive CO2 laser treatment is the initial recovery of 10-12 days and the secondary pinkness that follows. I have had my own lower lids lasered this year and can attest to both the extended recovery and the excellent improvement of dermatochalasis and dyschromia. For patients that cannot make the recovery sacrifice of laser, a 30% TCA peel produces good improvement with about half of the recovery.

For patients that decide against resurfacing, a skin pinch procedure can improve lower lid skin without middle lamellar contraction, but skin pinch in itself can produce lower lid malposition if performed too aggressively.

## TRANSCONJUNCTIVAL LOWER BLEPHAROPLASTY TECHNIQUE

This procedure can be performed with local anesthesia although I always use IV sedation. The TC lower blepharoplasty is performed by first injecting 1 ml of 2% lidocaine with 1:100,000 epinephrine split equally into the three lower fat pads. The needle is pointed towards the orbital rim and away from the globe.

I most commonly use the 0.2 mm CO2 laser handpiece (Lumenis Inc, Santa Clara, California) for incision but also interchangeably use radiowave microneedle (Ellman International, Oceanside, NY). Proper corneal protection is absolute and stainless steel shields are used for laser treatment while plastic shields are used for electric based devices. I prefer these bloodless incisional modalities and my total blood loss is less than a ml/eyelid. Less bleeding means a clearer surgical field and hence more precision surgery, less bruising and pain and faster recovery.

The incision is made through the conjunctiva and capsulopalpebral fascia (lower lid retractors) from the lacrimal punctum to the lateral canthus (figure 4). Extension to the lateral canthus assists in access to the lateral fat pad, which is the most difficult to treat via this approach. A 5-0 gut suture is placed on the superior conjunctiva and attached to a hemostat which is draped over the head to assist in retracting the incision. Gentle pressure is placed on the globe (retropulsion) with a Jager lid plate which causes the fat pads to bulge into the incision (figure 5). If the fat pads do not readily appear into the surgical field, blunt dissection with micro hemostat or cotton tipped applicators is used to gently spread the tissues until the fat pads can be visualized. Generally the central fat pad is most easily accessed. The pad is gently elevated with a small pick up and using the laser or radiowave microneedle, the base of the fat pad is incised. Defocusing the laser (to increase the spot size) or using the radiowave needle on pure coagulation provides adequate hemostasis (figure 6). This can also be performed with a micro radiofrequency bipolar forceps. If non hemostatic incision modalities (scalpel or scissors) are used, a micro hemostat is first used to clamp the base of the fat pad and the excess fat is cut above the clamp, then the incised portion is cauterized prior to removing the clamp. It is important not to use excessive traction when handling the fat pad if they are excessively retracted, a vessel laceration can occur which can retract back into the orbit and be extremely difficult to control. Retrobulbar hematoma can cause blindness and exacting hemostasis should also be performed. In the case of uncontrolled bleeding, a small suction and micro bipolar forceps are used to locate and cauterize the offending vessel. In the case of uncontrollable bleeding, proptotic globe or suspected retrobulbar hematoma, a lateral canthotomy is performed and emergent oculoplastic or ophthalmologic consultation is obtained.

After the central fat pad is reduced and recontoured, the medial (nasal) fat pad is similarly uncovered and treated. This pad can be elusive and sometimes requires significant micro dissection to identify. The inferior oblique muscle separates the medial (nasal) from the central fat pad and can serve as a landmark in find the medial pad. The medial fat pad is frequently white colored fat as

opposed to the yellow color of the neighboring fat pads. Finally, the lateral fat pad is addressed. This is the most often overlooked and under treated pad and inexperienced surgeons may leave a protruding bulge visible through the skin, which will require revision. It takes some exploring to expose the offending lateral fat pad. Retracting the incision with multiple skin hooks near the lateral canthal can assist in locating the lateral fat pad. As the fat is

Post operative care consists ice or cold compresses for the first 48 hours, then heat after this period if desired.

This article is only a synopsis of popular blepharoplasty technique and does not represent all available options options. As with any procedure, various surgeons prefer various approaches. The TC approach with simultaneous lower lid skin resurfacing has proved

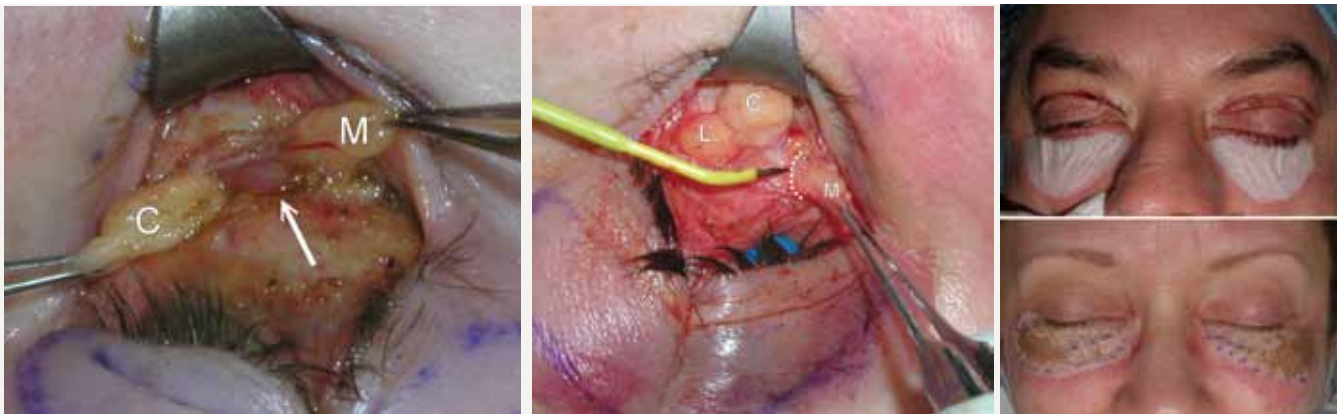


Figure 4. Figure 4 (left) shows the approximate transconjunctival approach to the lower periorbital fat pads and the right sided figure shows the position on a patient. Figure 5. This image shows the "surgeons view" of lower transconjunctival blepharoplasty. The central fat pad is shown as "C" and the medial fat pad is shown as "M". The white arrow points the inferior oblique muscle that separates these two fat compartments. Figure 6. A radio-wave microneedle is used on the pure coagulation mode to incise the base of a medial fat pad. The central (C) and lateral (L) fat pads are also shown.

reduced, the incision is redraped to make sure the offending bulge has been reduced.

It is imperative to be conservative when removing any fat from the eyelid. Removing a little less than you think is required is generally a good rule of surgery. Orbital hollowness is no trade off for cosmetic blepharoplasty.

TC blepharoplasty incision does not require suturing as an eyelid with normal tension will passively approximate the incision margins with normal healing. If laser or radiowave surgery is used, a moist cotton tipped applicator is used to wipe the incision margins to remove any char that might abrade the cornea.

Since the TC approach does not address the lower lid skin, concomitant procedures are used. I prefer high fluence, high density, multipass CO2 laser (figure 7). This makes new skin which not only addresses wrinkling but also pigment changes. The result is excellent, but the recovery is almost 2 weeks, which is prohibitive for some patients. 30% TCA (trichloroacetic acid) is an alternative to laser treatment. It generally produces a good result with half the downtime of the laser. If resurfacing is not an option, a skin pinch procedure can be utilized. In the procedure, a hemostat is used to pinch several millimeters (about half of the amount of skin you think need removed!) of lower lid skin just below the ciliary margin.

Patients are warned to refrain from any significant activity that will increase blood pressure or cause Valsalva compression. It is imperative for post blepharoplasty patients to realize that over activity could result in severe complications, including blindness.

to be a safe and effective procedure in my practice for the past 13 years. Figures 8-10 show before and after images of lower eyelid blepharoplasty using the transconjunctival approach with skin resurfacing. ■

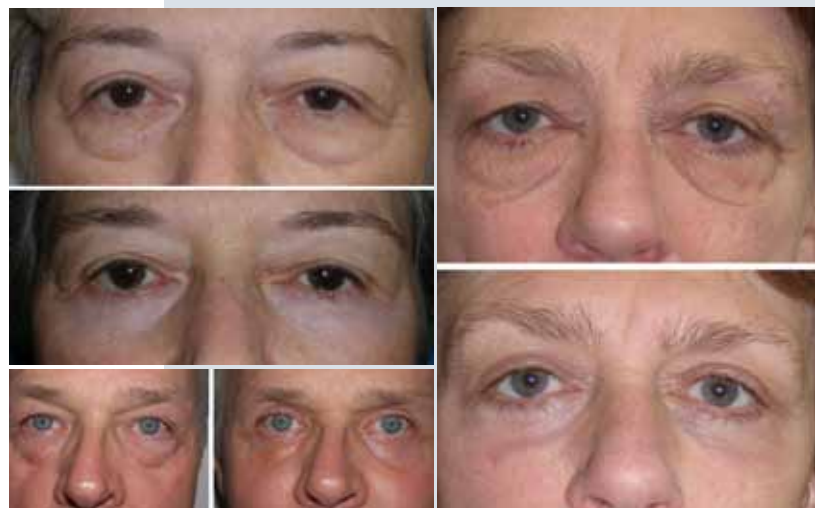

Figure 7. The top figure shows lower eyelid CO2 laser resurfacing performed after TC blepharoplasty. The bottom image shows another patient treated with 30% TCA peel

Figure 8. This patient was treated (lower lids only) with TC blepharoplasty and multipass CO2 laser resurfacing.

Figure 9. This patient was treated with upper blepharoplasty, lower TC blepharoplasty and multipass CO2 laser resurfacing.

Figure 10. This male patient was treated with upper blepharoplasty and lower TC bleph with multipass CO2 laser resurfacing.