

SURGERY



THE

REVISION

DECISION

There are numerous reasons for revision surgeries, ranging from a problematic first procedure to unrealistic patient expectations to unpredictable healing



Tips to Avoiding Unhappy Patients



Health Care Reform – Back on Center Stage



Procedural discussion...

Joseph Niamtu III, DMD

Facelift: Part II

In the last issue of *SURGE*, I outlined my approach to the short scar facelift technique. Obviously, the writings of any author express his or her opinion and approaches and are not meant to be last-word dogma, but rather a compilation of pearls that has been accrued with experience.

In my experience, it is rare that patients perform isolated facelift surgery, and more often have multiple simultaneous aesthetic procedures with the lift (although I believe the current economy has affected this). It is not uncommon for patients to undergo blepharoplasty, brow lift, facial implants or laser skin resurfacing with the facelift. I personally perform the more precision-oriented procedures, such as blepharoplasty, at the beginning of the case. This is followed by browlift. The chin implant is placed through the platysmaplasty incision, and the cheek implants are performed after the facelift. Concomitant laser skin resurfacing is performed last. Simultaneous laser and facelift should only be performed by surgeons with significant experience with both modalities.

As previously stated, many surgeons do not perform platysmaplasty or submentoplasty with short scar procedures, but I always perform these procedures with standard facelifts. At different times in my career, I have abandoned platysmaplasty and feel that not doing it was a mistake. I can attest, after almost 700 facelifts, that patients will get a tighter, longer-lasting result when the neck and submental regions are addressed.

I begin the facelift procedure by infiltrating about 100 ml of tumescent solution (0.1 percent lidocaine) with 1:333,333 epinephrine (made by adding 50 mg of 1 percent lidocaine and 1.5 mg of 1:1000 epinephrine to 500 ml of normal saline). 100 ml is injected in the submental and anterior cervical region, and 100 ml is also injected in each pre-and post-auricular region.

A 3-4 cm incision is made several millimeters below the submental crease to the subcutaneous plane. Liposuction is performed commensurate with the amount of fat present in these areas. At this point, a lipocutaneous flap is raised by undermining the anterior submental and cervical skin with facelift scissors.

Further liposculpting can be performed under direct vision. Lighted retractors can greatly simplify the performance of this procedure. I personally perform a simple corset platysmaplasty by using buried sutures from the thyroid region to the inferior border of the mandible (figure 1). Although many surgeons perform horizontal skin cutbacks on the platysma, I do not. If a chin implant is to be performed, it is

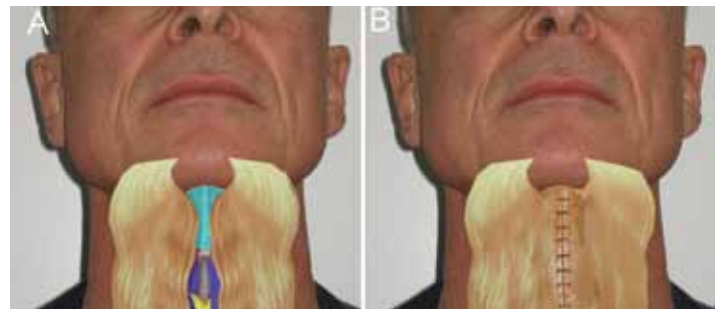


Figure 1. This image shows a rendition of midline platysma repair.

placed through this incision before the platysmaplasty so as not to disturb the sutured muscle repair. In the discussion of the short scar (“weekend facelift”), the incision approach to the anterior incision applies to more comprehensive facelifts and is essentially the same.

The posterior incision varies on the amount of submental and neck skin present. The most aesthetic posterior incisions are those which are best hidden by the pinna and posterior hairline. In

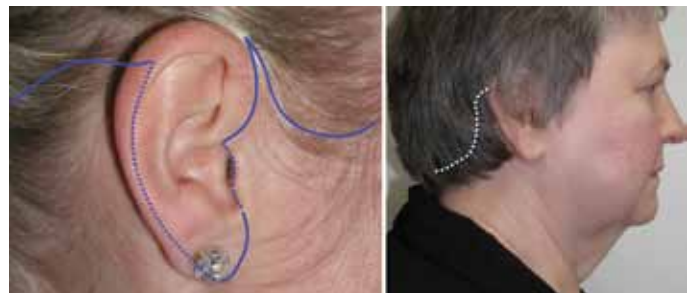

Figure 2A (left photo). The anterior facelift incision is engineered to preserve the temporal tuft and tragus and hide incisions in the hairline. The posterior limb of the incision is made at the greatest width of the pinna and tapers into the posterior scalp. Figure 2B (right photo) shows the low occipital hairline incision used by the author for patients with severe submental and skin excess.

patients with moderate submental and neck excess, the posterior incision is made in the post auricular area at the greatest width of the pinna. This places the posterior scar at the region where it is most hidden. This incision then tapers, gradually, 5-8 cm posteriorly (figure 2A). For patients with severe submental and neck skin excess, a lower occipital hair-line is frequently utilized (figure 2B). The reason for this lower placed incision is the fact that when pulling the extreme excess skin and using the traditional higher incision, post auricular balding can occur by removing hair-bearing skin. A naturally appearing posterior hairline is equally as important as the anterior hairline. I place all posterior incisions directly in the sulcus on females and males. After trying various techniques of placing the incision superior to the sulcus, etc., my observations have been that the sulcular incisions heal the best.

After the incisions are made, some surgeons predissect the flaps with a dissector or blunt cannula. This can be beneficial for the novice surgeon to maintain the proper subcutaneous plane. Otherwise, the flaps are carefully elevated with facelift scissors. It is important to leave several millimeters of subcutaneous fat

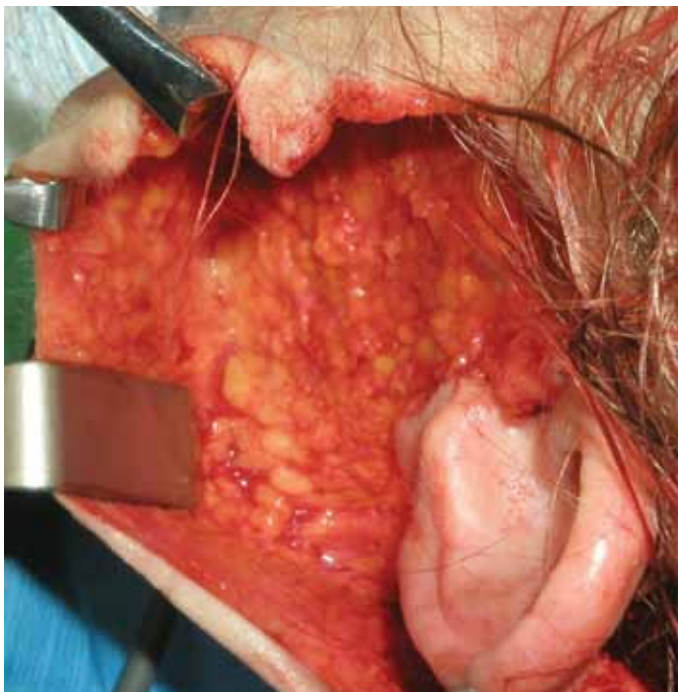


Figure 3 shows the elevated lipocutaneous flap with fat on the dermal side as well as the SMAS side of the flap.

on the dermal side of the flap as well as on the SMAS side of the flap (figure 3). This flap is a living creature and demands extreme respect during the procedure!

After the flaps are elevated (the average facelift requires a 5-7 cm dissection circumferential to the ear), “open” liposuction is performed, under direct vision, to address the lateral cervical and jowl fatty deposits. This fat is sculpted to taper into the mandibular border and lower cervical regions.

At this point, the SMAS is addressed. The superficial musculoaponeurotic system is a controversial structure as some surgeons believe it exists, while others feel there is no such structure. My definition of the SMAS is the tissue below the dermis and above the parotidomasseteric fascia. This fibro, fatty muscular layer is managed in numerous ways to tighten the deeper mobile tissues of the face. Popular means of managing the SMAS include plication, SMAS flaps, and SMASectomy. Regardless of which procedure is used, it is important for the surgeon to do something to address this deep tissue plane as “skin only” facelifts exhibit poor longevity.

The novice facelift surgeon is best served by SMAS plication which involves simple sutures placed in a manner to fold over the excess tissue to tighten these tissues. I most frequently perform a SMASectomy (although I don’t recommend this technique for novice surgeons). This involves excising an ellipse of SMAS from the malar region to the superior cervical region. This excision is performed parallel to the nasolabial fold. This means that the traction will be perpendicular to the fold and assist its improvement. The width of SMAS removed is commensurate to the amount of laxity to that given patient, which is generally about 3 cm in the average patient. Patients with thin or thready SMAS may not be good candidates for SMASectomy, as the consistency of the tissue will not “hold” the suture repair. Figure 4 shows an “arrowhead” configuration of a SMASectomy.

It is important to keep in mind that removing SMAS over the parotid gland is a safe zone, as the facial nerve branches run deeper in the gland and are protected. The parotidomasseteric fascia (as the name implies) covers the parotid gland and neighboring masseter muscle. Although this layer can be compromised over the parotid gland, there is no reason to disrupt the actual glandular tissue. The nerve lies deeper within the gland and is usually well protected, but disrupting the parotid tissue can cause a salivary fistula, so SMAS excision should stay above the parotid fascia. As the facial nerve branches exit the parotid gland, they cross the masseter muscle and are much more at risk for damage (figure 5). Again, performing all SMAS excision above the parotidomasseteric fascia will enable a safe plane of dissection relative to the facial nerve branches. The thickness of the SMAS excision does not have to absolutely extend to the parotidomasseteric fascia, but has to be thick enough to hold the sutures used to repair the SMAS.

To complete the SMASectomy, the ptotic SMAS, at the jowl is secured with a 2-0 braided nylon suture, pulled in a “positive vector” and attached to the fixed SMAS over the parotid gland. A “sweet spot” exists at the jowl region, where, when placed on traction in a superiorlateral angle, will tighten the cheek and the upper cervical region. When deciding on the placement of the first suture, the ptotic SMAS on the distal SMASectomy site is pulled at several different locations to see the exact area (“sweet spot”) of maximum improvement of jowl and upper-neck tightening. Once

this suture is placed, ancillary sutures are placed above and below the primary suture. Basically, 5-7 buried 2-0 braided nylon sutures are placed from the region of the angle of the mandible to the malar region (figure 4A). Placing sutures along the SMASectomy site will noticeably tighten the upper neck, jowl, mid cheek and in some cases, the upper cheek.

Next, the posterior platysmal border is suspended to the mastoid fascia to further tighten the neck. Although some surgeons feel that this

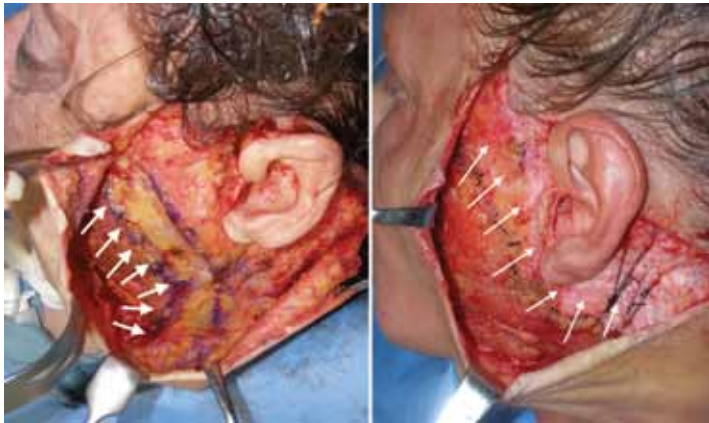

Figure 4A (left photo). This image shows the SMASectomy excision in the cheek (and in this case, extending into the neck). The white arrows illustrate the vectors of traction to be utilized (4A). Figure 4B (right photo) shows the SMASectomy closed from the malar region into the upper neck. Note the posterior platysma sutures pulling the muscle superiorly laterally and attaching to the mastoid fascia.

places tension on the midline platysma repair, I feel that this makes a complete sling to tighten the neck and submental region (figure 4B).

After the SMAS is repaired, the flap is checked for any residual subcutaneous dimpling that can occur with SMAS tightening, and this is released. The surgical site is then rechecked for hemostasis, and the excess skin is addressed. The first step in this process is to pull the flaps into a natural vector that adequately addresses the excess flap skin. I truly believe that each person has unique vectors, but they can be grouped into posteriorlateral “ten o'clock” and “two o'clock” vectors of tension (figure 6).

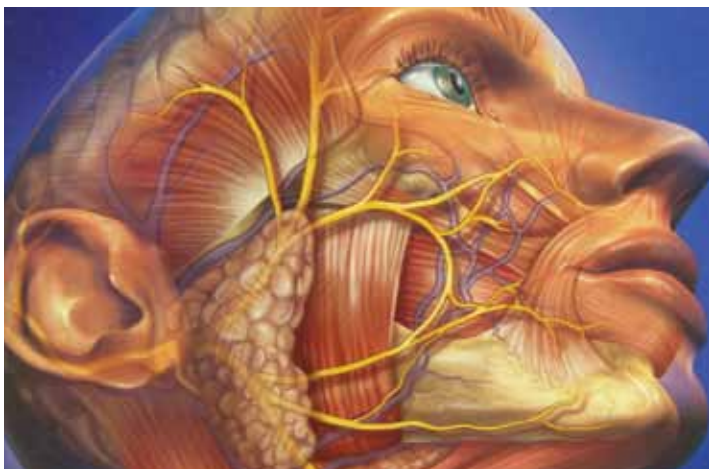

Figure 5. The facial nerve remains protected within the parenchyma of the parotid gland but is much more exposed and vulnerable when exiting the anterior border of the gland and traversing the masseter muscle.

Once the correct vectors and tension are achieved, skin cutbacks are made in front of and behind the ear and 4-0 Vicryl “Key” sutures are placed. The flap is pulled tight (without blanching) – these key sutures will be the only tension-bearing sutures on the skin. The earlobe is then delivered from under the flap to a passive position. In smaller lifts, this can be performed without a flap cutback, and in larger lifts, a cutback is required to deliver the lobe. This is definitely one area where the novice surgeon should cut 1/3 of what they think the incision will be, as over cutting this part of the flap is extremely common. When the flap cutback is performed in excess, the cheek will hang on the earlobe and a pixie lobe can occur. The surgeon must also account for the wound retraction and the fact that the patient is supine during the surgery, and when they return to the upright position, the lobe can be further pulled inferiorly.

At this point, the excess pre- and post-auricular skin is excised. This should be done so that the skin edges approximate passively and without tension. The posterior flap is never pulled directly back; it is simultaneously rotated when pulling in order to maintain correct hairline alignment (figure 6). I trim excess skin by using a radiowave microneedle which cuts with a pressureless incision and allows

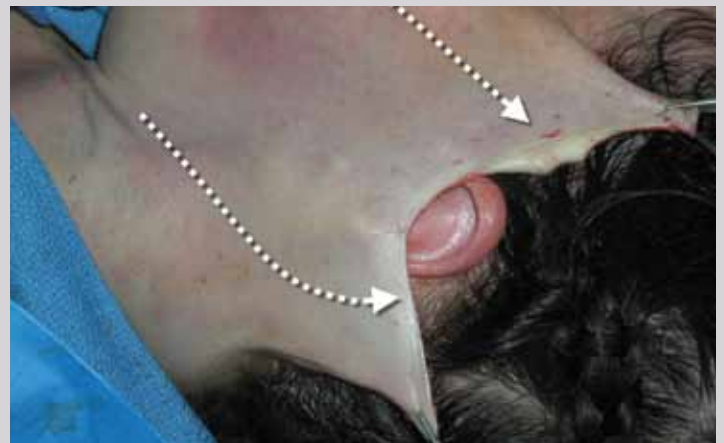

Figure 6. A generalization of vector directions is shown. Notice the posterior flap also rotates slightly forward to main hairline integrity.

precise navigation of the many curves and geometrics required with excess skin excision (figure 7). Great care is utilized to resulpt a naturally appearing tragus. I personally do not use subcutaneous sutures. I close all skin incisions with resorbable sutures and use staples in the hair-bearing regions.

I do not use drains and have stopped using the traditional, bulky facelift dressings without any negative findings. Novice surgeons should consider traditional dressings and therapies and can expand on variability with experience. ▀

Figure 7.
This image shows the excess skin and proposed incision margins.

Figures 8 -10 show patients before and after the facelift techniques described above.

Figure 8.
This patient is shown before and after comprehensive facelift, 4 quadrant blepharoplasty, silicone cheek implants and full face CO2 laser skin resurfacing.

Figure 9.
This patient is shown before and after comprehensive facelift.

Figure 10.
This patient is shown before and after comprehensive facelift, blepharoplasty, silicone cheek and chin implants and full face CO2 laser skin resurfacing.

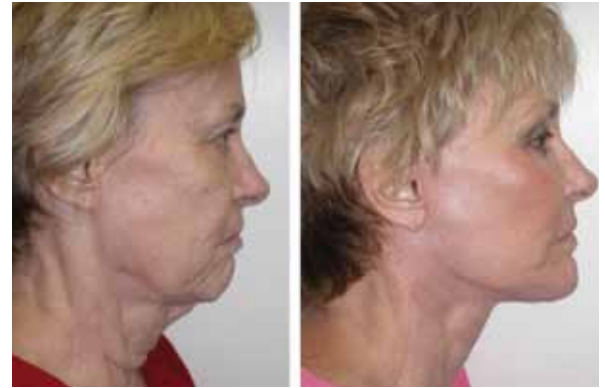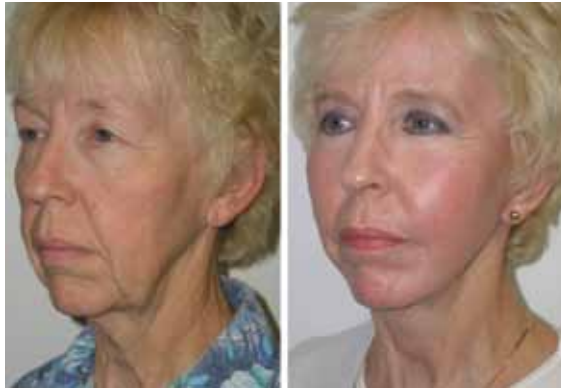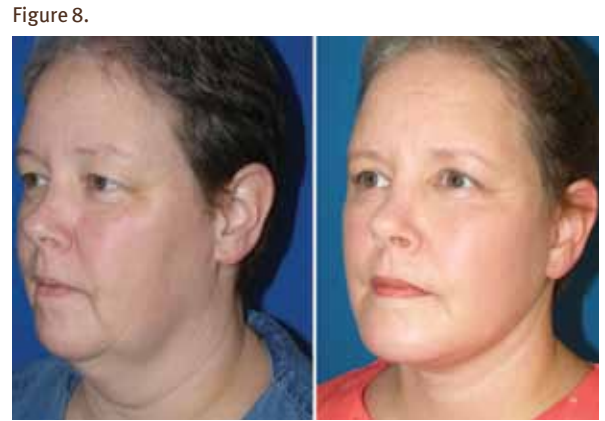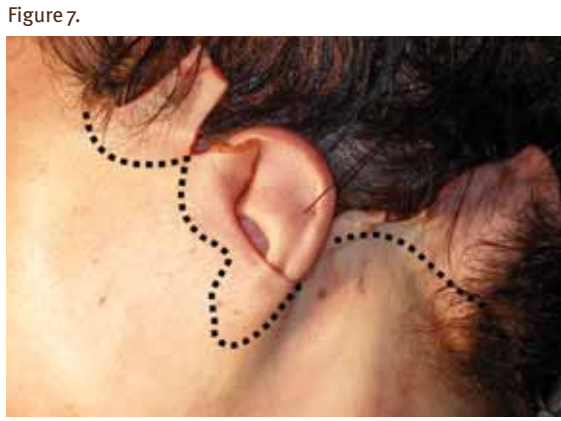


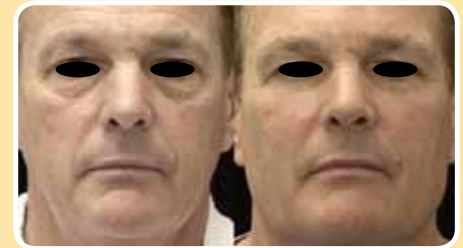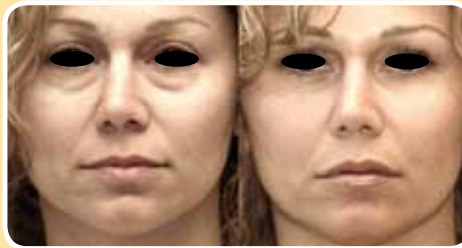Figure 9.

Figure 10.



Mark Berman, MD

- **ALL-IN-ONE - INTEGRATED SYSTEM**
From tumescent injection, through liposuction and harvesting, to fat transfer with higher survival rates
- **CLOSED-CIRCUIT, ASEPTIC PROCEDURES**
Reduce exposure to air or contamination
- **HARVESTING OF HIGHLY CONCENTRATED ADIPOSE-TISSUES**
By employing a specialized weight-mesh piston with strong RPM and G-force centrifugation

Visit Palomar® at the *AACS Annual Scientific Meeting* to Learn More about this **Autologous Fat Transfer System**



Palomar Medical Technologies, Inc. 15 Network Drive, Burlington, MA 01803 USA
©2010 Palomar Medical Technologies, Inc. Palomar is a registered trademark of Palomar Medical Technologies, Inc. Lipokit is a trademark of Medi-Khan (USA), Inc. ALL RIGHTS RESERVED