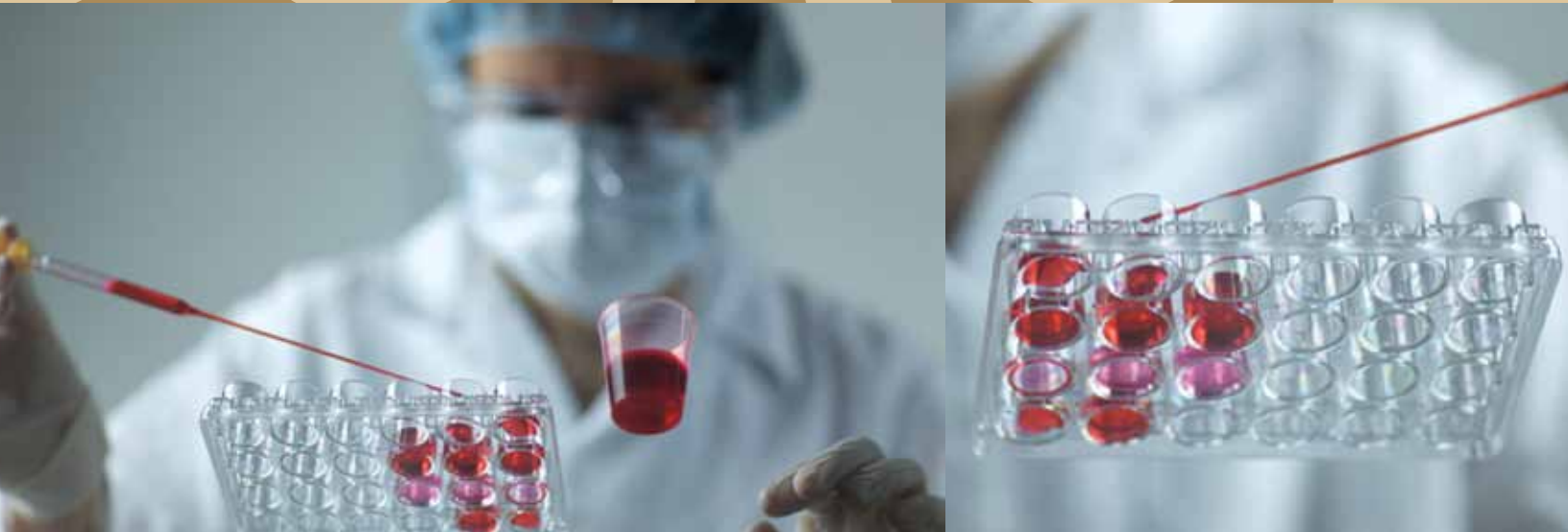



AMERICAN ACADEMY
OF COSMETIC SURGERY

A PUBLICATION OF THE AMERICAN ACADEMY OF COSMETIC SURGERY

SURGE



STEM CELLS

Where are we headed in 2011?

An entire industry based upon adipose-derived stem cells has been brewing.



AACS issues a statement on the FDA's recent report on breast implants



Dr. Clement Qaqish talks about his fast-paced AACS Fellowship

ISSUE 1

VOLUME 4

APRIL 2011



Procedural discussion...
Joseph Niamtu III, DMD

Cosmetic Blepharoplasty Part 1

UPPER BLEPHAROPLASTY

Blepharoplasty is one of the most commonly requested cosmetic surgery procedures for both men and women. As upper facial aging becomes evident in the fourth decade, younger patients frequently present with the common statement “Doc, I diet and exercise but the person looking back in the mirror looks older than I feel.” Skin and muscle excess, fat prolapse and brow descent all contribute to upper eyelid aging and each component must be addressed specifically for successful outcomes.

Failure to diagnose brow ptosis is still an amazingly common problem and I regularly see patients present for browlift consultation who have had two aggressive upper lid blepharoplasty procedures and now browlift is impossible as there is insufficient skin to close the lids. I tell my patients that if they see another surgeon for a blepharoplasty consult and the word “brow” is not mentioned in the first several sentences, they should stay away. A large number of blepharoplasty patients could benefit from a browlift. Although many will not be interested, it is still the job of the surgeon to provide contemporary options.

Although blindness and other serious complications are extremely rare, the surgeon and staff must be vigilant for any medical factors that could complicate blepharoplasty surgery. Hypertension, thyroid disease, diabetes, and coagulopathies are high on the list of potential problems. I perform a coagulation panel on all eyelid surgeries and spend a lot of time making sure to avoid any medication that can affect platelet function. Additional preoperative clinical tests include assessment of tear production, corneal reflex, pupillary function, extraocular muscle function, lid laxity, Bell’s phenomenon, ptosis screening, crease position and symmetry and of course visual acuity.

Upper eyelid blepharoplasty can be performed with local anesthesia or sedation and there are relative advantages for both methods. The preoperative marking is perhaps the most important single means of achieving safe and effective surgery. For novice surgeons, I believe it

is harder to learn and understand proper marking technique than it is to learn the surgical procedure.

The most important factor to consider in planning the upper eyelid incision is the fact that it takes at least 20 mm of upper lid skin to close the eye. The method of marking that has served me well is as follows. The patient is always marked in the seated and upright position before any local anesthesia is given. Prior to marking, the eyelid is cleansed with an alcohol pad to better adhere the ink.

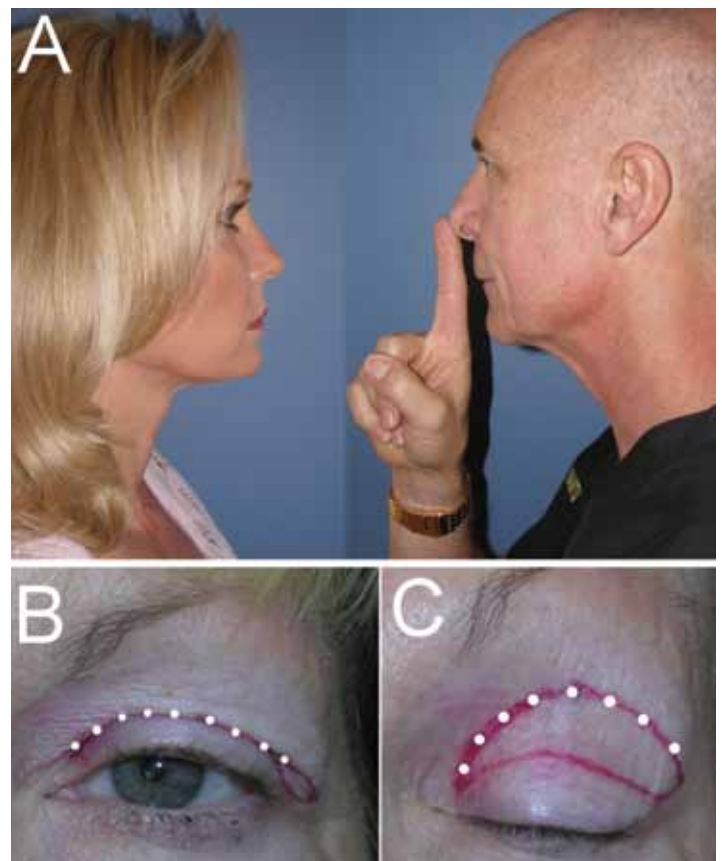


Figure 1. Marking the inferior portion of the upper redundant skin will closely approximate upper extent of the resection. 1A shows the patient staring at the surgeon’s finger, 1B shows the marking of the redundant skin fold which will generally correspond to the uppermost extent of the incision shown in 1C.

I prefer to use a blue fine-tip retractable Sharpie. I first begin my marking by standing in front of the patient and have them stare at my finger. While in this neutral gaze, I mark the underside of the redundant skin fold (Figure 1). This marking will generally correspond to the upper margin of the resection and is used with another method to predict the upper incision extent.

The other method I employ to mark the upper incision extent is to make a mark at the transition from the thick forehead skin to the “crinkly” orbital skin (uppermost white dot in figure 2). This transition is generally at or about the superior orbital rim. Most of the time the marking method in Figure 1 will correspond with the upper marking shown in Figure 1. I will come back to finishing this marking after describing the marking of the crease.

The palpebral crease is generally about 8-10 mm from the ciliary margin in males and 10-12 in females. (Asian blepharoplasty is outside of the scope of this article). I generally utilize the patient’s existing crease unless there is an aesthetic reason to change it. My marking extends from the lacrimal punctum (or just slightly medial to it) to the lateral canthal region. In this region, the incision is extended with a superior lateral upturn to meet the upper incision extent. This will allow extra skin to be removed to address the “hooding.” A typical marking example would be a female with a 10 mm existing crease. The crease is marked as shown in Figure 2. The transitional skin marking that I earlier referenced is now

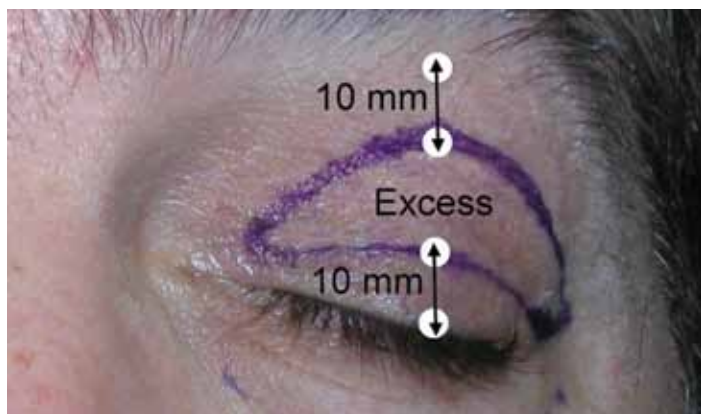


Figure 2. A safe way to ensure that 20 mm of normal lid skin is preserved is to mark from the ciliary margin to the crease (generally 8-10 mm), then make a mark (generally 10-12 mm) inferior to the frontal/orbital transition skin. In application, if the crease is at 10 mm, the superior mark would be made 10 mm below the transition skin for a total of 20 mm of lid skin preserved. If the crease was at 8 mm, the top mark would be 12 mm inferior to the transition, again to allow 20 mm of skin left in place. Any excess can generally be safely removed.

performed. I make a mark at the change between the thick frontal skin and crinkly orbital skin and measure 10 mm below this line and this will be the upper extent of the excision. Remember, it takes 20 mm of skin to close the eye and this method leaves 10 mm below the crease and 10 mm superiorly, thus preserving the required skin (Figure 2). To verify that this amount of skin removal is not excessive, I use an instrument to grasp the upper and lower lines and this maneuver should only gently evert the upper lashes and not forcibly open the lid (Figure 3).

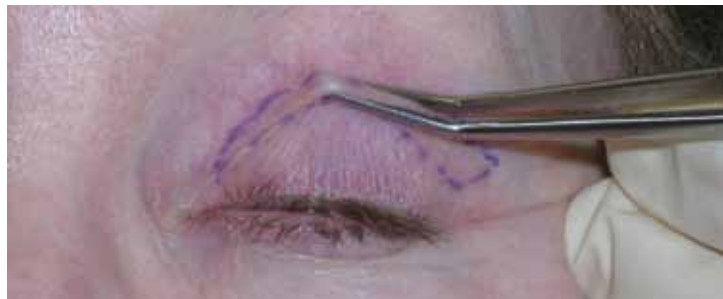

Figure 3. Confirmation of adequate skin preservation for lid closure is confirmed by pinching the upper and lower marked lines. The lashes should just begin to evert but not open the eye. Experienced blepharoplasty surgeons may make the entire marking by this pinching method.

SURGICAL PROCEDURE

The upper lid is infiltrated with 1-2 ml of 2% lidocaine with 1:100,000 epinephrine with care to avoid orbicularis injection to avoid bruising. Stainless steel corneal shields are used with lasers and plastic shields are used with electric-based devices. I

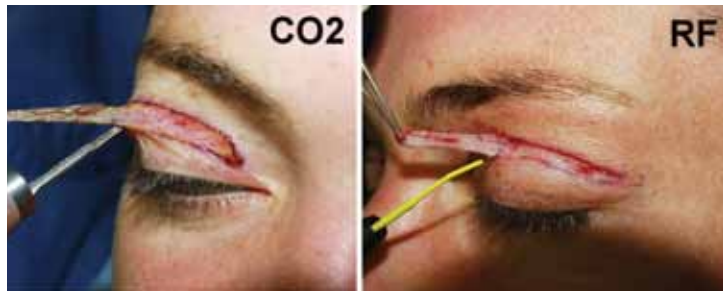


Figure 4. The CO₂ laser (left) and Ellman Radiowave microneedle (right) both enable exact tissue incision with simultaneous hemostasis.

prefer coagulative incisional modalities that provide simultaneous cutting and hemostasis. Less bleeding provides a cleared surgical field, and in a four quadrant blepharoplasty my blood loss is almost nonexistent. Less bleeding also means less bruising, less pain and faster healing. The skin is removed with the CO₂ laser or radiowave microneedle in a separate layer (Figure 4).

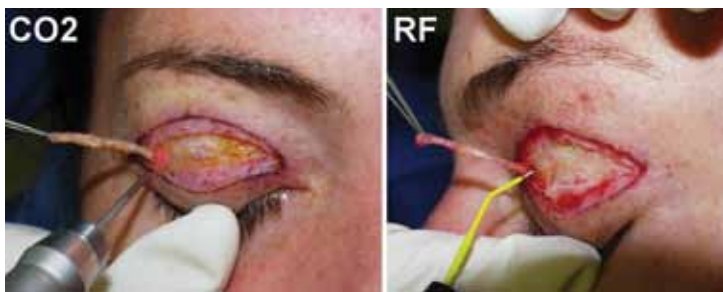

Figure 5. The middle 1/3 of the orbicularis oculi muscle is resected using the CO₂ laser (left) and the Radiowave microneedle (right). Both modalities provide bloodless excision. The orbital septum lies underneath the muscle and is visible.

Some surgeons remove the same amount of orbicularis muscle as the skin incision while others do not remove any muscle. I prefer to remove the middle 1/3 of the orbicularis that will underlie the suture line (Figure 5).

The upper lid contains a central and medial fat pad and the lacrimal gland in the lateral orbit, which has been inadvertently removed by novice surgeons. The fat appears yellowish while the glandular tissue is more pink and lobulated, resembling parotid or other glandular tissue. The two upper fat pads lie inferior to the orbital septum and I generally open the entire septum beginning in the central portion. I am judicious with fat resection in this area and take away only that fat that protrudes with gentle retropulsion (pressure on the globe) (Figure 6). The fat can be further shrunk by defocusing the laser and melting it back.

from any Valsalva-producing activity and to be “couch potatoes” for the first two days.

The next issue of SURGE will contain part two of this series and discuss lower eyelid blepharoplasty techniques. ■

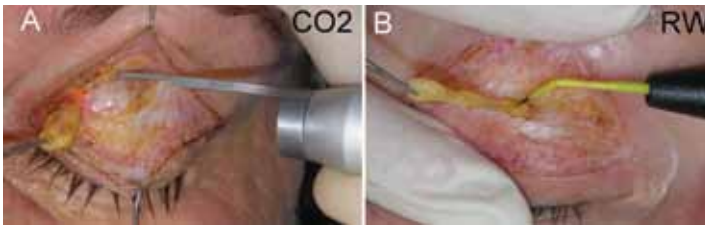


Figure 6. This image shows an upper lid central fat pad being reduced with CO₂ laser and the right image shows an upper lid central fat pad being reduced with Radiowave microneedle. No clamping of the fat is necessary with coagulative incision modalities.

The medial (nasal) fat pad can be more elusive and can be identified with retropulsion and blunt dissection with cotton-tipped applicators or blunt spreading with micro hemostats. I am more aggressive with fat resection in this area as fullness is a common complaint with patients. I am very judicious with my fat incision in this area as a bleeding vessel that retracts into the orbit can be difficult to control and could lead to retrobulbar hematoma. When incising this (or any) fat pads I use the laser in a defocused mode which increases the spot size and hence the coagulation. Otherwise, a micro bipolar radiowave forceps works quite well.

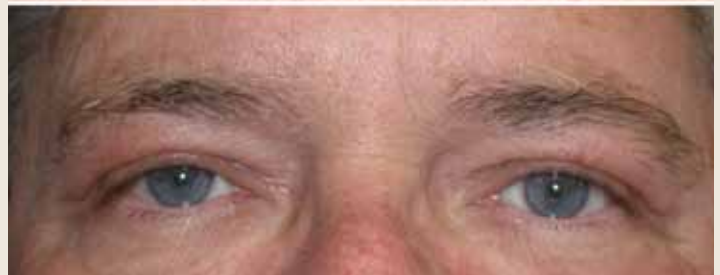
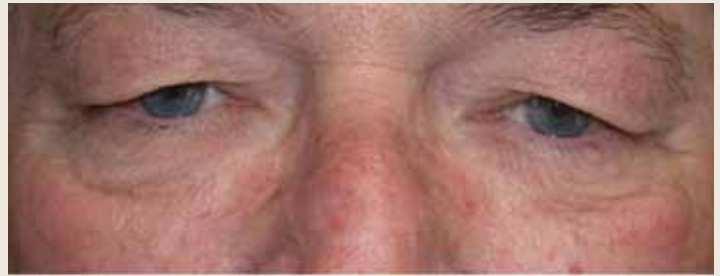
Figure 8. This image shows a 66-year-old male with severe upper eyelid skin excess before and after surgery.

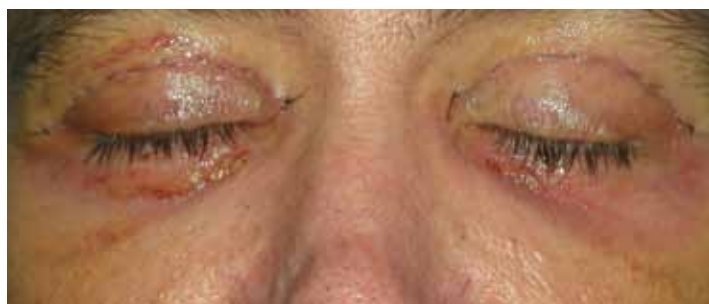

Figure 7. A running 6-0 nylon suture is shown five days after surgery.

When the excess skin, muscle and fat is removed, all areas are again checked for hemostasis and the wound is closed. I place a single 6-0 fast-absorbing gut suture at the medial, central and lateral 1/3 of the incisions. This adds strength to the closure as well as lines up the skin margins for more exact final closure. Finally, a running 6-0 nylon suture is placed only through the skin edges and does not include orbicularis margins. The sutures are left in place for five days (Figure 7).

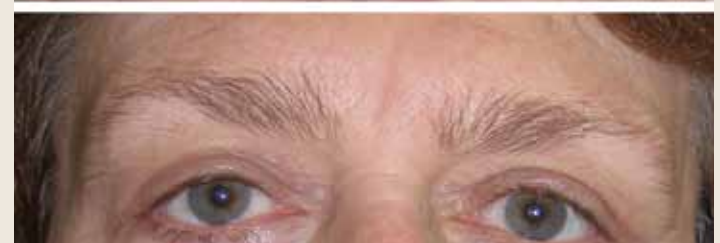
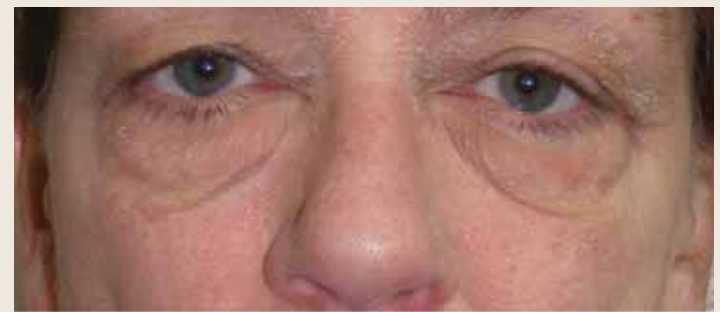
Figure 9. This image shows a 56-year-old female before and after upper and lower blepharoplasty and periorbital CO₂ laser skin resurfacing.

Post-operatively, the patients are treated with ice packs and asked to sleep elevated for 48 hours. They are further instructed to refrain