



Cosmetic Surgeon Shares Alternative Approaches to Lip Enhancements

By Joseph Niamtu, III, D.M.D., F.A.A.C.S.

Astute cosmetic surgeons and practitioners realize that all lips are not created equal. In fact, they are probably more like snowflakes in that no two patients present with the exact same situation for correction. For most cosmetic surgeons, injectable dermal fillers can satisfy the majority of their patients; however, some patients present with inherited, developmental or age related lip concerns that are not amenable to dermal filler injections. For this population, procedures such as the subcutaneous lip lift, lip implants or lip reduction may prove beneficial.



Cosmetic Surgeon Shares Alternative Approaches to Lip Enhancements

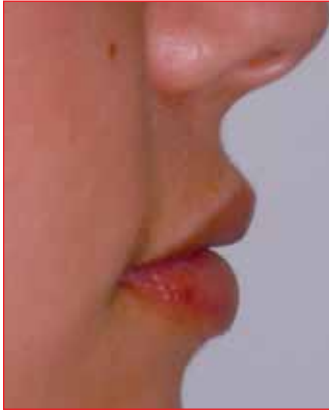

Figure 1A

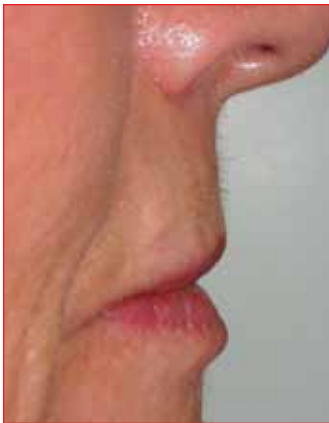

Figure 1B

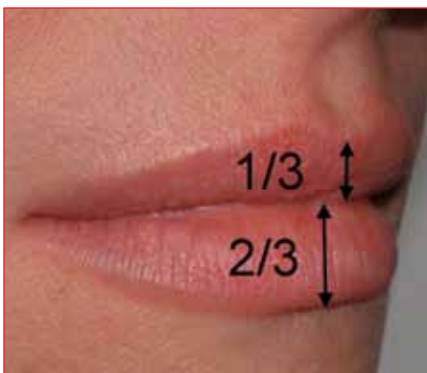


Figure 2

Photos courtesy of Joseph Niamtu, III, D.M.D., F.A.A.C.S.

The youthful lip has many unique characteristics. These include volume for plumpness and a shorter length than the aging lip, which provides pout and allows for several millimeters of the upper incisors to show. Additionally, youthful lips display well defined anatomic structures including the “white roll”, or light reflex at the vermilion / cutaneous junction of the Cupid’s Bow (Figure 1A). A well developed Cupid’s Bow generally has a “lazy M” shape in the upper lip, while the lower lip vermilion / cutaneous junction is more curvilinear. Other desirable features include well defined philtrum and philtral columns, as well as an upper lip consistent with the Golden Ratio (also called Devine Proportion) of 1:1.6. This means that the upper lip contains about one-third of the total lip volume, while the lower lip contains about two-thirds of the total lip volume (Figure 2).

Compared to the youthful lip, the senescent lip undergoes many changes. A generalized loss of volume occurs that affects all associated tissues. Lip skin is affected by actinic damage and vertical lip rhytides. The lip muscle, fat and salivary glands become atrophic, along with atrophic changes to the supporting teeth and alveolar bone, which lead to decreased lip position and support. The sum of these changes results in a longer lip in older individuals (Figure 1B) with loss of volume and definition, in addition to less upper incisor show.

“Although injectable lip enhancements are among the most commonly requested cosmetic procedures, not all patients will benefit from larger or fuller lips.”

Contemporary aesthetic practitioners are well aware of the art and science of lip enhancement using injectable dermal fillers. For those that have been practicing longer than ten years, you may recall the early days of dermal fillers. It was a tough time as there were basically two choices: Zylplast and Zyderm, developed by Inamed (Santa Barbara, Calif.) and acquired by Allergan (Irvine, Calif.). Given that bovine collagen was their key component, required allergy testing and minimal longevity made these products less than desirable options.

In 2002 the first hyaluronic acid (HA) dermal fillers received FDA approval, which began a revolution providing injectors with a non-allergenic product that did not require over correction, was much longer lasting, and most importantly, could be reversed. As a result, HA dermal fillers have become the dominating force in modern day lip enhancements. Nevertheless, numerous other types of dermal fillers have also been FDA approved offering a variety of safe and long lasting options.

Although injectable lip enhancements are among the most commonly requested cosmetic procedures, not all patients will benefit from larger or fuller lips. Some patients request smaller lips and other patients have congenital or age related morphologic conditions that require more than a simple dermal filler injection to improve.

The subcutaneous lip lift (SLL) is designed to shorten the philtrum, as well as roll the lip out and up to restore volume, extend the vermilion and improve upper incisor show. Candidates for this procedure must have a length of at least 20 mm from the columella to the vermilion, as shortening a lip that is already short can lead to unaesthetic results that are difficult to correct. Using a fine line marker, a



Cosmetic Surgeon Shares Alternative Approaches to Lip Enhancements

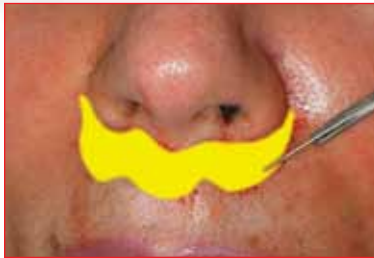

Figure 3

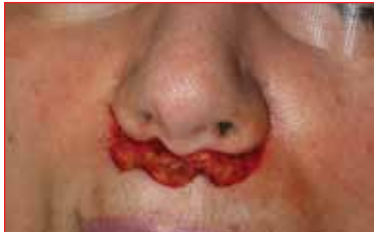

Figure 4

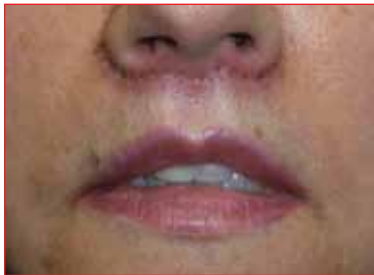
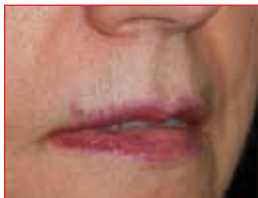
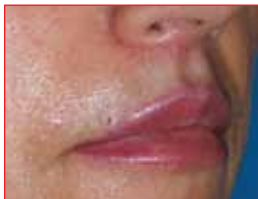Figure 5



Patient before



Patient after subcutaneous lip lift. Note the difference between the length and pout of the lip after the procedure.

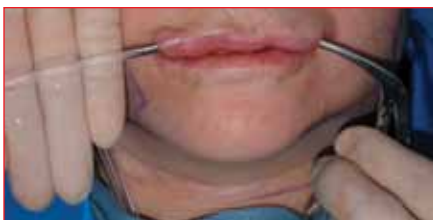

Figure 7

Photos courtesy of Joseph Niamtu, III, D.M.D., F.A.A.C.S.

very geometric line is drawn at the base of the columella, moving laterally along the bilateral alar bases. These lines should represent the full anatomic curvature of the nasal base structures. Next, a reciprocal line is drawn to complete the "bull horn" or "mustache" anatomy. The lower portion of the incision is 5 to 7 mm from the top line in the average patient and tapers into the alar bases (Figure 3).

Local anesthetic is injected subcutaneously around the marked incision. Using a 15 scalpel blade, the incision is made, keeping in mind the curvature of the incision. The incision may include skin only or skin and orbicularis muscle depending on how much outward roll or pout is desired. If muscle is included, the incision can be "V" shaped in cross section. The marked skin is then excised and cauterization is performed for hemostasis (Figure 4). Subcutaneous 5-0 gut sutures are used to reinforce the closure and a running 6-0 nylon suture is used for final closure (Figure 5).

"Though most patients have accepted the process of injectable dermal fillers, there is a segment that objects to needles or the need for continual maintenance."

Until approximately five years ago, lip implants were a common procedure in my practice. Due to the advances in HA dermal fillers, the procedure has waned, but it is still an option for some patients. Though most patients have accepted the process of injectable dermal fillers, there is a segment that objects to needles or the need for continual maintenance. Lip implants can be a suitable option for this segment of the cosmetic population. Contraindications for this procedure include smokers or patients that use their lips to make a living (woodwind instrument players). Patients must understand that an implant may be visible with extreme animation and that it will also be palpable.

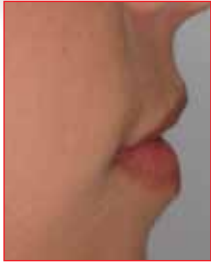Over the years I have used numerous materials for lip implantation and although several of these are biocompatible, they do not look or feel natural. At this time, the only lip implant I use is a soft, stretchy, tapered implant made by SurgiSil (Plano, Texas).

A patient's lips are measured pre-op to determine the proper implant size. This procedure is easily performed with local anesthesia which is infiltrated in all planes of the lip. A "stab" incision is made just shy of each commissure and a dissector is advanced through one incision and out the other incision (Figure 7). It is important to keep a straight line in the center of the lip throughout the entire dissection or the implant will not sit naturally. I generally use a tendon passer to perform the dissection, then pull one end of the implant through, center it and close the incisions. Experienced surgeons can perform this procedure in about five minutes. Patients are asked to limit oral function for several days and apply ice as much as possible.

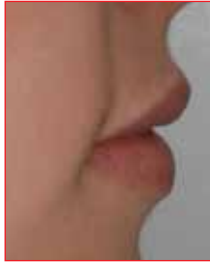As stated earlier, not all patients desire larger lips. Some patients seek lip reduction. This procedure is designed to reduce the amount of vermilion show and outward roll of the lips by removing a strip of mucosa, and/or muscle, posterior to the wet/dry line. Patients that have significant class II occlusion (buck teeth)



Cosmetic Surgeon Shares Alternative Approaches to Lip Enhancements



Patient before



Patient after upper and lower lip implants

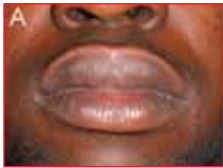

Figure 9A

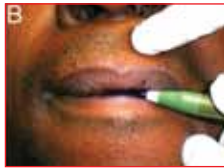

Figure 9B

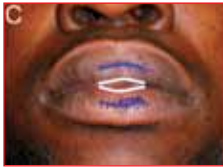

Figure 9C

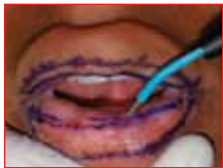

Figure 10

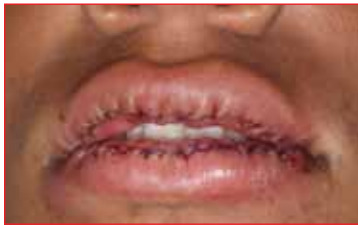
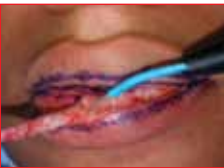
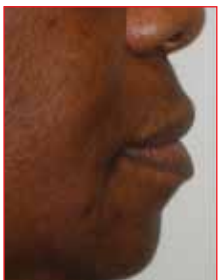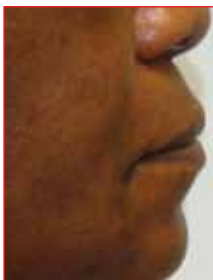Figure 11



Patient before



Patient after lip reduction

Photos courtesy of Joseph Niamtu, III, D.M.D., F.A.A.C.S.

or significant incisor show are not candidates, as this procedure also shortens the lip and excess tooth show would be a complication.

Like many procedures, pre-op markings are very important to control the outcome. A patient is marked by estimating the amount of excess or desired reduction. The lips are wiped with alcohol to ensure better adherence of the marking. To begin, lips are first observed in repose (Figure 9A). Next, the patient is asked to retract their lips to the point of reduction desired while looking into a mirror. A mark is made at this position on the lips (Figure 9B). Then the patient is asked to relax their lips and a mark is made on the vermilion at this point (Figure 9C). The difference between the marks (usually 5 to 7 mm) is the minimal amount of anticipated reduction. For the novice surgeon it is better to error on the conservative side as more reduction can always be completed later. After marking the lips, dry gauze is placed between the lips to prevent the markings from smudging.

Making the incision posterior to the wet/dry line to keep it hidden is of the utmost importance to the success of this procedure. Failure to do so will produce a visible incision. The lips are infiltrated with local anesthesia in all planes. Due to the vascularity of the lips, a simultaneous incision or coagulation such as electrosurgery, radiowave surgery or CO₂ laser is preferable (Figure 10).

Experienced surgeons will often remove 1.5 to 2 times the estimated skin. If the pre-op markings require a 5 mm position difference, 10 to 12 mm of skin is removed to compensate for the elasticity of these tissues. This should be approached with caution by novice surgeons.

After the skin is excised, the orbicularis oris muscle and minor salivary glands are visible. For patients that desire a significant reduction, it is not uncommon to remove a wedge of these deeper tissues. After the proper amount of mucosa and deep tissue is removed, absolute hemostasis is performed and several 5-0 gut key sutures are placed to strengthen the closure. This is followed by a running 5-0 silk suture (Figure 11). Although other suture materials can be used, silk is the most patient friendly.

This procedure is always followed by significant swelling and patients are frequently placed on a steroid regimen. The suture line may initially be visible due to the swelling, but will retract as swelling resolves. Patients must be warned that in some cases swelling can last for a number of weeks. ■



Joseph Niamtu, III, D.M.D., F.A.A.C.S.

Dr. Niamtu is well known as a surgeon, teacher and author, and is regarded as a key opinion leader by academies and clinicians worldwide. Dr. Niamtu is board certified by the American Board of Oral and Maxillofacial Surgery and lectures internationally on cosmetic facial surgery. He has written three textbooks, 22 chapters in other textbooks; authored hundreds of publications on various cosmetic facial topics and a cosmetic facial surgery DVD series. Dr. Niamtu has served on the board of directors of the *Cosmetic Surgery Foundation* and has chaired numerous committees with the *American Academy of Cosmetic Surgery*. Dr. Niamtu is committed to numerous charitable organizations and has been active with Operation Smile, Noah's Children, International Hospital for Children and Medical Care for Children.