

Simple Technique for Lip and Nasolabial Fold Anesthesia for Injectable Fillers

Q2 JOSEPH NIAMTU III

BACKGROUND. Minimally invasive cosmetic facial surgery procedures including injectable lip fillers are more popular than ever. Many of the newer fillers are more painful to inject than previous products and require a greater level of pain control.

OBJECTIVE. The objective of this article is to describe a simple method of local anesthesia infiltration for pain control when injecting filler substances into the lips and perioral and nasolabial fold areas.

MATERIALS AND METHODS. The preinjection topical anesthetic preparation, the actual infiltration techniques, and the author's experience are reviewed.

RESULTS. These infiltration technique are simple to perform and provide adequate anesthesia for the painless injection of filler substances in the lips and perioral and nasolabial regions.

CONCLUSION. This simple intraoral infiltration technique is well tolerated and appreciated by patients and facilitates the experience of filler injection for both the patient and the doctor.

JOSEPH NIAMTU III HAS INDICATED NO SIGNIFICANT INTEREST WITH COMMERCIAL SUPPORTERS.

INJECTABLE FILLERS have been a mainstay of cosmetic facial surgery for decades. There is no doubt that the majority of filler injections in the United States over the past 20 years have been bovine collagen. Zyplast and Zyderm (Inamed Corp., Santa Barbara, CA, USA) contain local anesthesia in the form of lidocaine (0.3%). Owing to the inherent local anesthesia, the nature of the bovine collagen preparations, and the small needle size (30 gauge), these preparations were most commonly injected in the lips and face without augmentive anesthetic techniques.

Restylane (Medicis, Inc, Scottsdale, AZ, USA) is a hyaluronic acid filler that has been used outside the United States for the past decade and was approved by the US Food and Drug Administration (FDA) in December 2003. Restylane has been long awaited in this country owing to the increased longevity over bovine collagen.¹ Since the FDA approval, Restylane has become an extremely popular injectable facial filler in this country. Restylane contains 100,000 gel particles per milliliter and is optimally injected through a 30-gauge needle. Radiesse (formally called Radiance, Bioform Medical, Inc, San Mateo, CA, USA) is an injectable filler that has FDA approval for use in the vocal cords and as a radiographic marker. Radiesse is used off label for rhytid effacement and lip enhance-

ment. This filler is injected in the subcutaneous plane with a 27-gauge needle. Owing to the properties of these new fillers, viscosity differences, and the larger needle size required, injection in the lips can be more painful to patients than previous bovine collagen preparations. These newer fillers can be injected in the facial skin in most patients with no local anesthesia. Injection in the lips, however, can be intolerable. Even seasoned patients who had many previous bovine collagen injections find some of the newer fillers prohibitively painful without augmentative local anesthesia. This increased pain has warranted the use of topical anesthetics and maxillary and mandibular nerve blocks.²⁻⁴ Although local anesthetic nerve blocks are very effective for anesthesia of the lips, they pose numerous drawbacks to the routine injection of fillers. The main problem with local anesthetic nerve block is that they lengthen and complicate the otherwise routine appointment for facial fillers. In addition, many practitioners are unfamiliar with these blocking techniques (especially non-physician injectors), and the need for these blocks can add stress to the patient and injector. Local anesthetic blocks are required bilaterally for upper and lower lip injection, and this requires four separate injections. This basically renders the patient's entire mid- and lower face anesthetized for 1 to 3 hours, which is an additional drawback. It is not uncommon for even veteran practitioners to "miss" the local anesthetic block, which necessitates even more injections. Finally, postinjection pain and hematoma can occur from these blocking techniques.

Q3 Address correspondence and reprint requests to: Joseph Niamtu,

I have been performing local anesthetic blocks of the face for 25 years and initially used them while injecting the newer fillers in the lips. Owing to the negative connotation of additional injections and the added time needed for filler injection, other methods of anesthesia were investigated. After experimenting with various topical and local anesthesia infiltration techniques, I have eliminated the use of trigeminal nerve blocks and use the described techniques. This has expedited appointments for lip filler injection and has been a welcomed change on the part of the patient. This technique has proven adequate for 100% of patients receiving Restylane and Radiesse injections in the lips and/or nasolabial folds. The injections are performed quickly and provide excellent local anesthesia for lip and perioral injection.

Technique for Upper and Lower Lip Anesthesia

As soon as the patient is seated in the treatment room, a potent topical anesthesia compound of 20% benzocaine, 6% lidocaine, and 4% tetracaine (Bayview Pharmacy, Baltimore, MD, USA) is applied intraorally in the depth of the anterior maxillary and mandibular vestibule. The vestibule is the sulcus formed at the junction of the attached gingival and the unattached mucosa. The same topical agent is applied to the external lip mucosa. A 5 cc syringe of 2% lidocaine, 1:100,000 epinephrine, and a 32-gauge needle is used. Increments of 0.5 cc of local anesthetic solution are injected in four to five areas between the canine teeth (Figure 1A). The injection is submucosal in the potential space between the mucosa and the periosteum. The needle does not need to touch bone because this is a soft tissue injection. If both lips are to be injected, the same procedure is performed in the lower vestibule as well (Figure 1B). Alternatively, the injections can be placed 5 to 7 mm superior to the sulcus in the upper lip or inferior to the sulcus in the lower lip. The surgeon can experiment with either of these

injection locations to determine which is most preferable for the injector and the patient. After several minutes, the lips and perioral areas are adequately anesthetized for filler injection. This infiltration approach does not produce the profound level and extent of anesthesia experienced with bilateral nerve block but is well suited for cutaneous and vermilion filler injection of the lips. On an informal query of the depth of anesthesia, most patients reported 10 of 10 (10 being most profound) in the central third of the lip, with this tapering off to 7 of 10 at the lateral third areas (Figure 2). The area anesthetized may extend to the nasal tip in the maxilla and to the mentolabial fold in the mandible (see Figure 2, dotted outline). Return of sensation generally progresses between 30 and 60 minutes. No significant anatomic structures traverse this area of the vestibule, and I have not experienced any complications with thousands of these injections.

Technique for Nasolabial Fold Anesthesia

This technique involves injecting local anesthesia into the oral mucosa on the underside of the nasolabial fold. The black dotted line in Figure 3A illustrates the skin surface of the nasolabial fold and the white dots show the underside of the nasolabial folds where the anesthetic is injected. After applying topical anesthesia, a 32-gauge, quarter-inch needle is used to deposit 0.25 cc of 2% lidocaine and 1:100,000 epinephrine in four to five areas spanning the underside of the nasolabial fold. The anesthetic is injected halfway between the skin and the mucosa. By keeping this injection deep to the skin, there is no distortion of the actual nasolabial fold. Figure 3B shows the blanched skin outlined by arrows to illustrate the anesthetized area. Waiting 5 to 10 minutes allows sufficient time for the anesthesia to take effect. To minimize the number of punctures, a 1.5-inch, 27-gauge needle may be inserted to the hub and the solution injected as the needle is withdrawn,

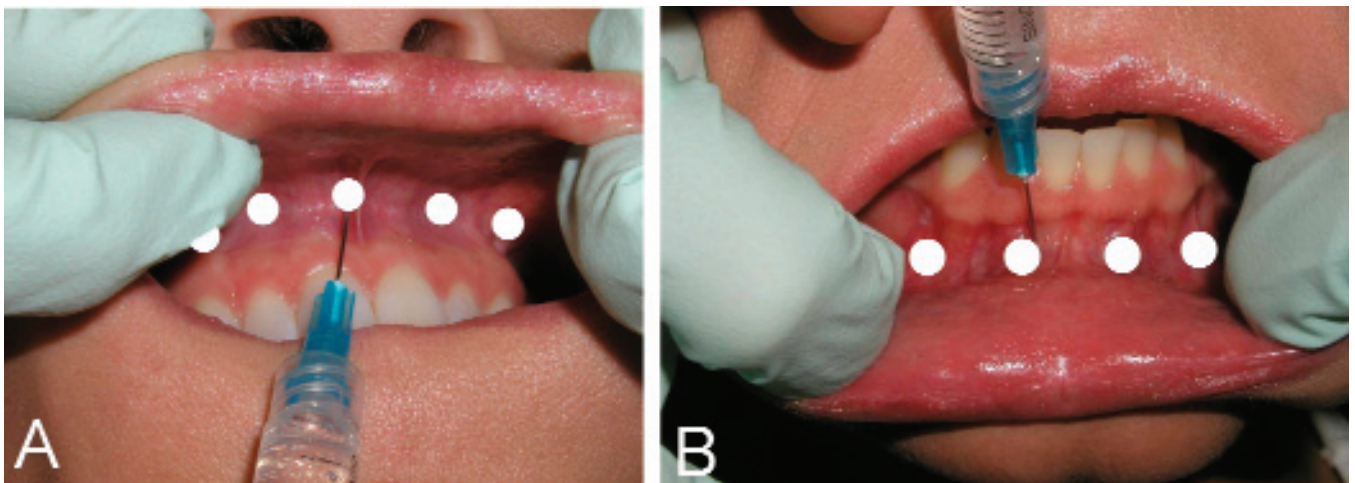
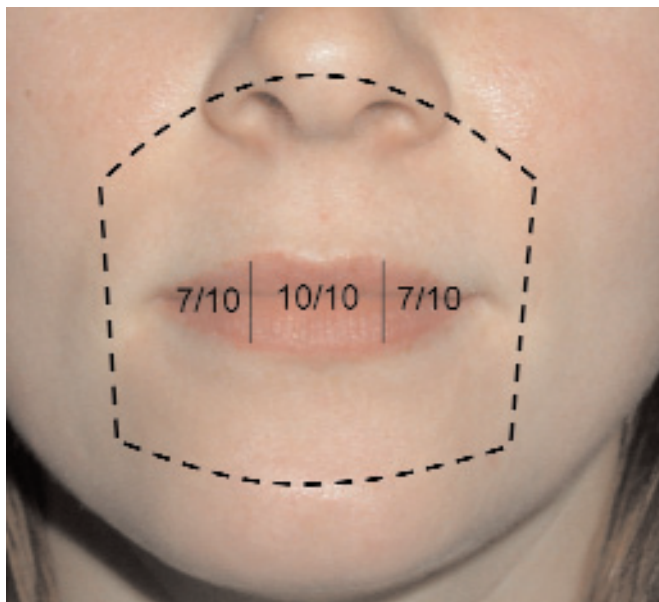


Figure 1. A shows the pattern for local anesthetic injection of the upper lip and figure B shows the injection pattern of the lower lip.



Q8 **Figure 2.** For the average patient, the perioral *dashed line* shows the extent of anesthesia in the perioral region. The central third of the lip is usually totally anesthetized, whereas the lateral third averages an anesthesia level of 7 of 10.

Q9

thereby requiring only a single mucosal puncture. Although this technique could be performed percutaneously, it would have drawbacks. First and foremost is the fact that the solution will distort the nasolabial fold, making accurate filler injection difficult. Second, the oral mucosa is much more responsive to topical anesthesia, making the actual injections less painful.

Conclusion

These simple techniques of maxillary and mandibular vestibular and mucosal infiltration in conjunction with topical mucosal anesthesia are safe, rapid, and effective ways to provide local anesthesia for the cosmetic injection of fillers in the lips and perioral and nasolabial regions.

References

1. Narins RS, Brandt F, Leyden J, et al. A randomized, double-blind, multicenter comparison of the efficacy and tolerability of Restylane versus Zyplast for the correction of nasolabial folds. *Dermatol Surg* 2003;29:588-95.
2. Niamtu J. Local anesthetic blocks of the head and neck for cosmetic facial surgery. Part I. A review of basic sensory neuroanatomy. *Cosmet Dermatol* 2004;17:515-22.

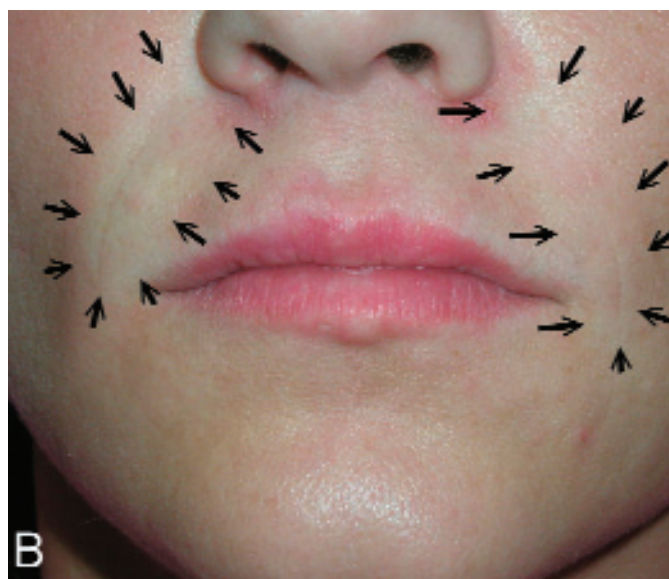
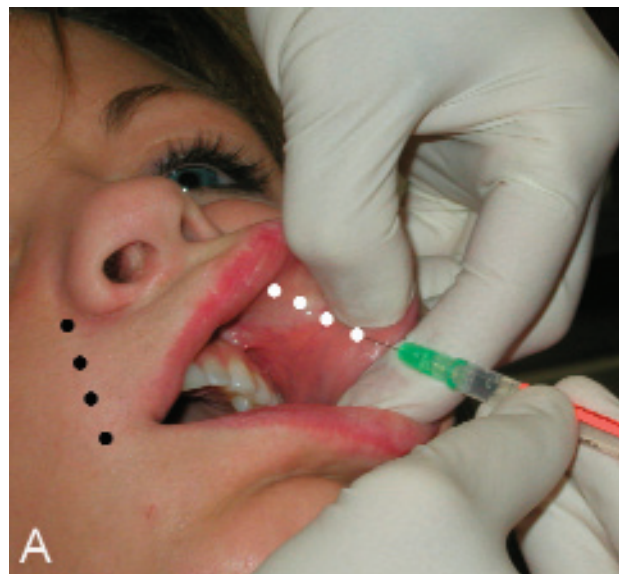
Figure 3. (A) The *black dots* show the skin surface of the nasolabial fold, and the *white dots* show the corresponding injection points for the mucosal side of the nasolabial folds. B shows the blanched areas outlined by *arrows* to illustrate the extent of the area anesthetized.

3. Niamtu J. Local anesthetic blocks of the head and neck for cosmetic facial surgery. Part II. Techniques for the upper and midface. *Cosmet Dermatol* 2004;17:583-7.
4. Niamtu J. Local anesthetic blocks of the head and neck for cosmetic facial surgery. Part III. Techniques for the maxillary nerve. *Cosmet Dermatol* 2004;17:645-7.