

Advanta ePTFE Facial Implants in Cosmetic Facial Surgery

Joseph Niamtu, III, DMD*

Cosmetic rejuvenation of the lips, facial folds, and wrinkles are frequently sought after procedures. A rise in the popularity of cosmetic surgery has made minimally invasive procedures extremely popular. Over the years, many types of fillers have been used to augment the face. These include silicone, fat, expanded polytetrafluoroethylene (ePTFE), cadaver dermis, bovine collagen, hyaluronic acid, hydroxyapatite and methylmethacrylate microspheres, and many other products or preparations.¹⁻⁷ Each type of filler has relative advantages and disadvantages and historically fall in and out of favor for soft tissue facial augmentation.

Expanded polytetrafluoroethylene was synthesized by the W.L. Gore Company and has been used safely and effectively in the human body for over 30 years for various applications in vascular and cosmetic surgery. Many articles have described the use of ePTFE for cosmetic facial surgical applications.⁸⁻⁴⁴ This author has been placing soft tissue ePTFE facial implants for 10 years.⁸⁻¹¹ These implants have been very successful in subperiosteal placement or in subdermal placement in the upper face. One problem this author has encountered with previous ePTFE implantation in the lips is that the implants became hardened, distorted and less pliable, especially in more superficial applications (Fig 1).

Although none of these patients experienced infection or untoward histologic effects, the implants became more palpable and frequently visible in areas of increased tissue movement. Patients reported that the implants felt stiff or that they could see the implants on animation. Due to this, some of these implants were removed. Explantation is uneventful as extreme tissue in growth is rare with the biologically compatible ePTFE. Due to these perceived problems, the

author ceased further soft tissue implantation in the lips with ePTFE for a number of years.

Several colleagues reported the successful use of ePTFE that is produced with a new manufacturing process for soft tissue facial augmentation that led to a renewed interest by this author.^{45,46}

Advanta facial implants are made by Atrium Medical Corporation (Hudson, NH). The main differences between Advanta implants and other ePTFE products is the manufacturing process and a dual porosity design. The implants undergo a sintering process that heats the material and stabilizes the dimensions and porosity. This heating process contributes to the physical properties and decreases implant shrinkage and stretching. As other available ePTFE implants consist of a uniform structure of 20 μm the Advanta ePTFE implant has a dual porosity configuration. Cross sectionally the Advanta implant has a smooth, medium porosity outer core of 50 μm and high porosity soft inner core of 100 μm (Fig 2). This softer, more porous construction improves cellular integration with less inflammatory response and less rigid encapsulation.⁴⁷ This dual porosity structure is also responsible for a softer look and feel with increased tissue response and implant stabilization.⁴⁷

Clinical Applications

Like other ePTFE implants, the Advanta implant can be used to augment lips, lines and wrinkles such as nasolabial folds, mentolabial folds, glabellar lines, or defects from acne, hypoplastic scars, and traumatic defects. Although the author has used the Advanta implant in all of these applications, the cosmetic augmentation of lips remains the most requested area for implantation in his practice.

Patient Selection

In theory, any healthy patient is a candidate for ePTFE implantation. Many options exist for lip augmentation but some patients are quite resistant to "needle procedures" or those procedures requiring repeated injections. Although some patients are resistant to the thought of "foreign body" implantation

*Private Practice, Richmond, VA.

Address correspondence and reprint requests to Dr Niamtu: Alexander, Keeney, Harris & Associates, 10230 Cherokee Road, Richmond, VA 23235; e-mail: niamtu@niamtu.com

© 2006 American Association of Oral and Maxillofacial Surgeons
0278-2391/06/6403-0030\$32.00/0
doi:10.1016/j.joms.2005.11.022

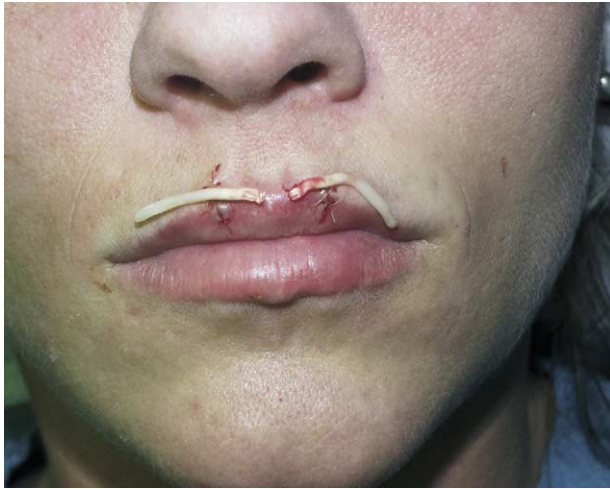

FIGURE 1. Hardened and contracted lip ePTFE implants removed from a patient at 12 months. These smaller implants were originally placed to augment the “white roll” of the upper lip.

Joseph Niamtu. Advanta Implants in Cosmetic Facial Surgery. J Oral Maxillofac Surg 2006.

other patients are intrigued by the thought of a one-time procedure that is “permanent.”

The author’s experience has shown certain professional or occupational conditions should be considered before placing lip implants (or injectable filler substances for that matter). Any person whose vocation or hobby requires precise oral function should be informed that changing the lip structure with implants (or fillers) could possibly affect lip function. The author placed an implant in a flute player and she stated she was unable to play high notes. Additionally, patients that manifest oral habits such as onychophagia (nail biting), pencil biting, nervous habits such as “fidgeting” with their lips, or possess psychological problems may be poor candidates for lip implantation. These relative contraindications are explained to all patients at consultation. The author suggests that the patient first try a reversible lip augmentation procedure such as Restylane (hyaluronic acid, Medicis Inc, Scottsdale, AZ) injection. If they are pleased with the look and feel of the augmentation, then the Advanta lip implant may be considered. It is further explained to the patient that these implants are easily removable with local anesthesia should the patient be dissatisfied. The patient is also informed that any implant (chin, breast, etc) is palpable and visible in some positions or animations.

Procedure

Advanta facial implants are available in various sizes and configurations. Round or oval implants are available from 1.8 to 5 mm diameter. In addition some sizes have an attached swaged trocar that is very

useful for implantation. In most cases the author prefers the 5 mm round implant. For small patients or those requesting minimal augmentation a 4 mm round implant is used. These larger sizes are not available with attached trocars and it would behoove the manufacturer to consider this addition. The implants are packaged sterile in a 15 cm length.

The implants are usually placed with local anesthesia blocks and infiltration. It is important not to overly infiltrate the lips as not to distort the anatomy that can skew the intraoperative surgical judgment. With experience the entire procedure takes about 5 minutes per lip. Although most patients request bilabial augmentation, some patients choose to only treat one lip. Several of these patients have returned to have the other lip augmented as well.

The implant is measured and cut to fit the proposed site. In some patients the 15 cm implant can be cut in half to produce 2 implants, 1 for each lip. Depending on the size and length of the lips only a single implant can be used from the 15 cm strand. The author has inadvertently placed too short an implant in an attempt to use a single 15 cm strand for two implants. To measure the patient, the implant is laid on the patient’s lip with the mouth open position (Fig 3). Failure to measure with the mouth open can result in too short an implant and a poor clinical result.

After the local anesthesia and prep with a surgical cleanser, a 6 to 8 mm stab incision is made in the lip several millimeters medial to the oral commissure within the vermilion tissue. This incision must be generous enough so as not to distort the implant that is somewhat ductile. If the incision is too small, the

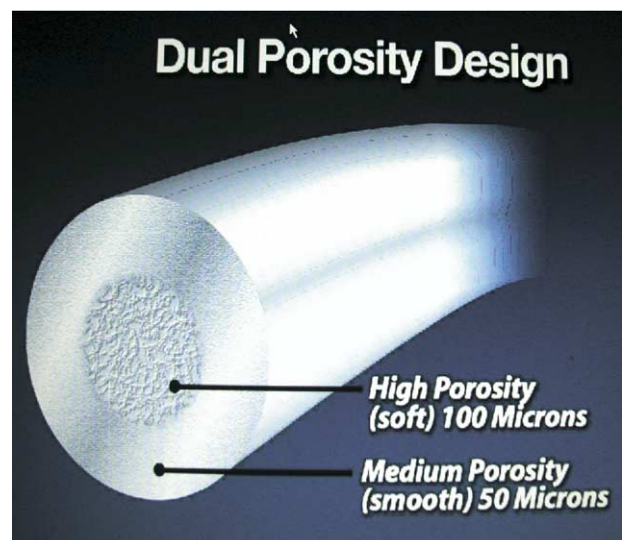


FIGURE 2. The dual porosity configuration provides the main differences of other ePTFE implants.

Joseph Niamtu. Advanta Implants in Cosmetic Facial Surgery. J Oral Maxillofac Surg 2006.

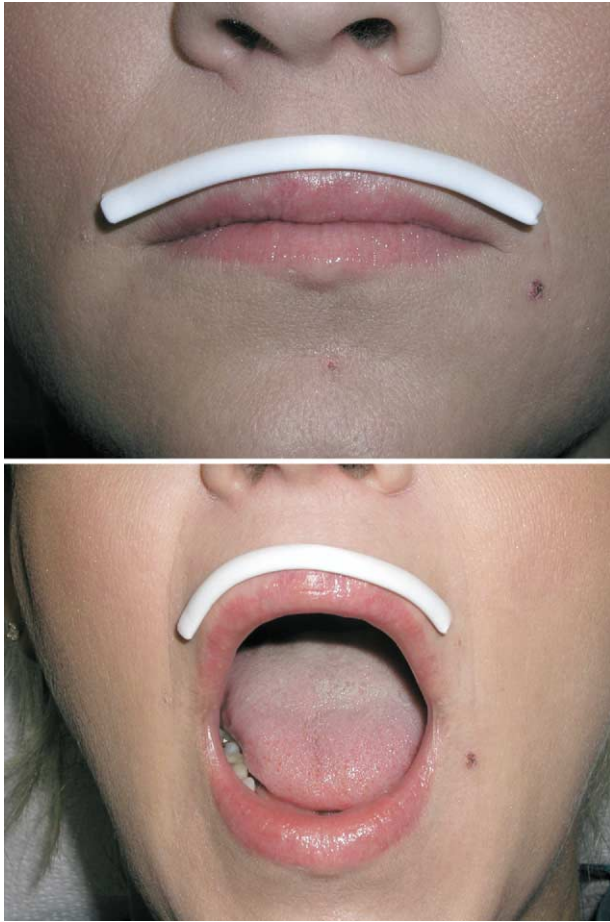


FIGURE 3. The top picture shows an implant measured on the patient's upper lip in repose. The lower picture is the same implant shown with the patient's mouth wide open. In this posture the implant would be too short. The point is to measure prospective implant length with the mouth wide open.

Joseph Niamtu. Advanta Implants in Cosmetic Facial Surgery. J Oral Maxillofac Surg 2006.

implant will be stretched into a cone shape instead of the round configuration. This will cause one side to be larger than the other side. The next step is to thread an instrument through the midportion of the lip from one incision and exiting the other incision (Fig 4A shows the round 5 mm implant and Fig 4B shows the threaded tendon passer). The attached trocar is convenient or a tendon passer may be used. It is important to remain in the same plane for the entire threading process or the implant will distort the lip or not sit naturally within the tissue.

Staying within the mid portion of the lip will avoid the labial artery that generally course through the posterior one-third of the lip closer to the incisal surface of the lip at the wet/dry line or the mucocutaneous junction (Fig 5). If the implant sits too deep, less augmentation is appreciated and if placed too superficially, it may be visible, palpable, and unnatural looking.

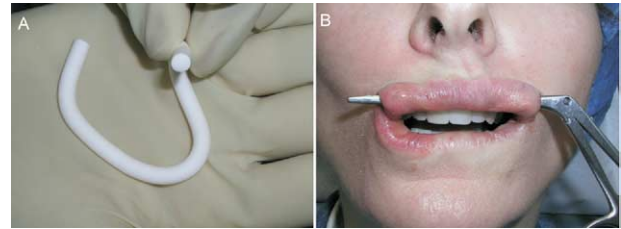


FIGURE 4. A, Round 5 mm implant. B, Tendon passer inserted through the middle of the upper lip from the entrance incision to the exit incision.

Joseph Niamtu. Advanta Implants in Cosmetic Facial Surgery. J Oral Maxillofac Surg 2006.

If a trocar is used, the implant is pulled through the lip with approximately 1 cm of implant protruding through the distal incision. When using a passing instrument other than a trocar, the leading edge of the implant is tapered thereby facilitating the threading process. If a passing instrument is used the instrument is first placed through the lip and the implant is grasped and pulled back from the original puncture site (Fig 6).

It is important to then stretch the lip horizontally to passively admit the implant to the full length of the lip. The implant is then trimmed to protrude approximately 3 mm on each side. The lip is then stretched and the implant will passively fall into the incision. It is paramount to have the implant ends tapered and to

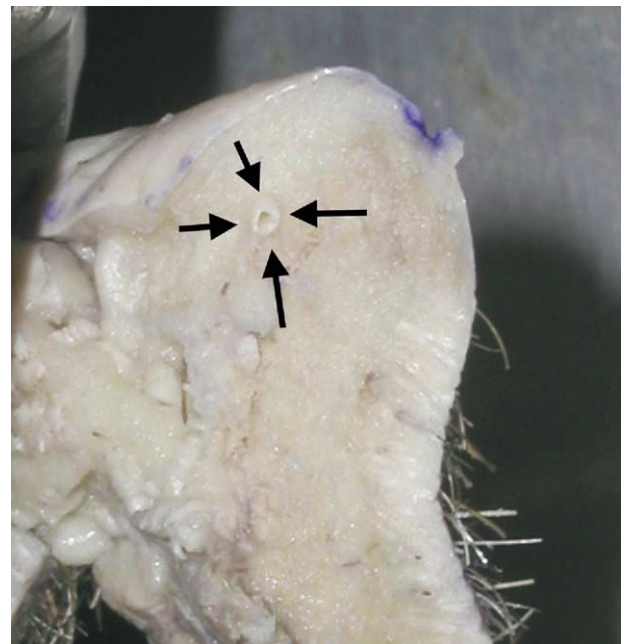


FIGURE 5. The labial artery of the lower lip (arrows) is shown in this cadaver dissection. The artery traverses the upper lip in the posterior 1/3 of the lip at the level of the vermilion-cutaneous junction and also corresponds to the incisal edges of the lower incisors.

Joseph Niamtu. Advanta Implants in Cosmetic Facial Surgery. J Oral Maxillofac Surg 2006.

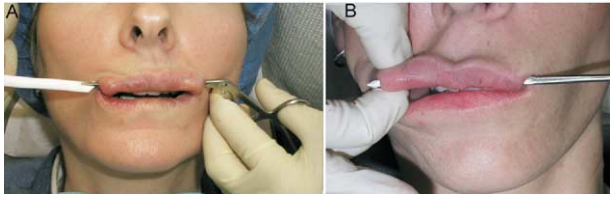


FIGURE 6. A, Implant grasped by the inserted tendon passer. B, ePTFE implant pulled through the lip tunnel with several millimeters of implant protruding at the exit incision.

Joseph Niamtu. *Advanta Implants in Cosmetic Facial Surgery.* *J Oral Maxillofac Surg* 2006.

tuck into the incisions within the mid portion of the lip. Having the implant tip too superficial to the skin or mucosa can result in a noticeable and palpable lump or eventual erosion of the implant tail. The incisions are then closed with 6-0 nylon sutures as experience has shown resorbable sutures to dehiscence prematurely. The patient is prescribed a suitable oral antibiotic and tapering steroids are an option. The nylon sutures are removed at 5 days.

Recovery is generally a weekend situation although some patients return to work the following day. All patients are forewarned that significant swelling may be encountered, although this has been a rare finding. Significant pain has not been seen by the author. The patient is asked to keep lip function to a minimum for the first several days.

Facial Folds and Lines

Advanta facial implants can also be placed in anatomic folds or hyperfunctional lines. They will not ablate the fold but can blunt the fold or line to improve the cosmetic appearance. Strict attention to implant placement is imperative in the nasolabial region. Because various anatomic planes converge at the nasolabial fold, any injectable or implantable material can easily migrate laterally and actually accentuate the fold instead of improving it. One would normally think that placement directly in the valley of the fold would be accurate but fillers or implants can migrate laterally, thereby worsening the fold. To circumvent this problem, the implant is generally placed just medial (nasally) to the fold. The area is anesthetized with bilateral infraorbital blocks and a small amount of infiltration along the fold. A stab incision is made lateral to the ala and at the inferior extent of the fold. A 2-mm liposuction cannula is used without suction to gently make a tunnel just medial to the nasolabial fold entering at the inferior stab incision and exiting at the alar incision. The correct plane of dissection is subdermal (Fig 7). It is important not to make the tunnel too wide or the degree of augmentation will be diminished. In addition, a large lateral

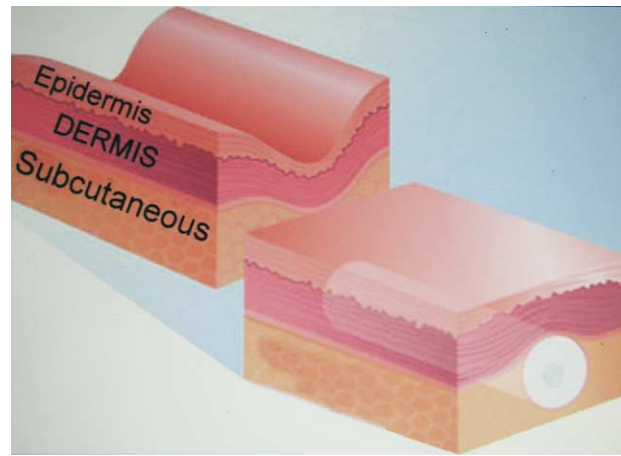


FIGURE 7. The correct plane for implant placement on the facial tissues (non lip) is subdermal.

Joseph Niamtu. *Advanta Implants in Cosmetic Facial Surgery.* *J Oral Maxillofac Surg* 2006.

dissection can facilitate implant migration. The tunnel only needs to be slightly larger than the proposed implant. The implant can be pulled through the tunnel with a passing instrument, passing awl and suture or integrated trocar with some Advanta implant sizes (Fig 8A). The implant is pulled through the incision from superiorly to inferiorly and the ends are tapered so that 3 to 4 mm of implant tail protrudes from each incision (Fig 8B). The lip is then bimanually palpated and stretched with one hand in the cheek and one hand on the face so that the tissue is stretched and the implant tails will fall passively into the incisions. The tails should fall just short of the incision and can be further tucked deep into the incision. The incisions are then closed with 6-0 nylon suture.

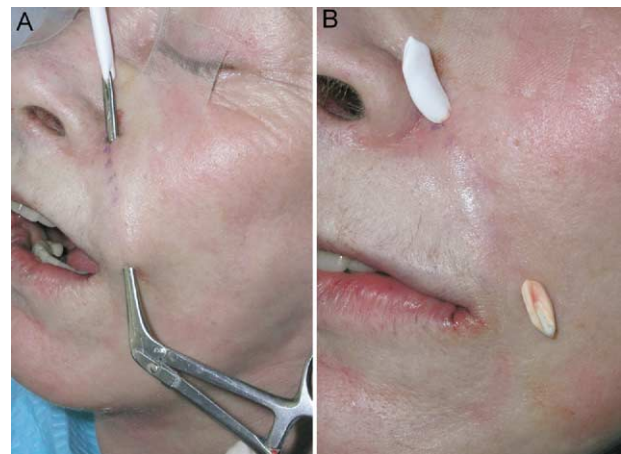


FIGURE 8. A, Tendon passer traversing just medial to the nasolabial fold and grasping the implant at the exit incision. B, Implant in place before trimming the tails.

Joseph Niamtu. *Advanta Implants in Cosmetic Facial Surgery.* *J Oral Maxillofac Surg* 2006.

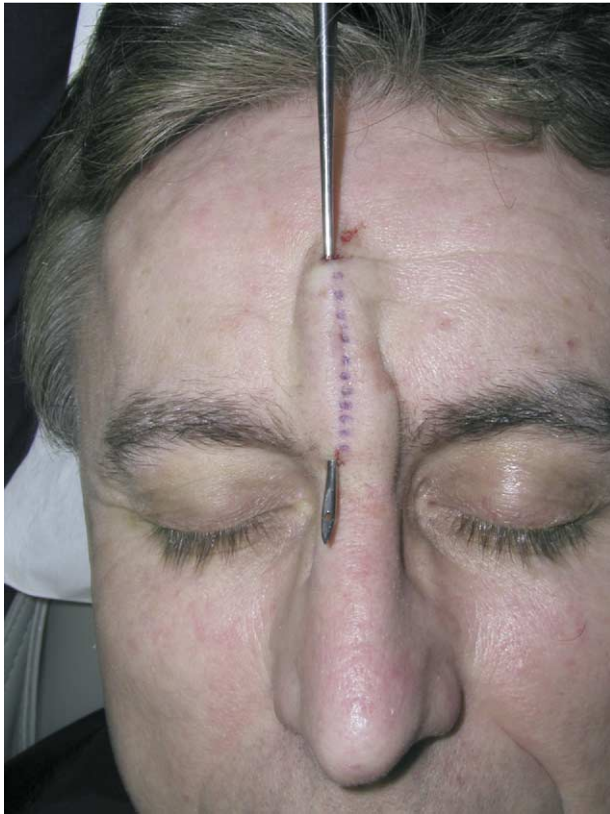

FIGURE 9. A passing awl is placed in the subdermal plane to pull an ePTFE implant back through the incision via an attached suture.

Joseph Niamtu. Advanta Implants in Cosmetic Facial Surgery. J Oral Maxillofac Surg 2006.

The same process can be carried out in the glabella for deep lines of folds resistant to Botox or other therapies. The surgical procedure is similar to the nasolabial folds. An entrance and exit stab incision is made and the tunnel is dissected. The implant may be

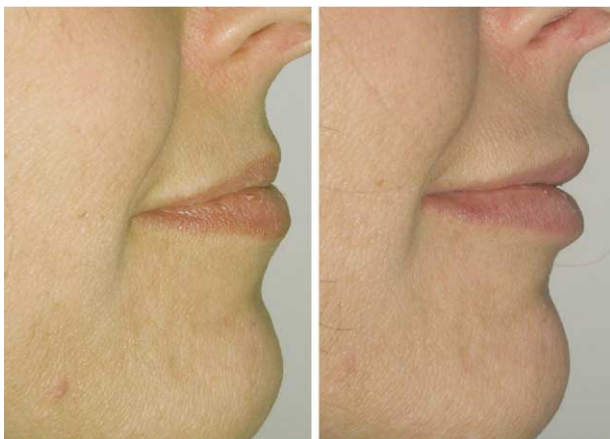

FIGURE 10. This patient is shown 8 weeks after placement of Advanta implants in the upper and lower lip.

Joseph Niamtu. Advanta Implants in Cosmetic Facial Surgery. J Oral Maxillofac Surg 2006.

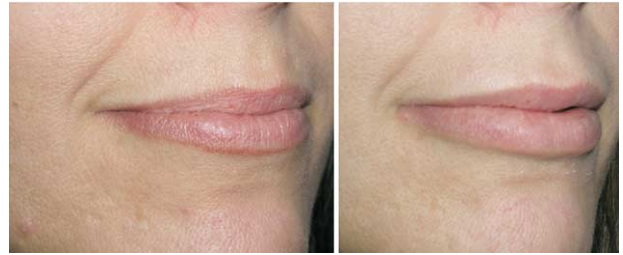

FIGURE 11. An oblique view of the same patient shown in Figure 10.

Joseph Niamtu. Advanta Implants in Cosmetic Facial Surgery. J Oral Maxillofac Surg 2006.

passed with a tendon passer, passing awl or an attached trocar (Fig 9).

For severe glabellar folds the author has used Advanta implants, Botox, and laser resurfacing concomitantly for a multiple modality treatment.

Results

The Advanta lip implant is soft and pliable, but it can be felt by the patient when pinching the lip. The outline of the implant may be visible in some extreme lip posture such as stretching the lip over the front teeth. With the exception of a single patient who was a flute player, no patient in this series has reported any problems with normal function such as eating, talking, or kissing. Patients with Advanta lip implants have been later treated with injectable fillers such as Restylane for further augmentation without any problems. Figures 10–14 show clinical cases of Advanta implant placement.

Complications

Of 72 implants placed in 44 patients over a 31-month period, a single implant became infected. Two

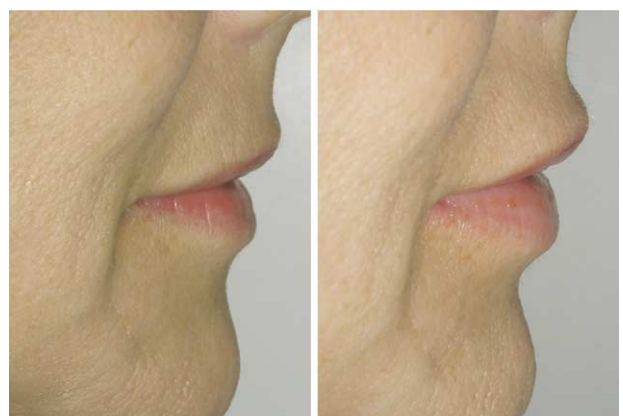

FIGURE 12. This patient is shown 2 months after Advanta implant placement in the upper and lower lips. Note increased pout and volume of both lips.

Joseph Niamtu. Advanta Implants in Cosmetic Facial Surgery. J Oral Maxillofac Surg 2006.

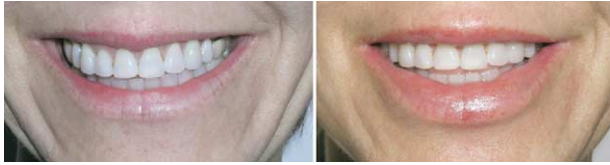

FIGURE 13. This image shows the same patient as pictured in Figure 12. Smiling and normal oral function is not impeded with this soft and pliable implant.

Joseph Niamtu. *Advanta Implants in Cosmetic Facial Surgery. J Oral Maxillofac Surg 2006.*

patients reported the implant being too short and these were removed and replaced with a longer implant. Early in the experience the implants were measured by placing the material over the upper or lower lip in the closed mouth position. As mentioned previously, it is imperative to measure the implant with the mouth at maximum opening as the lips are longer in this position. The author has also abandoned the practice of trying to obtain 2 implants from a single 15 cm strand. The entire implant is now used and insufficient length is not a problem.

One patient developed significant swelling that did not resolve over a month. The area was treated with antibiotics and tapering steroids and failed to resolve. Surgical exploration showed a mucous retention phenomenon that most likely resulted from trauma to the minor salivary glands at the time of implant placement. The implant was removed and the patient desires replacement. Two patients complained of the tail of the implant being visible and palpable at one end of the lip or nasolabial fold (Fig 15A). This was a result of the implant not being placed in the correct plane at the time of placement. The superficial portion of the implant was exposed with a several millimeter minimal incision. A skin hook was used to retrieve the protruding portion of the implant that was then trimmed and replaced back into the soft

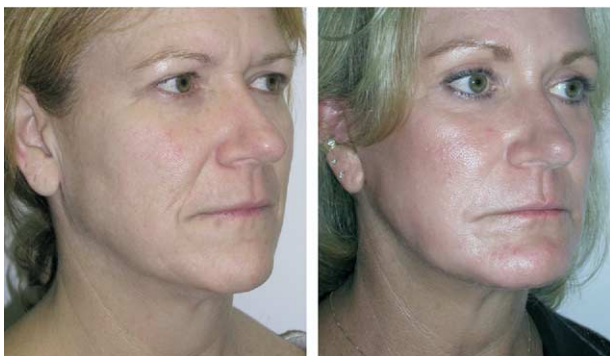

FIGURE 14. This patient is shown 2 months after Advanta implants to both nasolabial folds with concomitant laser resurfacing.

Joseph Niamtu. *Advanta Implants in Cosmetic Facial Surgery. J Oral Maxillofac Surg 2006.*

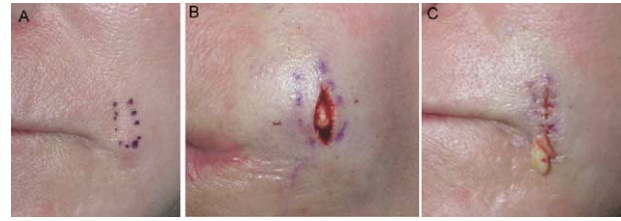


FIGURE 15. A, Visible and palpable tail of an implant placed too superficially (outlined with surgical marker) on the left nasolabial fold. B, Protruding implant tail after incision. C, Trimmed implant tail resting over the sutured incision to show the amount of implant tail trimmed.

Joseph Niamtu. *Advanta Implants in Cosmetic Facial Surgery. J Oral Maxillofac Surg 2006.*

tissue pocket (Figs 15B,C). None of these procedures resulted in infection or problem and both patients were pleased with the repair.

Implant removal is not complicated and can be carried out with local anesthesia. The end of the implant is palpated and a 4 to 5 mm stab incision is made through the overlying vermilion lip tissue. A small hemostat is used to bluntly spread the tissues to expose the tail of the implant while pushing the implant toward the skin from the inside of the mouth. Once the implant tail is located, a larger hemostat is attached firmly and traction is placed on the implant that will pull out but requires significant traction. No implants have torn or separated on removal. No post removal complications have been reported or visualized and lip function returned to normal.

Seventy-two implants were placed in 44 patients over a 31-month period. In accessing implant tissue compatibility there were no cases of implant rejection or instability. No case of implant removal was related to product performance. A single implant was removed due to infection. Two implants were removed in a patient who did not state preoperatively that she played the flute. She felt afterwards that the implants impeded her playing of high notes. Three other implants were removed because the patients did not like having larger lips. The surgeon, staff, and all patients remain pleased at the esthetics and function of the augmentations.

In general the clinical experience has been very favorable for the surgeon and patient and the implants are simple to place, provide a natural augmentation without compromising normal lip function, are serviceable, and can be removed easily. Advanta facial implants seem to have a place in the armamentarium of oral and maxillofacial surgeons that carry out cosmetic facial surgery.

References

1. Hotta T: Dermal fillers. The next generation. *Plast Surg Nurs* 24:14, 2004

2. Narins RS, Brandt F, Leyden J, et al: A randomized, double-blind, multicenter comparison of the efficacy and tolerability of Restylane versus Zyplast for the correction of nasolabial folds. *Dermatol Surg* 29:588, 2003
3. Brown LH, Frank PJ: What's new in fillers? *J Drugs Dermatol* 2:250, 2003
4. Lemperle G, Morhenn V, Charrier U: Human histology and persistence of various injectable filler substances for soft tissue augmentation. *Aesthetic Plast Surg* 27:354, 2003
5. Niamtu J: The use of Restylane in cosmetic facial surgery. *J Oral Maxillofac Surg* 64:317, 2006
6. Niamtu J: Clinical technique for fat transfer, *in* *Cosmetic facial surgery oral and maxillofacial surgery clinics of North America*. Philadelphia, WB Saunders, 2000, pp 641-647
7. Niamtu J: Fat transfer gun used as a precision injection device for injectable soft tissue fillers. *J Oral Maxillofac Surg* 60:838, 2002
8. Niamtu J: Perioral soft tissue rejuvenation techniques. *Compendium Journal* vol 22, number 11, 2003, pp 729-736
9. Niamtu J: Alloplastic chin augmentation, *in* *Cosmetic facial surgery, oral and maxillofacial surgery clinics of North America*. Philadelphia, WB Saunders, 2000, pp 765-769
10. Niamtu J III: Cosmetic oral and maxillofacial surgery options. *J Am Dent Assoc* 131:756, 2000
11. Niamtu J: Facial implant applications for cosmetic facial surgery. *Plastic Surgery Products*, Novicom Publications, vol 8, number 5, pp 26-29
12. Panossian A, Garner WL: Polytetrafluoroethylene facial implants: 15 years later. *Plast Reconstr Surg* 113:347, 2004
13. Ham J, Miller PJ: Expanded polytetrafluoroethylene implants in rhinoplasty: Literature review, operative techniques, and outcome. *Facial Plast Surg* 19:331, 2003
14. Prabhat A, Dyer WK 2nd: Improving surgery on the aging neck with an adjustable expanded polytetrafluoroethylene cervical sling. *Arch Facial Plast Surg* 5:491, 2003
15. LaFerriere KA: The adjustable sling in corrective surgery for the aging neck: A promising technique when used with caution. *Arch Facial Plast Surg* 5:502, 2003
16. Godin M, Costa L, Romo T, et al: Gore-Tex chin implants: a review of 324 cases. *Arch Facial Plast Surg* 5:224, 2003
17. Steinsapir KD: Aesthetic and restorative midface lifting with hand-carved, expanded polytetrafluoroethylene orbital rim implants. *Plast Reconstr Surg* 111:1727, 2003
18. Romo T 3rd, Baskin JZ, Scalfani AP: Augmentation of the cheeks, chin and pre-jowl sulcus, and nasolabial folds. *Facial Plast Surg* 17:67, 2001
19. Choe KS, Stucki-McCormick SU: Chin augmentation. *Facial Plast Surg* 16:45, 2000
20. Constantinides MS, Galli SK, Miller PJ, et al: Malar, submalar, and midfacial implants. *Facial Plast Surg* 16:35, 2000
21. Scalfani AP, Romo T 3rd: Biology and chemistry of facial implants. *Facial Plast Surg* 16:3, 2000
22. Singh S, Baker JL Jr: Use of expanded polytetrafluoroethylene in aesthetic surgery of the face. *Clin Plast Surg* 27:579, 2000
23. Beaty MM: Treatment of neck laxity with a Gore-Tex cervical sling for patients with heavy neck tissues. *Facial Plast Surg* 17:117, 2001
24. Brody HJ: Complications of expanded polytetrafluoroethylene (e-PTFE) facial implant. *Dermatol Surg* 27:792, 2001
25. Maas CS, Denton AB: Synthetic soft tissue substitutes: 2001. *Facial Plast Surg Clin North Am* 9:219, 2001
26. Louis PJ, Cuzalina LA: Alloplastic augmentation of the face. *Atlas Oral Maxillofac Surg Clin North Am* 8:127, 2000
27. Cox AJ 3rd, Wang TD: Skeletal implants in aesthetic facial surgery. *Facial Plast Surg* 15:3, 1999
28. Homsy CA: Complications and toxicities of implantable biomaterials for facial aesthetic and reconstructive surgery. *Plast Reconstr Surg* 102:1766, 1998
29. Lewis RP, Schweitzer J, Odum BC, et al: Sheets, 3-D strands, trimensional (3-D) shapes, and sutures of either reinforced or nonreinforced expanded polytetrafluoroethylene for facial soft-tissue suspension, augmentation, and reconstruction. *J Long Term Eff Med Implants* 8:19, 1998
30. Garner WL: Gore-Tex facial implants. *Plastic Surgery Educational Foundation DATA Committee*. *Plast Reconstr Surg* 100:1899, 1997
31. Saccoanno F, Bernardi C, Vittorini P: The expanded polytetrafluoroethylene (ePTFE) in the surgical treatment of Parry-Romberg syndrome: case report. *Aesthetic Plast Surg* 21:342, 1997
32. Still EF 2nd: Gore-Tex in facial augmentations. *Plast Reconstr Surg* 99:1468, 1997
33. Scalfani AP, Thomas JR, Cox AJ, et al: Clinical and histologic response of subcutaneous expanded polytetrafluoroethylene (Gore-Tex) and porous high-density polyethylene (Medpor) implants to acute and early infection. *Arch Otolaryngol Head Neck Surg* 123:328, 1997
34. Milam SB: Failed implants and multiple operations. *Oral Surg Oral Med Oral Pathol Oral Radiol Endod* 83:156, 1997
35. Maas CS: ePTFE (Gore-Tex) facial augmentation. *Plast Reconstr Surg* 97:1076, 1996
36. Sherris DA, Larrabee WF Jr: Expanded polytetrafluoroethylene augmentation of the lower face. *Laryngoscope* 106:658, 1996
37. Levine B, Berman WE: The current status of expanded polytetrafluoroethylene (Gore-Tex) in facial plastic surgery. *Ear Nose Throat J* 74:681, 1995
38. Schoenrock LD, Chernoff WG: Subcutaneous implantation of Gore-Tex for facial reconstruction. *Otolaryngol Clin North Am* 28:325, 1995
39. Owsley TG, Taylor CO: The use of Gore-Tex for nasal augmentation: a retrospective analysis of 106 patients. *Plast Reconstr Surg* 94:241, 1994
40. Cisneros JL, Singla R: Intradermal augmentation with expanded polytetrafluoroethylene (Gore-Tex) for facial lines and wrinkles. *J Dermatol Surg Oncol* 19:539, 1993
41. Maas CS, Gnepp DR, Bumpous J: Expanded polytetrafluoroethylene (Gore-Tex soft-tissue patch) in facial augmentation. *Arch Otolaryngol Head Neck Surg* 119:1008, 1993
42. Conrad K, Reifen E: Gore-Tex implant as tissue filler in cheek-lip groove rejuvenation. *J Otolaryngol* 21:218, 1992
43. Lassus C: Expanded PTFE in the treatment of facial wrinkles. *Aesthetic Plast Surg* 15:167, 1991
44. Neel HB 3rd: Implants of Gore-Tex. *Arch Otolaryngol* 109:427, 1983
45. Truswell W: A new implant for facial soft tissue augmentation. *Arch Facial Plastic Surg* 4:92, 2002
46. Hanke CW: A new e-PTFE soft tissue implant for natural-looking augmentation of lips and wrinkles. *Dermatol Surg* 28:901, 2002
47. Williams SK, Patula VB, Kleinert LB, et al: Dual porosity expanded polytetrafluoroethylene for soft tissue augmentation. *Plast Reconstr Surg* 115:1995, 2005