

# Botulinum Toxin A: A Review of 1,085 Oral and Maxillofacial Patient Treatments

Joseph Niamtu III, DDS\*

**Purpose:** Botulinum toxin A (Botox; Allergan, Inc, Irvine, CA) has been used safely and effectively for the management of rhytids and dynamic lines of the face. Much of the initial anecdotal experience with Botox has changed with experience and is reported by the author.

**Patients and Methods:** In a 56-month period, 439 vials of Botox were used for primarily cosmetic improvement of facial lines and rhytids. Four hundred seventeen patients underwent 1,085 treatment episodes with an estimated 17,000 injections that were tracked on a database and reviewed.

**Results:** Botox is a safe and effective treatment for the temporary improvement of facial lines and dynamic rhytids in selected anatomic regions. The techniques of reconstitution, storage, use, dose, and technique may not be as sensitive as originally described.

**Conclusion:** When following minimal guidelines, the use of Botox for cosmetic facial applications is safe, predictable, and without serious complications and provides generalized patient satisfaction.

© 2003 American Association of Oral and Maxillofacial Surgeons

*J Oral Maxillofac Surg* 61:317-324, 2003

Botulinum toxin A (Botox; Allergan, Inc, Irvine, CA [BTA]) is a naturally occurring polypeptide chain molecule derived from the *Clostridium botulinum* bacterium. There are 7 distinct neurotoxins (BTA, -B, -C1, -D, -E, -F, and -G) produced by this bacterium. Botulinum toxin is the most toxic material known. It is 4 times more lethal in mice than tetanus toxin,  $1 \times 10^{10}$  more lethal than curare, and  $100 \times 10^{10}$  more lethal than sodium cyanide.<sup>1</sup> BTA has been used successfully since the early 1980s for the various cosmetic indications. The mechanism of action results from blocking the release of acetylcholine at the myoneural junction. BTA is a dichain molecule with a heavy and light chain. The heavy chain is responsible for selective binding of the neurotoxin to cholinergic nerve terminals, and the light chain acts intracellular to prevent acetylcholine release.<sup>2</sup>

In 1999 and 2000, the author reported on the cosmetic use of BTA for facial rhytids and dynamic lines.<sup>3,4</sup> Although the use of BTA for cosmetic concerns appeared in 1988, its widespread use did not occur until the mid-1990s. Also, there was much speculation about how to use BTA. Specifically, this spec-

ulation concerned storage and dilution, delivery methods, and appropriate treatment dosages. During the mid-1990s, BTA was also being used for lateral canthal lines (crow's feet), platysmal banding, orbicularis oris injection, masseter muscle injection, and the treatment of temporomandibular disorders (TMDs).

## Patients and Methods

The author examined his experience with BTA treatment over a 56-month period, which consisted of 1,085 separate patient treatments on 417 different patients with approximately 17,000 BTA injections using 439 vials of Botox.

Various dilutional schemes were compared, and clinical observations were made from this patient population. Cosmetic treatment consisted primarily of injecting the glabellar, frontalis, and lateral canthal regions.

Botox is shipped in a special Styrofoam container packed with dry ice. The unreconstituted BTA can be stored indefinitely in a conventional household freezer. Single vials of BTA were reconstituted by adding various dilutions of unpreserved saline. The reconstituted BTA was then drawn up in 1-mL tuberculin syringes and stored in a standard refrigerator until injected. The vast majority of patients were injected with no means of pain control and tolerated the procedure quite well. Apprehensive patients were treated with topical or local anesthesia or nitrous oxide/oxygen analgesia.

---

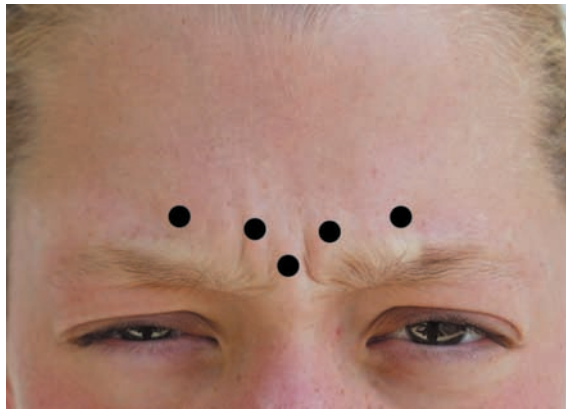
\*Group Private Practice, Richmond, VA.

Address correspondence and reprint requests to Dr Niamtu: Oral/Maxillofacial and Cosmetic Facial Surgery, 10230 Cherokee Rd, Richmond, VA 23235; e-mail: niamtu@niamtu.com

© 2003 American Association of Oral and Maxillofacial Surgeons

0278-2391/03/6103-0007\$30.00/0

doi:10.1053/joms.2003.50069

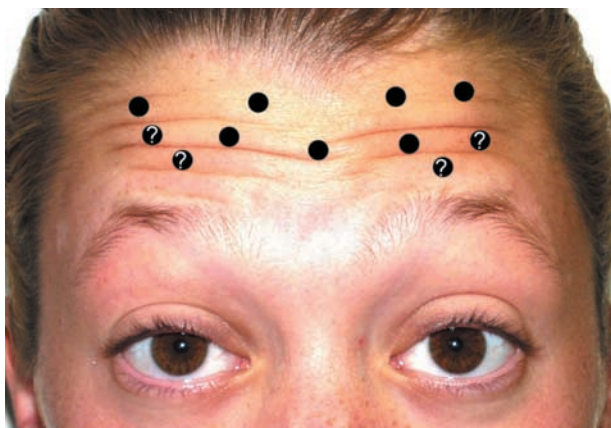


**FIGURE 1.** The patient is asked to scowl, and 4 units of Botox is injected in regions of maximum muscular contraction. This image illustrates a typical scenario of injection placement for glabellar dynamic lines.

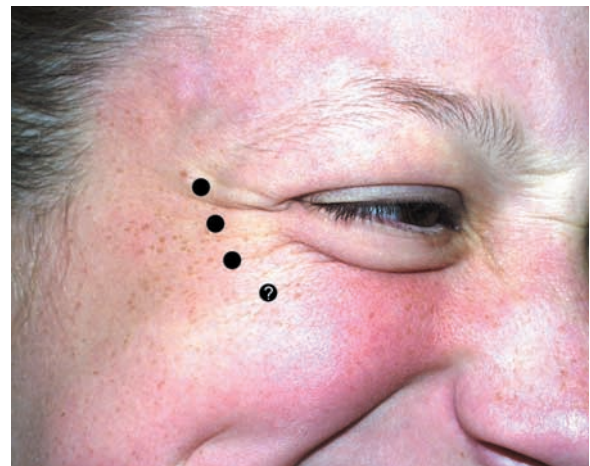#### BTA INJECTION TECHNIQUE OF THE UPPER FACE

After injecting thousands of sites in the upper face, the author abandoned previously described precision marking and measuring techniques<sup>3,4</sup> and disregarded needle angulation, making all injections perpendicular to the skin surface. The patient is simply asked to animate, and 2 to 4 units of BTA is injected into the region of muscle bulge. From 2 to 3 units is injected for thin muscles such as the orbicularis oculi and frontalis, and 4 to 5 units is injected for the procerus and corregator muscles. The only measurement heeded is to stay 10 mm away from the bony orbit. The generalized injection technique is illustrated in Figures 1 through 3. Due to anatomic variance, each patient presents a unique combination of dynamic rhytids on animation; thus the injections are tailored to that specific anatomy.

Treatment of the glabellar, frontalis, and lateral canthal regions are the hallmark of Botox injection. Ex-



**FIGURE 2.** Typical placement of Botox injections for frontalis wrinkles. The injection sites with question marks indicate optional injection sites depending on the amount of brow lift or brow animation desired.



**FIGURE 3.** The black dots indicate a typical pattern of lateral canthal injection with Botox. The question mark in the malar region indicates optional injection if the patient recruits the zygomaticus musculature as part of the dynamic lines.

amples of successful temporary rhytid effacement are shown in Figure 4.

Several patients with the complaint of mentalis wrinkling were successfully treated with injections of 1 to 2 units of Botox in the regions of muscle activity during animation with no compromise in perioral function (Fig 5).

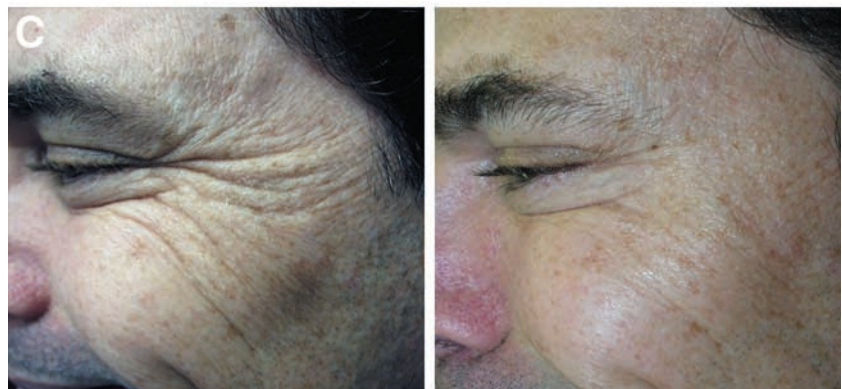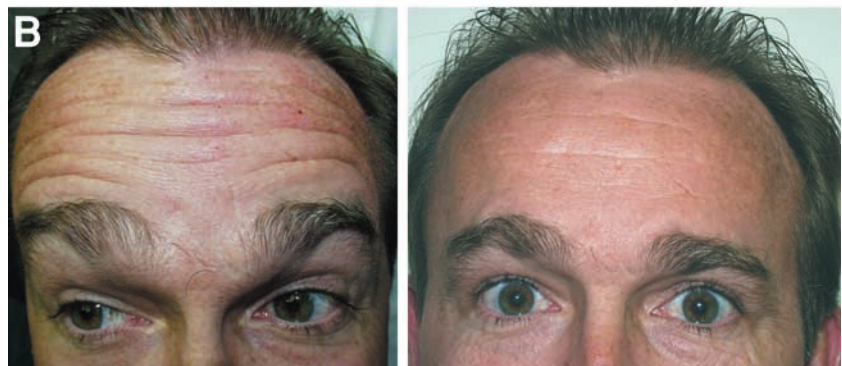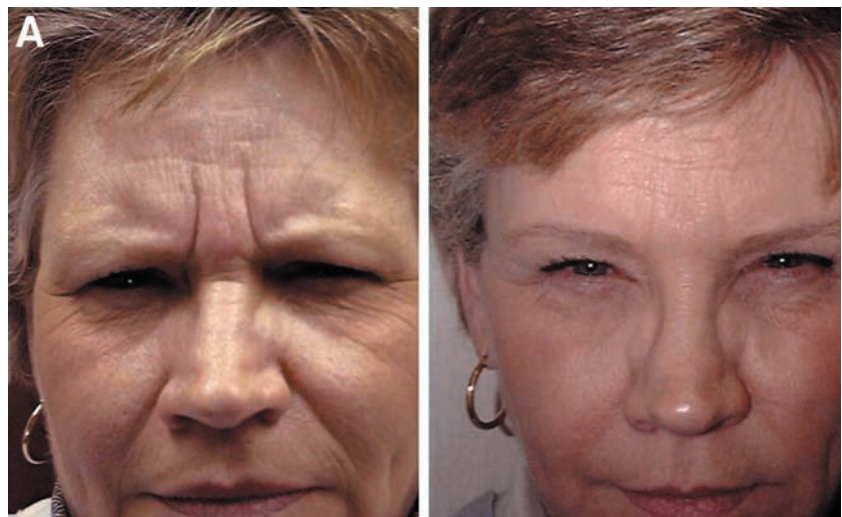#### HEADACHE AND TMDs

Multiple noncosmetic patients were injected for complaints of migraine headache and/or TMD symptoms. The glabella, frontalis, and crow's feet regions were injected in all of these patients. In addition, if the patient had pain or trigger regions in the temporalis or masseter muscles, 2 to 4 units of BTA was injected in these sites as well.

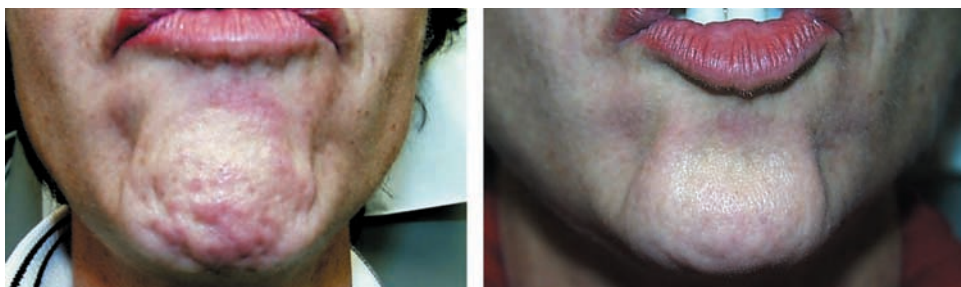#### Results

The author examined data regarding BTA treatment from January 1998 until article submission. During this 56-month period, 439 bottles of Botox were used for 1,085 separate treatments. These 1,085 treatments were performed on patients, indicating that many patients returned on a regular basis for additional treatment. Of these retreatments, 111 patient treatments were treated for "touch up" injections. These were patients who had insufficient paralysis in 1 or more regions at 10 days after initial treatment. In many cases, the paralytic effect was indeed adequate, but the patient desired zero movement with animation, and to please the patient, several 2- to 4-unit repeat injections were administered.

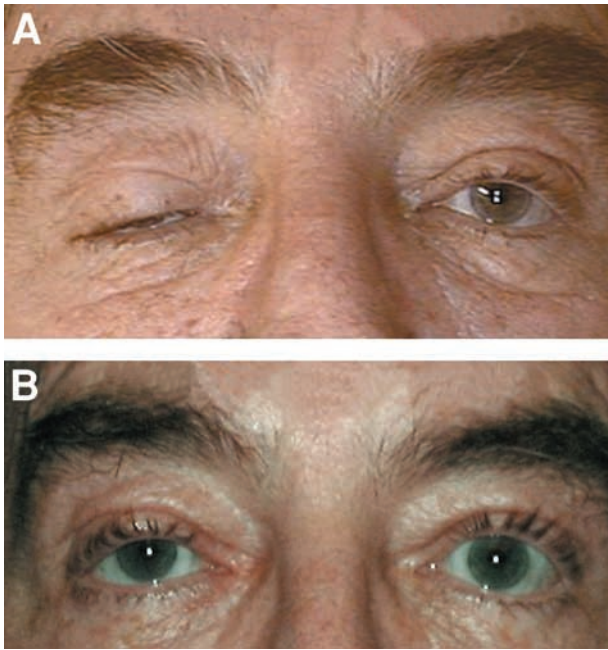
Three dilutional schemes were used. One hundred thirty-three patient treatments were performed with



**FIGURE 4.** A, Successful treatment of glabellar region. B, Successful frontalis treatment. C, Successful lateral canthal treatment.



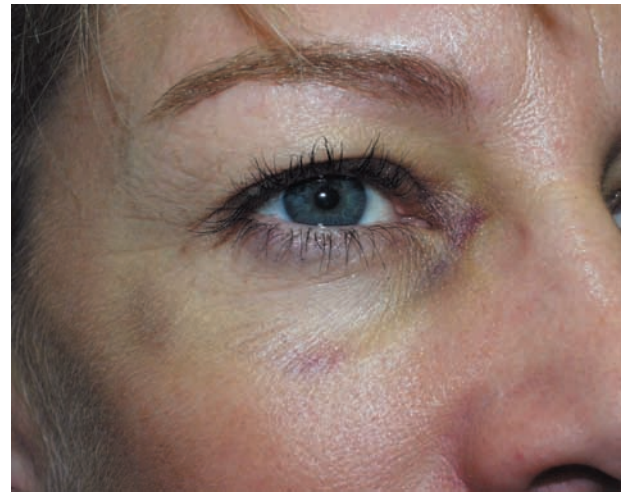
**FIGURE 5.** Chin puckering from mentalis activation can be successfully treated with Botox injections.



**FIGURE 6.** A, Patient 7 days after Botox was injected too close to the upper eyelid. B, The same patient 1 hour after placing apraclonidine (lopidine) drops to stimulate Mueller's muscle.

1-mL dilution of unpreserved saline per vial, and 174 patient treatments were performed with a 12-mL dilution of unpreserved saline per vial of BTA. Six hundred nine patient treatments were performed with a dilution of 6 mL of unpreserved saline per vial (Table 1).

Forty-eight patients were treated for headache or TMD-related headache. One patient was treated for platysmal banding, 3 patient treatments were for masseter hypertrophy, and 6 patient sessions were for

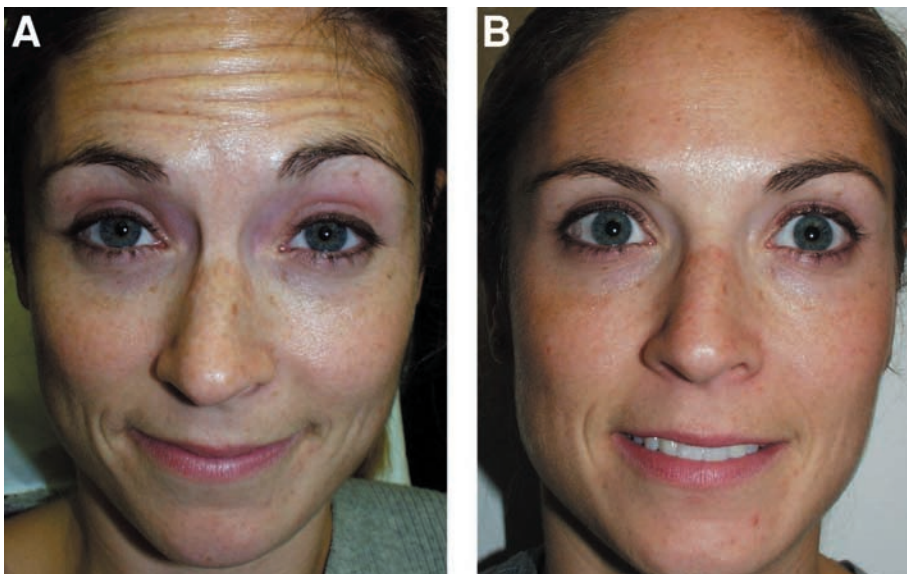


**FIGURE 8.** Unusual but significant periorbital bruising in a Botox patient who was taking large doses of aspirin for several weeks before injection.

perioral vertical (lipstick) lines. Two patients were treated for mentalis hyperactivity.

#### COMPLICATIONS

In the administration of 1,085 Botox treatments in 417 patients and an estimated 17,000 injections, we have seen very few complications. The only major complication was an upper eyelid ptosis that persisted for about 3 weeks (Fig 6). This was seen in one of our first patients and resulted from an injection that was too close to the upper lid in a patient with very ptotic eyebrows that were at a level below the orbital rim. This patient was treated with apraclonidine (Iopidine; Alcon Labs Inc, Ft Worth, TX) 0.5% drops used 30 minutes before social situations. This  $\alpha$ -adrenergic



**FIGURE 7.** A, Preinjection frontalis animation. B, Positive treatment result. Note that the patient can still elevate her brows but not to the degree as in the pretreatment photograph. In addition, the amount of upper lid exposure is decreased on frontalis animation.

**Table 1. TOTAL BTA (BOTOX) INJECTIONS FROM JANUARY 1998 TO JULY 2001 (53 MONTHS)**

|  |       |
|--|-------|
| Patients (n)   | 417   |
| Patient treatments (n)                               | 1,085 |
| Botox vials (n)                                      | 439   |
| Patient treatments with 1-mL dilution/100 U (n)      | 133   |
| Patient treatments with 6-mL dilution/100 U (n)      | 609   |
| Patient treatments with 12-mL dilution/100 U (n)     | 174   |
| Patient treatments for headache/TMD (n)              | 48    |
| Patient treatments for platysma banding (n)          | 1     |
| Patient treatments for perioral vertical lines (n)   | 6     |
| Patient treatments for masseter hypertrophy (n)      | 3     |
| Patients reinjected for residual muscle movement (n) | 111   |

Abbreviation: TMD, temporomandibular disorder.

agonist stimulates Mueller's muscle, causing several hours of transient lid opening. Theoretically, stimulating Mueller's muscle will improve lid opening by only 2 mm. We have treated several cases of upper lid ptosis caused by BTA injections performed by other practitioners, and the resultant lid elevation with apraclonidine was disappointing and not as dramatic as the case presented in Figure 6.

A number of first-time female Botox users reported a heavy feeling of their brows. In reality, these patients are used to persistently recruiting their frontalis muscles to elevate their brows. While evaluating patients for frontalis treatment, it is interesting to observe the amount of subconscious frontalis activation they have. If a patient persistently elevates his or her eyebrows through frontalis function, this patient must be warned that he or she may not be able to elevate the brows as much if the entire glabella and forehead are treated (Fig 7).

Many women do not notice this until they attempt to put on eye shadow a week later and they cannot elevate their brows as easily as before. Due to this, we usually do not treat the lower most frontalis wrinkles (question marks in Fig 2) so the patient can still preserve brow function. It is also interesting that in our series, some patients demand a total upper facial paralysis and complain if any brow or forehead wrinkling is present. On the contrary, many patients still wish to animate and should be treated more conservatively. An important point is to treat all first-time Botox patients in a more conservative manner; you can always touch up the regions that move, but if you cause an unwanted paralysis, the patient will have to wait months to overcome the effects.

The most common complication seen was postinjection bruising. This was seen primarily in the lateral canthal region and could usually be predicted by increased bleeding or immediate hematoma at the injection site. Although this spontaneously resolves over several days, it may be disconcerting for the patient. One patient developed significant periorbital

bruising and admitted to increased use of aspirin on a regular basis (Fig 8). Postinjection bruising has been kept to a minimum by the immediate placement of ice on a freely bleeding injection site and by keeping injections superficial. Especially in thin-skinned individuals, BTA will diffuse to the superficial muscles without deep injection. We routinely inject in a subcutaneous plane in regions close to visible blood vessels or in thin-skinned individuals.

Several patients reported transient headaches after Botox injection. In the several patients who complained of postinjection headache pain, we believe that it was the pain from 15 to 20 injections that was responsible for the headache and not the actual BTA. One patient reported severe headache for 3 weeks after the initial treatment but has subsequently returned for repeat treatment without headache problems.

Many practitioners provide patients with post-Botox injection precautions, such as not lying down for 4 hours, not exercising for 4 hours, and not flying for 24 hours. This theoretically reduces diffusion into unwanted regions. We have several patients who travel continually and have injected several pilots with no special precautions. None of these individuals have had unwanted diffusion from flying after Botox.

The Botox product insert cites 2 cases of cardiovascular collapse 3 weeks after having Botox injected for blepharospasm.<sup>5</sup> No cardiovascular problems were noted proximal to Botox injection in our patients

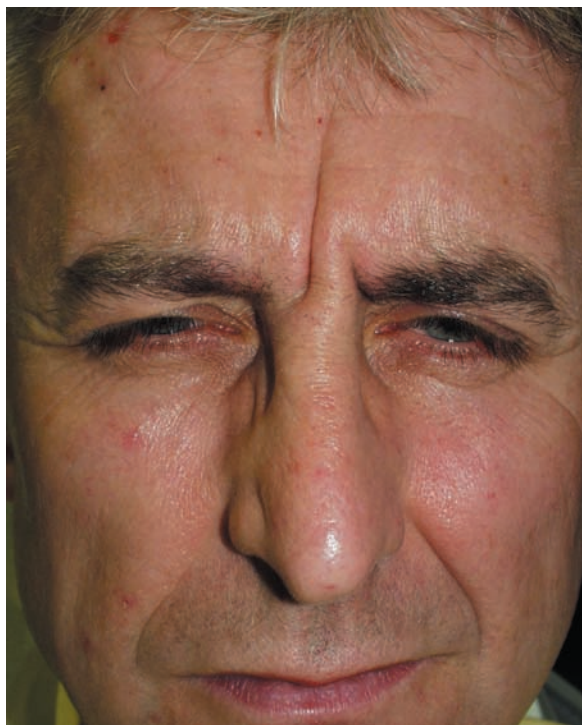#### RESISTANCE

In our series of 1,085 patient treatments, we have seen 2 patients (1 male and 1 female) who had no clinical paralytic effect from multiple Botox injections. Both of these patients were retreated with the same dose from a different vial of Botox and still showed absolutely no clinical effect. It has been hypothesized that some resistant individuals may have had subclinical botulism infection and are sensitized to BTA (A. Carruthers, J. Carruthers, personal communication, July, 2001). We are currently treating these patients with botulinum toxin B (Myoblock; Elan Pharmaceuticals, San Francisco, CA) to evaluate their response to this subtype of the toxin.

#### CLINICAL OBSERVATIONS AND IMPRESSIONS

In the 1,085 treatment sessions on 417 patients consisting of an estimated 17,000 BTA injections from 439 vials, multiple generalized now-quantified observations and impressions were made.

- Males seemed to take more units to paralyze a given region, presumably because they have larger muscle masses.



**FIGURE 9.** Typical scenario (male, thick skin, and large muscle bundles) of a patient who will require more BTA to achieve a clinical effect.

- Patients with thick or acneic skin require more units per region to achieve paralysis.
- Older patients may require more units per region to achieve desired results.
- Patients (of either gender) with large muscle masses require more units to achieve paralysis (Fig 9).
- Anatomic variations (high hairlines, large foreheads) require more units.
- Periorbital bruising may be minimized by extremely superficial injection and avoiding superficial blood vessels

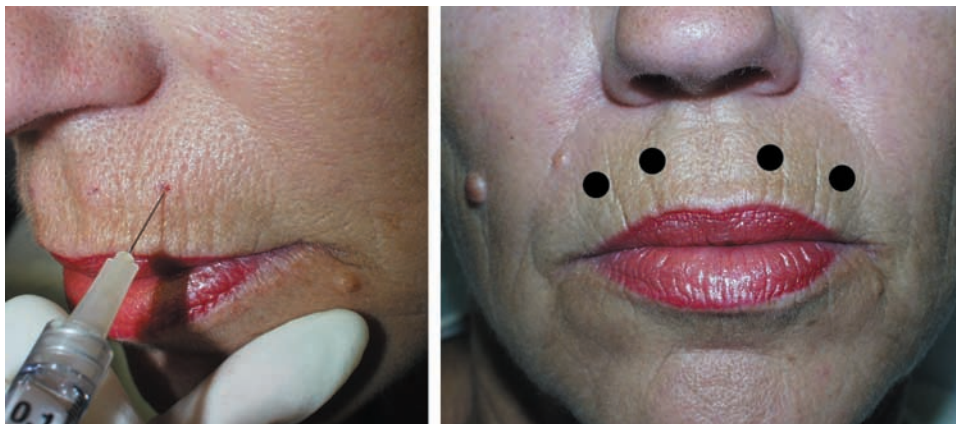- Paralysis at any dilution was usually apparent in 72 hours and persisted an average of 4 months.
- An average of 4 units of BTA was adequate for larger muscle groups, and 2 to 3 units was adequate for thinner or smaller muscles
- The same number of units are administered to a specific region regardless of dilution. Diluting Botox does not mean that the patient receives less.

## Discussion

### DILUTION

Carruthers and Carruthers<sup>6</sup> original studies consisted of a 1-mL dilution of unpreserved saline, and they still use this dilution.<sup>7</sup> The author has experimented with several dilutions and found no discernible difference in longevity based on observation or patient reporting. Regardless of the dilution, approximately 4 units of Botox was injected in the glabellar regions, whereas 2 to 3 units were injected in thinner muscular regions such as the frontalis and lateral canthal regions. With experience, more attention was paid to the size of the injected bleb than the actual syringe graduations.

A 1-mL dilution was used on 133 patients and had several disadvantages as experienced by the author. This small volume, via capillary action, leaves a coating on the bottle that prevents all of the reconstituted Botox from being drawn up in syringes. Even though 1 mL of unpreserved saline is added, less than 1 mL can be drawn up in syringes. Considering that Botox costs \$392 per milliliter (at the time of submission of this article) at this dilution, any waste is not cost effective. We used the previously described bottle opener to access the vial. The other disadvantage is that smaller quantities are injected at this dilution. An injection of 5 units requires 0.05 mL, which is sometimes difficult to read on the syringe while injecting. The author has found that by using B-D Ultrafine 2



**FIGURE 10.** Treatment for perioral rhytids involves injecting 1 to 2 units symmetrically across the upper lip. These injections are very superficial and just subcutaneous. The author generally performs only 2 injections and observes the treatment response before reinjecting.

syringes (Becton Dickinson & Co, Franklin, NJ), the increments that are injected are much easier to read and handle at this dilution.<sup>7</sup> This syringe holds 0.3 mL and has an attached ¼-inch 30-gauge needle.

For any dilution scheme that was used, paralysis was apparent in about 72 hours and lasted approximately 4 months by patient and physician observations.

We have experimented with higher dilutional regimens on several hundred patient treatments. We used 12 mL of unpreserved saline on 174 patient treatments. Although more diluent was used, each injection delivered the same dose of 2 to 4 units depending on muscle size and region treated. There was no significant observational differences in the length or effect of paralysis. One disadvantage of such a high dilution was that we observed slightly more injection pain as well as a larger postinjection bleb at each site.

Due to the increased pain and the fact that the larger blebs prevented patients from having Botox treatments over their lunch break from work, the dilution was decreased to a 6-mL dilution per vial of Botox. Six hundred nine patients treatments have so far been performed at this dilution with the same time of onset and longevity as the previous dilutions. The Botox vial will hold 6 mL of unpreserved saline, and we have found this to be a convenient method for injection. Six 1-mL syringes are then drawn up from the bottle. Each syringe contains 17 units, or 1.7 units/0.01 mL. The author injects a 4-mm-diameter bleb in the glabellar region, which equals approximately 3.4 units of Botox per injection. About 1.7 units is injected in smaller blebs in the frontalis and lateral canthal regions (Figs 2 and 3). Larger muscles require more Botox, regardless of the anatomic region. We currently use this regimen and have found rate of onset, longevity, and patient acceptance to be predictable.

In the discussion of dilution, it is important to point out that, ultimately, it is the actual number of Botox units that produce the effect. Regardless of the dilution, we have found that 3 to 4 units is required to treat larger muscles and 2 to 3 units is required for smaller or thinner muscles. The increased or decreased dilution only means that more or less diluent is injected per site to achieve the therapeutic effect. Dilution does not save money or make the Botox last longer. There are 100 units per vial regardless of how it is diluted. We simply find it more convenient to use a 6-mL dilution. This is important to clarify with patients because some individuals think that using a greater dilution equals less Botox. Again, 4 units is 4 units, regardless of the vehicle concentration. It is rumored that some practitioners dilute the vial and give less units, which obviously is a different scenario.

Across the board, it has been the author's experience that less BTA is required than the 5 units originally described.<sup>6,8</sup> Our experience indicates that 3 to 4 units will produce paralysis of approximately 1 cm in diameter. Again, large, hypertrophied, or active muscles may take more than 4 units to paralyze.

#### ANESTHESIA

In the author's experience, the average patient tolerates the minor discomfort of the BTA injections. Although most patients are apprehensive at the first treatment, they subsequently tolerate injections quite well. Topical anesthetics are frequently used by some practitioners. The author has used acid mantle cream mixed with lidocaine<sup>9</sup> (ELA-Max cream, lidocaine 4%; Ferndale Laboratories, Ferndale, MI) and Lidoderm patches (lidocaine 5%; Endo Labs, Chadds Ford, PA). Most patients treated with topical anesthesia elected not to use it on subsequent treatments.

#### INJECTION TECHNIQUE

Multiple injection techniques have been described in the international literature. Carruthers and Carruthers originally described a method based on brow position.<sup>6</sup> The author has described a method based on needle angulation and measurement.<sup>3,4</sup> After thousands of injections, it is thought that there are only 2 main situations that guide treatment outcomes. It is most important is to stay 10 mm away from the bony orbit. The apparent diffusion of BTA is approximately 1 cm. In the estimated 17,000 injections, only 1 case of ptosis was observed, and this was in a patient in whom the injection was close to the upper eyelid.

#### ALTERNATIVE COSMETIC FACIAL INJECTION SIGHTS

Although Botox has been approved by the Food and Drug Administration for the treatment of glabellar lines, other uses have shown the same degree of improvement for frontalis and lateral canthal regions. The use of Botox for the reduction of platysmal bands has been described as successful.<sup>10,11</sup> The author has attempted this on only 1 patient with minimal clinical results.

Flynn et al<sup>12</sup> described the use of Botox for the noninvasive reduction of lower eyelid orbicularis hypertrophy. One unit of Botox is placed in the center of the eyelid, just below the lash line.

The author has seen several patients from other offices who presented with the complaint of post-BTA treatment perioral muscular palsy. These patients were injected for the treatment of vertical lip rhytids (lipstick lines). It is unknown what regions were injected or how many units were injected. The patients presented with asymmetric movement of the orbicularis oris muscle (as seen in a Bell's palsy), and 1 patient lost the ability to pucker. Because of these

complications, the author has not commonly injected this region. After personal communication (A. Carruthers, J. Carruthers, personal communication, July 2001), this region is being conservatively treated without negative clinical results to date. A small series of patients were injected in the upper perioral region for lip rhytids. The technique involves 4 subcutaneous injections of 1 unit of Botox symmetrically across the upper lip for microparesis or weakening as opposed to paralysis (Fig 10). Due to the obvious problems from possible lip incompetence, extreme caution must be kept in mind. Using a 0.3-mL insulin syringe assists microdosing for accuracy. Minimal vertical lip rhytid improvement has been seen by the treating physician with this small series, but all patients reported improvement and satisfaction. Treatment of this region should not be performed by inexperienced practitioners.

Due to the possibility of perioral muscle incompetence, it is imperative not to inject any patient who may need absolute oral function for their profession or vocation, such as scuba divers, trumpet players, or singers.

Carruthers<sup>1</sup> also describes improvement of patients with excessive gingival exposure. By weakening the lip elevators, the amount of movement is decreased and the patient reportedly shows less gingiva.

#### HEADACHE AND TMD TREATMENT

Of the 1,085 patient treatments in our office, we had multiple reports of chronic headache improvement. This has been observed by others who use BTA regularly in the facial regions. Binder et al<sup>13,14</sup> reported that 79% of migraine patients experienced complete or partial improvement at 6-week follow-up. The author to date has treated 48 patients specifically for headache pain or facial pain. These patients were not classified by type of headache, but all 48 patients reported some improvement in severity and frequency of their headaches.

Patients with TMDs frequently report regions of muscular sensitivity in the temporalis and masseteric regions. The author has injected these patients in the tender regions with 2 to 5 units of BTA but cannot comment on its effectiveness as improvement is multifactorial.

#### CONCERNS AND CONTRAINDICATIONS

Because human albumin is used in the preparation of Botox, a patient could exhibit an allergic reaction. Although the author asks all patients if they are allergic to serum or egg whites, we have yet, to our

knowledge, to see an allergic reaction to Botox. In addition, concerns have been raised about the possibility of viral infection or prion infection such as in spongiform bovine encephalopathy. Commercially available human serum albumin comes from screened donors. Because the albumin is pasteurized during the manufacturing process, viral transmission should be theoretically nil. No case of prion transmission in humans through blood or blood donors has ever been identified.<sup>15</sup>

Allergan lists Botox contraindications as pregnancy and breastfeeding, disorders of the neuromuscular junction (myasthenia gravis, amyotrophic lateralizing sclerosis, myopathies), and theoretical drug interactions (aminoglycoside antibiotics and calcium channel blockers).<sup>5</sup> In our series, we received no complaints about systemic problems associated with cosmetic injection.

#### References

1. Carruthers A: Facial aesthetic enhancement educational initiative. Chicago, IL, Faculty Training, July 13-15, 2001
2. DasGupta BR, Sugiyama H: A common subunit structure in Clostridium botulinum type A, B and E toxins. *Biochem Biophys Res Commun* 48:108, 1972
3. Niamtu J: Aesthetic uses of botulinum toxin A. *J Oral Maxillofac Surg* 57:1228, 1999
4. Niamtu J: Cosmetic facial surgery. *Oral Maxillofac Surg Clin North Am* 12:595, 2000
5. Botox package insert. Irvine, CA, Allergan, Inc
6. Carruthers J, Carruthers A: Treatment of glabellar frown lines with C. botulinum-A exotoxin. *J Dermatol Surg Oncol* 18:17, 1992
7. Flynn TC, Carruthers A, Carruthers J: Surgical Pearl: The use of the Ultra-Fine II short needle 0.3-cc insulin syringe for botulinum toxin injections. *J Am Acad Dermatol* 46:931, 2002
8. Hankins CL, Strimling R, Rogers GS: Botulinum A toxin for glabellar wrinkles. Dose and response. *Dermatol Surg* 24:1181, 1998.
9. Niamtu J, Campbell RL: The anesthetic skin patch for topical cutaneous anesthesia. *J Oral Maxillofac Surg* 42:839, 1984
10. Matarasso A, Matarasso SL, Brandt FS, et al: Botulinum A exotoxin for the management of platysma bands. *Plast Reconstr Surg* 103:645, 1999
11. Kane MA: Platysmal band treatment with botulinum toxin A. *Plast Reconstr Surg* 103:656, 1999
12. Flynn TC, Carruthers J, Carruthers A: Botulinum-A toxin treatment of the lower eyelid improves infraorbital rhytides and widens the eye. *Dermatol Surg* 27:703, 2001
13. Binder W, Brin MF, Blitzer A, et al: Botulinum toxin type A (BTX-A) for migraine: An open label assessment. *Mov Disord* 13:241, 1998 (suppl 2)
14. Binder WJ, Brin MF, Blitzer A, et al: Botulinum toxin type A (Botox) for treatment of migraine headaches: An open-label study. *Otolaryngol Head Neck Surg* 123:669, 2000
15. Brown P, Cervenakova L, McShane LM, et al: Further studies of blood infectivity in an experimental model of transmissible spongiform encephalopathy, with an explanation of why blood components do not transmit Creutzfeldt-Jakob disease in humans. *Transfusion* 39:1169, 1999