

The Use of Restylane in Cosmetic Facial Surgery

Joseph Niamtu, III, DMD*

The injection of filler substances is one of the most common procedures in cosmetic surgery. In 2003, the number of nonsurgical procedures increased 22% from 2002.¹ The last 5 years have brought about an extreme interest in minimally invasive rejuvenation techniques. The ease and popularity of Botox (Allergan Inc, Irvine, CA) has popularized and expanded the use of rejuvenative injections.²⁻⁴ This, coupled with the introduction of multiple new products, has increased the number of treatment options for cosmetic patients. Multiple substances are available to inject into facial wrinkles, folds, lips, traumatic defects, and depressed scars, and to augment facial form (Table 1).

Over the last century some substances, such as paraffin and silicone, have been used with associated problems.^{5,6} For over 2 decades the gold standard for injectable facial fillers in the United States has been bovine-derived collagen (Zyplast; Inamed Inc, Santa Barbara, CA). This product was available in several viscosities (particle sizes) to use in different indications from fine lines and wrinkles to lip plumping.

Various advantages and disadvantages exist with all filler substances. One of the biggest disadvantages has been the need for allergy testing with the non-human preparations. In addition to the possible allergic reaction, cosmetic patients are very impulsive consumers and having to wait a month for an allergy test before treatment is a huge drawback. Many of the newer products are non-animal and do not require allergy testing.

Another problematic situation that can present is the use of "permanent fillers" (products such as silicone liquid or those containing methylmethacrylate spheres that are not resorbed by the body). In this case, a permanent filler can cause permanent compli-

cations. Although a permanent filler may look fine at the time of injection, migration with aging or misinjection can be very problematic.

The biggest problem with previous fillers has been longevity. The search for a filler that does not require allergy testing and that would last longer than the collagen-based products has brought about the development of hyaluronic acid-based substances.

Restylane (Medicis Inc, Scottsdale, AZ) is a new filler approved in December 2003 by the US Food and Drug Administration (FDA) for use in the lips. This product has been used very successfully for a decade in Europe, Canada, and Australia.⁷⁻¹³ It is a NASHA (non-animal stabilized hyaluronic acid) preparation synthesized from bacterial cultures and is packaged as a clear gel in 1.0-cc syringes with an accompanying 27-gauge needle (Fig 1). Restylane is terminally sterilized to prevent bacterial transmission.

Hyaluronic acid is a naturally occurring substance found in the skin, eye, and joints. Unstabilized forms of hyaluronic acid are not lasting when used as intradermal fillers and are rapidly resorbed. Manufacturers use a proprietary process known as cross-linking to stabilize the hyaluronic acid to increase its longevity. Hyaluronic acid is thought to be nonimmunogenic, but trace amounts of bacterial protein from product synthesis can cause inflammatory or granulomatous reactions. Restylane has a low allergic response of 1 in 26,000⁸ (data on file, Q Med Inc, Uppsalla, Sweden) compared with bovine collagen, which has a much higher allergic response of 3 in 100.¹⁴ Several studies have shown significant inflammatory reactions to hyaluronic acid fillers, but these appear to be extremely isolated incidents.¹⁵⁻¹⁷ Multiple studies have shown that Restylane can last longer than Zyplast when injected in vivo.^{12,13} The non-animal composition, low allergic response, and increased longevity of Restylane have made it an extremely popular product. Because all resorbable fillers are phagocytized by the body, the cosmetic effects are transient. One reason that the hyaluronic acid lasts longer than previous fillers is that it is a hydrophilic molecule. Normally, biodegradable implants shrink gradually upon degradation, but Restylane has the unique property of maintaining the initial volume throughout the degra-

*Private Practice, Oral and Maxillofacial and Cosmetic Facial Surgery, Richmond, VA.

Address correspondence and reprint requests to Dr Niamtu: 10230 Cherokee Road, Richmond, VA 23235; e-mail: niamtu@niamtu.com

© 2006 American Association of Oral and Maxillofacial Surgeons
0278-2391/06/6402-0024\$32.00/0
doi:10.1016/j.joms.2005.10.019

Table 1. SOME OF THE NEWER FILLER SUBSTANCES CURRENTLY IN USE AROUND THE WORLD

Product	Source	Manufacturer
Restylane	Non-human hyaluronic acid	Medicis Inc, Scottsdale, AZ
Restylane Fine Line	Non-human hyaluronic acid	Medicis Inc
Perlane	Non-human hyaluronic acid	Medicis Inc
Cosmoplast	Human-derived collagen	Inamed Inc, Santa Barbara, CA
Cosmoderm	Human-derived collagen	Inamed Inc
Radiesse	Hydroxyappetite	BioForm Medical Inc, San Mateo, CA
Hyalform	Hyaluronic acid	Inamed Inc
Artecol	PMMA beads in hyaluronic acid	Artes Medical Inc, San Diego, CA
Artefil	PMMA beads in bovine collagen	Artes Medical Inc
Silikon	Liquid injectable silicone	Alcon Labs Inc, Ft. Worth TX
Sculptra	Polylactic acid	Aventis Pharm Inc, Bridgewater, NJ
Isolagen	Cultured autologous fibroblasts	Isolagen Inc, Huston, TX
Autologen	Autologous collagen	Collagenesis Inc, Beverly, MA

Joseph Niamtu. Restylane in Cosmetic Facial Surgery. J Oral Maxillofac Surg 2006.

dation phase. This is termed “isovolemic degradation.” As the hyaluronic acid is degraded, water takes its place. The less concentrated the gel becomes, the more water each molecule is able to bind. The result is that the same volume can be maintained with less implant material.¹⁸ Finally, the implant is fully degraded and reabsorbed, leaving the tissue without any fibrosis or implant waste.

The hyaluronic acid products distributed by Medicis Inc are all NASHA-based, contain 20 mg/mL of hyaluronic acid, have a pH of 7.0, and differ only by particle size. Restylane Fine Line contains 200,000 gel particles per mL and is intended for fine lines and wrinkles to be injected in the superficial dermis. Restylane contains 100,000 gel particles per mL and is indicated for injection in the middle dermis. Perlane contains 10,000 gel particles per mL and is intended for injection in the deep dermis or subcutis. The larger the particle the deeper it is injected and the longer it will last. To obtain optimum clinical results and longevity it is imperative to inject the correct particle size product in the correct tissue plane. At

the time of submission of this publication only Restylane had FDA approval and discussion will be limited to this product.

Cosmetic Indications for Restylane

Like most fillers, Restylane is primarily used for the treatment of facial lines, wrinkles, folds, and lip enhancement. Unlike some fillers, Restylane has no inherent local anesthesia or local anesthetic properties, and for that reason facial nerve blocks are recommended before injection. This is especially true in the lips, where filler injection can be very uncomfortable. Restylane can usually be injected in facial areas such as nasolabial folds with only topical anesthetic, but local anesthetic blocks or infiltrations are necessary when treating the lips. A useful anesthetic preparation for topical cutaneous anesthesia is a compound of benzocaine, lidocaine, and tetracaine in a gel base (BBPharmacy.com) which is applied to the skin 15 minutes before injecting.

Patients are also advised when they schedule their appointment to refrain from aspirin or other medications 2 weeks before treatment because it may affect coagulation and therefore increase bruising.

Injection Technique: Lips

Esthetic lips are a result of a pleasing combination of volume, anatomic definition, pout, and symmetry. The basic outline of an esthetic upper lip is the shape of an “M” and the lower lip is curvilinear or parabolic. The upper lip contains one third of the total lip volume and the lower lip adds two thirds of the volume of the lips (Fig 2).

A well defined Cupid’s Bow, white roll, philtral columns, and commissures contribute to the esthetic lip and are targets of injectable fillers (Fig 3).

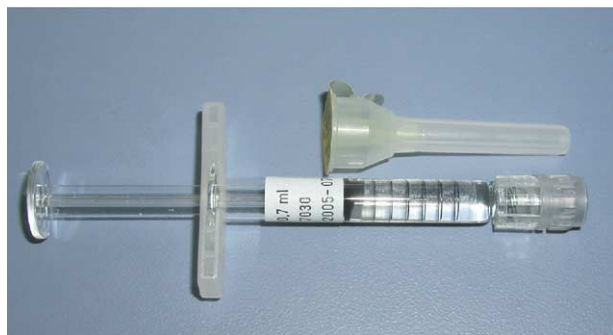

FIGURE 1. Restylane is an injectable hyaluronic acid packaged as a clear gel in 1.0-cc syringes and comes with a 27-gauge needle.

Joseph Niamtu. Restylane in Cosmetic Facial Surgery. J Oral Maxillofac Surg 2006.

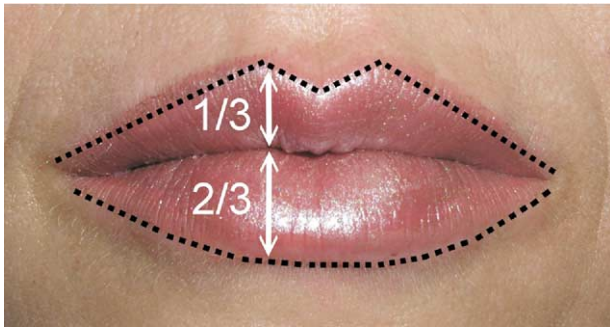


FIGURE 2. Illustration of the anatomic outlines and relative size components of an esthetic adult female lip.

Joseph Niamtu. Restylane in Cosmetic Facial Surgery. J Oral Maxillofac Surg 2006.

Most younger female patients present for lip augmentation to either increase volume, pout, or definition. Older patients desire similar improvement and the treatment of vertical lip rhytids (lipstick lines). Vertical lip lines are a significant problem in older females, especially smokers. Not only are they unesthetic, but applied lipstick will run into the lines producing fine, colored vertical lines running from the lip.

Other common areas of requested treatment include nasolabial folds, glabellar lines, and periorbital and generalized facial rhytids. In reality, any skin wrinkle may be treated.

The media frequently hypes new fillers as a treatment for generalized facial rhytids or a replacement for Botox. Some patients present with the request to treat hundreds of facial wrinkles and think that filler injection is a global treatment. Although this could be performed, it would generally not be cost effective or long lasting for the average patient. These patients must be informed that rhytidectomy or laser resurfacing would be a more appropriate wrinkle treatment; in addition, they should understand the difference between a filler and a neurotoxin treatment such as Botox.² Although these 2 products have distinctly different treatment actions, it has been shown that the concomitant use of fillers and Botox enhance the longevity of the filler and complement the total esthetic result.¹⁹

Preinjection Considerations

Clinical photographs are taken on all patients.²⁰ Frequently, patients will not recall their actual preinjection anatomy and may later complain about what they perceive as poor treatment results which may truly be related to their specific pre-existing anatomic situation. In addition, pre- and postinjection photographs will allow both the surgeon and patient to judge the success of augmentation. These images can

also be used to show other prospective patients anticipated results and for general cosmetic marketing purposes. It is also prudent to query the patient on their expectations of the augmentation. Some patients may have unrealistic expectations and showing them average before and after photographs can serve to close the gap between patient perception and reality. Another caveat is to explain that a single syringe only contains 1.0 cc of filler and for most patients several syringes may be required. Multiple syringes are usually required to treat older patients or younger patients with deep creases or hypoplastic lips. A single syringe is frequently adequate to augment the upper lip and the central portion of the lower lip. A single syringe will also serve to blunt the average nasolabial fold bilaterally. In patients with deeper nasolabial folds it is not uncommon to use a syringe or more on each side. It may also take several syringes to augment both lips. For this reason, an estimate of the number of syringes required should be discussed before injection or the patient may be put off when they are told in the middle of the procedure that more filler is required. This problem is mitigated by insisting on a 2-week follow-up appointment to assess the anticipated augmentation and re-treat if desired. Finally, if a patient only desires a single sy-

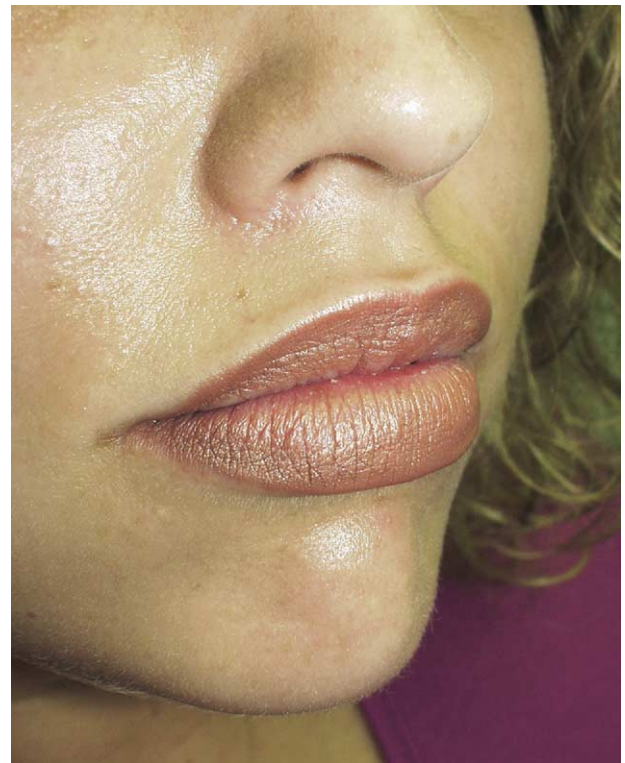


FIGURE 3. Well-defined anatomic units contribute to optimum lip esthetics.

Joseph Niamtu. Restylane in Cosmetic Facial Surgery. J Oral Maxillofac Surg 2006.

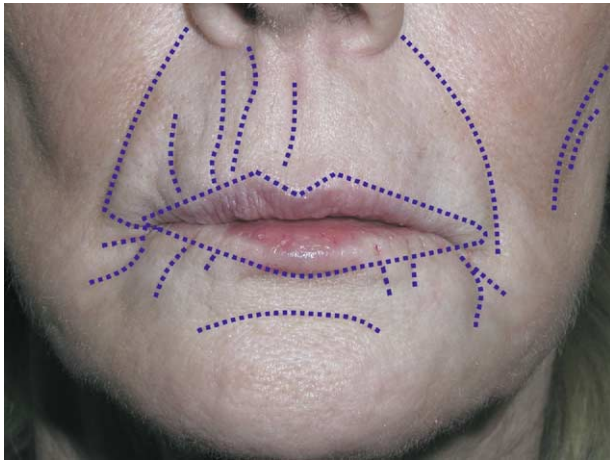


FIGURE 4. Marking the intended areas of augmentation will assist with the accuracy of the filler substance.

Joseph Niamtu. Restylane in Cosmetic Facial Surgery. J Oral Maxillofac Surg 2006.

ringe of filler the doctor and assistant must keep a close eye on the remaining material in the syringe to ensure that enough filler is left for the other nasolabial fold or the other lip.

It is also prudent to ask all potential lip augmentation patients about recurring herpes labialis infection, especially those patients in which perioral trauma triggers outbreak. In this population the author suggests prophylaxis for these patients with valacyclovir 500 mg every 12 hours beginning 48 hours before injection and continuing for 3 days postinjection.

Patients presenting for filler injection are asked if they are taking any medications such as aspirin compounds or certain herbs that may affect coagulation. Although the intradermal injection of fillers is not contraindicated in these patients, they certainly may experience increased incidence of bruising or swelling and should be forewarned. In addition, there are other distinct differences between Restylane and previous bovine collagen fillers. Those doctors with prior experience using bovine collagen fillers generally over-corrected lips and wrinkles beyond the desired clinical result. This was in part because these products contained lidocaine and an initial resorption of the clinical augmentation would result in the first several days. Restylane does not contain any inherent local anesthesia and does not need to be overcorrected to achieve clinical result. Again, it is important for the doctor and patient to realize this difference to avoid overcorrection. Additionally, there is a more pronounced initial inflammatory response with Restylane than bovine collagen fillers. It must be explained to patients that they will likely experience somewhat more redness and swelling with Restylane than they did with bovine collagen fillers. This swelling and erythema also appear more rapidly with Restylane

and can skew the apparent amount of augmentation delivered. For this reason it is absolutely critical to remain conservative to avoid overcorrection. Under correcting a patient is never a problem because more filler can always be added. Significant overcorrection, on the other hand, can be quite problematic because the patient may be disfigured for the greater part of a year. As new fillers increase clinical longevity, this process becomes more significant. Ice is applied to the tissues to be injected before and after augmentation and allows patients to apply makeup as soon as any pinpoint puncture bleeding stops. Additionally, all patients are told to expect 24 to 48 hours of swelling and erythema in the injected areas. It is rare that a patient would not be able to return to work the next day because of swelling or inflammation. Due to the aforementioned increase in erythema and swelling, the author feels strongly about not attempting to treat most patients in a single injection session. Patients are told that Restylane augmentation is a sculpting process and that it may require several appointments. Reappointment at 1 to 2 weeks allows the surgeon not only to assess the level of augmentation, but to add more filler if necessary to correct underfill or asymmetry.

Marking the areas to be injected with a surgical marking pen is highly recommended and will enable a more accurate augmentation (Fig 4). This is especially true for the novice injector because landmarks may change during the injection procedure from such factors as swelling and patient position.

An additional critical factor is to inject the patient in the upright position (Fig 5). If the patient is in the recumbent position, gravitational forces will distort the nasolabial folds and lips, potentially affecting accuracy.

As stated earlier in this article, erring on the conservative side is a commandment of fillers. A summary of pertinent injection reminders is listed in Table 2.

Restylane Injection Technique

Two main techniques exist for filler injection (Fig 6). Serial puncture is a technique that involves placing

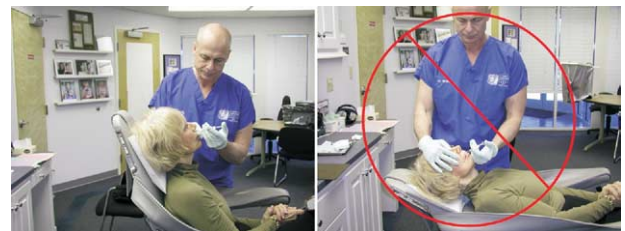

FIGURE 5. Fillers should be injected with the patient in the upright position to prevent gravitational anatomic distortion.

Joseph Niamtu. Restylane in Cosmetic Facial Surgery. J Oral Maxillofac Surg 2006.

Table 2. PEARLS TO REMEMBER WHEN INJECTING FILLERS

- Assess patient outcome expectations prior to injection.
- Take preinjection pictures on all patients.
- Explain the possible need for multiple syringes before injecting.
- Explain expected recovery in advance of injection.
- Schedule the augmentation as a two appointment procedure to assess results and correct problems.
- Be conservative as more filler can be added but excess cannot be removed.
- Mark all areas of augmentation before injecting.
- Utilize appropriate pain control.
- Always inject in the upright position.
- Remember to conserve 1/2 of the syringe for the other side or other lip when injecting bilaterally
- Ice the treated areas before and after injecting.

Joseph Niamtu. *Restylane in Cosmetic Facial Surgery. J Oral Maxillofac Surg* 2006.

a small bolus of filler in a single area and repeating this progressively along the area to be augmented. The other technique is linear threading, which is a technique where the needle is inserted parallel to the long axis of the lip or wrinkle and inserted to the needle hub. The filler is injected as the needle is removed, which forms a liner ridge as opposed to a bolus of filler. The filler may also be injected while advancing the needle as well. Both techniques are valid and useful in various applications. They are frequently combined and are the preference of the injector.

Cosmetic lip injection is performed after makeup is removed, the lips anesthetized, and the area is prepped with an alcohol wipe. Each patient exhibits different anatomy and treatment expectations. Injection is begun in the upper lip to enhance or reform

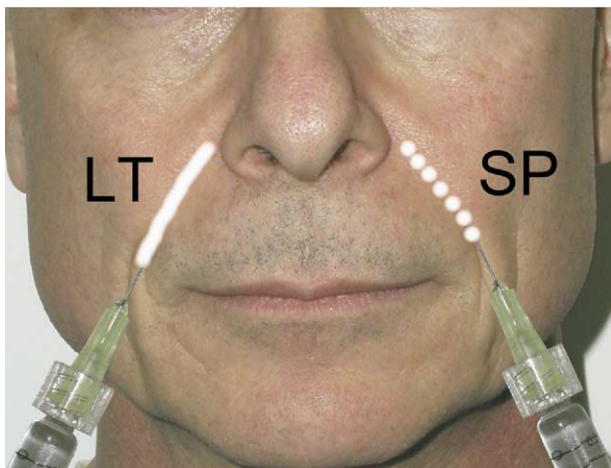


FIGURE 6. Linear threading (LT) and serial puncture (SP) techniques are most commonly used in filler injection.

Joseph Niamtu. *Restylane in Cosmetic Facial Surgery. J Oral Maxillofac Surg* 2006.

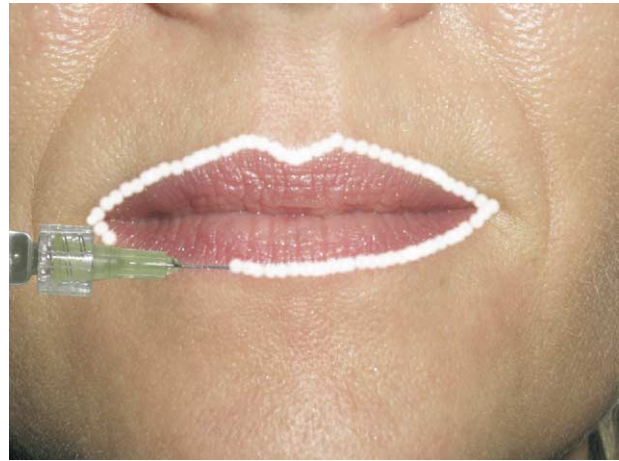


FIGURE 7. Augmentation of the “M” configuration of the “Cupid’s Bow” in the upper lip and the “white roll” area of both lips.

Joseph Niamtu. *Restylane in Cosmetic Facial Surgery. J Oral Maxillofac Surg* 2006.

the “M” configuration, which creates a defined “white roll” and accents the “Cupid’s Bow” (Fig 7). The proper plane of injection for this area is at the vermilion cutaneous junction in the potential space just below the skin or mucosa. In the proper plane, the filler should flow freely without excessive syringe pressure in both an antegrade and retrograde direction. The needle is inserted in the potential space parallel to the lip and the Restylane is injected while the needle is withdrawn (Fig 7).

If significant syringe pressure is required or if the filler does not flow forward, then the needle is in the incorrect plane and must be redirected. Injection in the incorrect plane will cause a clump of filler as opposed to a flowing ridge (Fig 8).

Keeping the lip stretched will also assist the flowing of the filler. A perimeter of filler is placed on the borders of both lips to define the “white roll.” Depending on the amount of aging and the patient’s desires, the filler can be carried all the way to the commissure area. Some lips look esthetic with only the central two thirds augmented, while other pa-

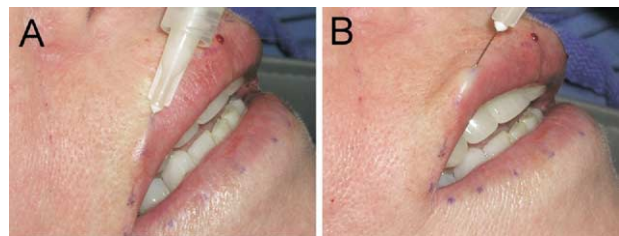


FIGURE 8. A shows a flowing ridge of filler when injected in the correct plane; B shows clumping of filler from injecting in an improper plane.

Joseph Niamtu. *Restylane in Cosmetic Facial Surgery. J Oral Maxillofac Surg* 2006.

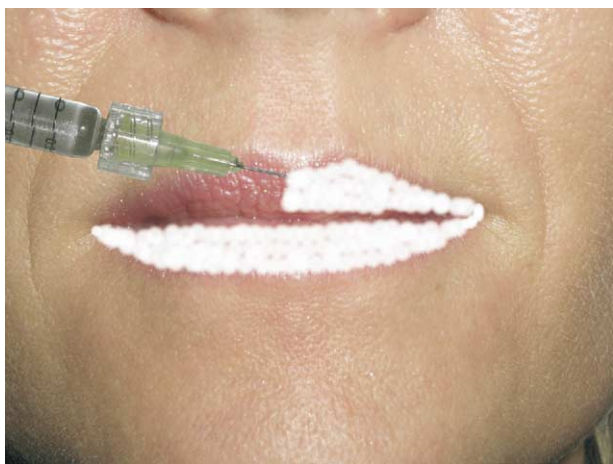


FIGURE 9. For volumetric vermilion augmentation, deeper submucosal injection is performed.

Joseph Niamtu. Restylane in Cosmetic Facial Surgery. J Oral Maxillofac Surg 2006.

tients appreciate augmentation all the way to the commissure, especially in the senescent lip where the corners turn downward. There exists some artistry in this aspect, and asking the patient what they want or asking them to bring a picture can give the surgeon a “blueprint” for treatment, assuming the request is realistic. After outlining the Cupid’s Bow area, the surgeon may choose to inject the vermilion substance of the lip. Augmenting the “white roll” area is all that is required for some patients, while others desire more volumetric vermilion augmentation. This can be performed in the deep and superficial plane. In the superficial plane the filler is injected in the submucosal plane several millimeters inferior to the vermilion cutaneous area. It is important to stay superficial in this area to ensure optimum planar flow and to avoid hematoma (Fig 9). Again, the potential space beneath the mucosa is the correct plane.

To inject in the deep substance of the lip, the needle is injected midway into the lip and aspiration is used to prevent both intravascular injection and hematoma formation. The labial artery traverses the posterior third of the lip at the level of the lower central incisor edge and also corresponds with the level of the vermilion cutaneous junction and is rarely encountered with filler injection. Many patients do not need deep tissue injection as Restylane augmentation of the “white roll” area and or vermilion area is sufficient.

Older patients frequently have rhytids in the corners of the mouth from overclosure, resulting from reduced vertical dimension. Restylane is injected in this area in a radiating pattern to plump this area. Finally, if significant vertical rhytids still exist, these are treated with a very superficial intradermal injection parallel to the long axis of the wrinkle (Fig 10).

To further define or accent esthetic lip anatomy, augmentation of the philtral columns may be performed. The philtral columns are shaped like a megaphone where the apex is subalar and the base is at the vermilion cutaneous junction. To augment this area, the skin is pinched between the thumb and index finger of the noninjecting hand. This defines the area to be injected and assists in containing the flowing filler to this area. This area is injected in the deep dermal layer.

Injecting the Nasolabial Folds

Second to the lips, the nasolabial folds are the most requested area to be augmented in the author’s practice. Many patients do not understand that these folds cannot be eliminated. It is explained to them that an adult would look unnatural without any nasolabial folds; the goal is to blunt these folds. As previously mentioned, an upright injecting position is preferred as gravitational effect will distort the true nasolabial anatomy when the patient is reclined or supine. The correct tissue plane for Restylane injection in the nasolabial fold is intradermal. Because the skin is

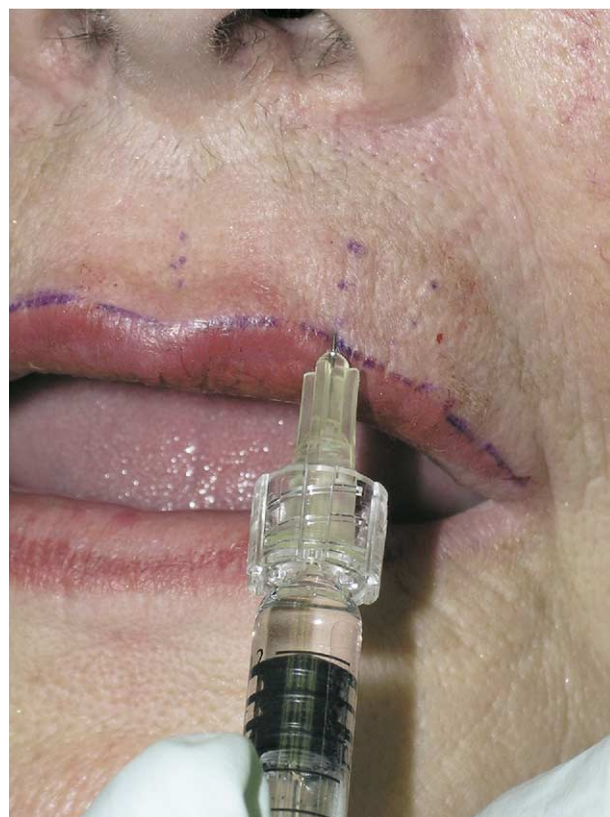

FIGURE 10. Illustration of plumping of the vertical lip rhytids with Restylane.

Joseph Niamtu. Restylane in Cosmetic Facial Surgery. J Oral Maxillofac Surg 2006.

relatively thick in this area, the needle is placed just deep enough in the skin so that the injection produces augmentation without visibly producing lumps that are lighter in color than the skin; this indicates too superficial of an injection plane. This is especially true when injecting pigmented skin with light colored fillers.

A caveat is to not make the nasolabial fold bigger. Because multiple tissue planes come together at the nasolabial area, any injected substance can easily follow the natural tissue plane laterally instead of remaining at the depth of the fold. It is especially easy to have filler flow lateral to the nasolabial fold. If this happens, it actually increases the lateral margin of the fold and makes the valley deeper, thereby worsening the appearance of the fold. This is not an uncommon mistake with the novice injector. To prevent this, the injector must pay close attention to where the filler is flowing and most importantly err on the medial side of the nasolabial fold. Liner threading and serial puncture are frequently used in combination to fill in this area (Fig 6). Using the serial puncture technique and aiming just medial to the valley of the fold is a predictable manner of injecting this area. When using the serial puncture technique, the surgeon is laying down small boluses of filler and the area may appear bumpy. By placing the thumb inside the mouth and the index finger on the skin, these bumps may be smoothed by compression and massage. The actual injection technique is less important. It is the final result of a blunted or less noticeable nasolabial fold that is the desired endpoint. It generally takes an entire syringe to bilaterally blunt shallow nasolabial folds and multiple syringes to bilaterally blunt deeper folds.

Injecting Facial Rhytids

Extreme care must be used when injecting any substances in the periorbital areas because permanent blindness has been described with collagen and fat from intravascular injection and retinal artery occlusion.²¹⁻²³ Any injection in these areas must be extremely superficial and intradermal.

The linear threading technique works well with these superficial rhytids. The rhytid is first marked with a surgical marker and the skin is stretched. The needle is inserted in the mid or superficial dermis and the filler is injected directly in the valley of the rhytid while withdrawing the needle. The area is then massaged to smooth any lumpy areas.

Deep glabellar or lateral canthal lines are best treated with a combination of Botox and Restylane and can truly create a synergistic result that will enhance the longevity of the filler because of the decrease in local muscle movement.¹⁹ In addition, the combination of Botox and Restylane provides an im-

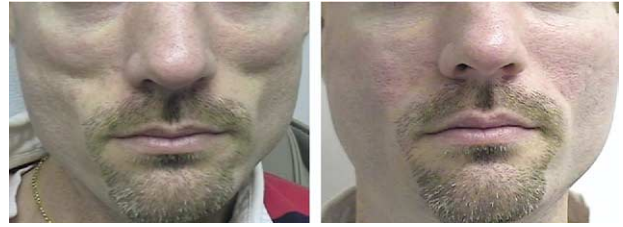

FIGURE 11. Before and after injection of facial atrophy secondary to HIV antiviral medication.

Joseph Niamtu. Restylane in Cosmetic Facial Surgery. J Oral Maxillofac Surg 2006.

provement that is superior to what each technique could provide by itself.

When injecting very superficial cheek or lip wrinkles it is imperative not to overcorrect, as the patient will go from a noticeable wrinkle to a noticeable ridge. Again, being conservative and having the patient follow up in 2 weeks for possible re-treatment can prevent overtreatment misadventures. At the time of submission of this article only Restylane has FDA approval in the United States. A similar product called Restylane Fine Line (Medicis Inc) has smaller size particles and is specifically designed for fine lines. This is analogous to Zyderm (Inamed Inc) being indicated for superficial injection as compared with Zylplast (Inamed Inc). When injecting lips and folds some practitioners will layer the augmentation. Restylane or Perlane is injected deeper and Restylane Fine Line is injected more superficially.

Augmenting Facial Anatomy

Restylane may also be used to enhance existing anatomy. Perlane is actually better indicated for this because of its larger particle size, but is not FDA approved in the United States at the time of submission of this article. The author has augmented the malar areas, chin, and the lateral eyebrows by injecting Restylane over the prominence of the area to be augmented. It has been noted that only small amounts of Restylane are required to produce a visible augmentation over a prominent area.

Another indication for facial augmentation is HIV patients that have severe facial atrophy from lipodystrophy from antiretroviral therapy.²⁴ The antiretroviral medications cause extreme hollowing of the cheeks, temples, and zygomatic areas, calling attention to the tell-tale stigmata of this disease. Restylane has been successfully used to treat antiretroviral lipodystrophy. It may take 5 to 10 syringes to augment severe facial atrophy. Figure 11 shows a before and after photograph of an HIV patient with lipodystrophy from antiretroviral medications.

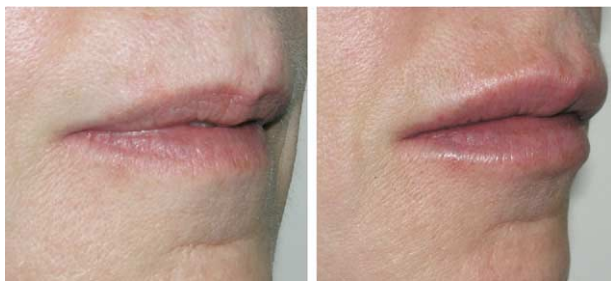

FIGURE 12. Before and after injection of a single syringe of Restylane divided between both lips.

Joseph Niamtu. Restylane in Cosmetic Facial Surgery. J Oral Maxillofac Surg 2006.

Postinjection Protocol

After injecting any area, bimanual massage is used to smooth any lumps or irregularities. This is done by placing the thumb intraorally and the index finger on the skin and massaging and stretching the lips or nasolabial fold to compress the injection sites. For areas remote to the mouth, a finger compresses the injected area against the hard tissue. The injected areas are iced immediately after injection and the patient is encouraged to continue this for several hours. The patient is forewarned to expect erythema and swelling for 24 to 48 hours. The patient is given a follow-up appointment at 1 to 2 weeks and advised in advance that further treatment may be required at the follow-up appointment if asymmetry exists.

Figures 12 and 13 show before and after photographs of Restylane lip enhancement. Figure 11 shows a pre- and post-treatment photograph of an HIV patient augmented with Restylane for facial fat atrophy from antiretroviral medical therapy.

Complications

Asymmetry, overcorrection, and under correction are the most common complaints and generally improve with the experience of the injector. Because the facial tissues (especially the lips) may begin to swell during the injection it is sometimes difficult to judge what is edema and what is filler. For this reason, the patient and doctor may not have an accurate perception of the final result. As the degree of intra injection swelling differs from patient to patient, it is best to remain conservative with injection and have the patient return for follow-up at 1 to 2 weeks. At the follow-up appointment undercorrection or asymmetry may be addressed with reinjection. One caveat is to have an understanding before this appointment as to who will be responsible for the cost of the filler and what that cost will be. Some patients will feel that they should have had a larger augmentation for their investment or that the product should have “worked

better” and want more filler free of charge. Other patients may feel that the fillers did not address the original problem they presented with. This after the fact discourse can be uncomfortable and awkward for the patient and the doctor’s office. It is best avoided by having a sound preinjection informed consent, as well as taking time to provide a realistic expectation of treatment outcome to the patient. Showing the prospective patient actual pre- and postinjection pictures can improve expectations and decrease patient unhappiness. It is best to show a full range of results from average to best, and is important to show pictures of older patients as well. Showing only the best treatment results can lead to disappointed patients.

As the science of tissue fillers advances, prolonged clinical effects are being seen. The increased duration of the augmentation is generally looked upon as positive by the doctor and patient. If an area is over corrected, however, the product longevity can become a liability. The longer lasting the filler, the longer lasting the potential complication and this should be kept in mind. The best weapon against over augmentation is to be conservative and make filler augmentation a multi appointment procedure. This is imperative for the novice injector.

Inflammatory and granulomatous reaction can result from product allergy as detailed earlier in this article. Tissue necrosis can result from intravascular injection with blockage of blood flow or with extremely superficial tissue injection causing localized vascular congestion.²⁵ Close attention to proper tissue injection planes and syringe pressure can prevent vascular occlusion problems.

Hematoma and bruising are relatively common problems with filler injection and usually pose no significant problems. Even the most experienced injectors will, from time to time, cause bruising or hematoma from unrecognized vasculature. This must be explained to the patient in the preinjection informed consent. Immediate bruising, hematoma, or swelling is treated with ice and elevation. It is ex-

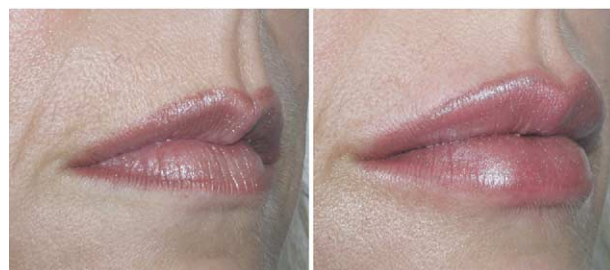

FIGURE 13. Before and after injection of 2 syringes of Restylane divided between both lips.

Joseph Niamtu. Restylane in Cosmetic Facial Surgery. J Oral Maxillofac Surg 2006.

plained to the patient that 24 to 48 hours may be required before they are socially presentable. In rare cases patients may experience extended swelling that can last up to a week. These patients are treated with a dose of tapering steroids in addition to the aforementioned therapies. As mentioned earlier in this article, medications that affect coagulation can increase the incidence of bruising and, like all surgeries, patients should be screened and informed of this.

Cosmetic surgery has become very popular in our society and technologic advances and patients' desires are making minimally invasive cosmetic procedures more popular than ever. The injection of facial fillers is a commonly requested and performed procedure for cosmetic facial surgery. Technologic advances have increased the longevity and decreased the allergenicity of facial fillers, making them more predictable and safer for the patient.

Restylane is a filler new to this country that can be used in the practice of cosmetic facial surgery to augment lips and improve facial rhytids and folds. Restylane has notable advantages over previous animal-derived fillers. Because Restylane is a non animal product, preinjection allergy testing is not required and the incidence of allergic reaction is greatly reduced. In addition, Restylane lasts longer than the bovine collagen products. This product has been used safely and effectively in other countries for a decade. The author has injected over 450 syringes in the 24 months since FDA approval and submission of this article. A high degree of patient and doctor satisfaction was observed and no significant complications occurred or were reported.

References

1. American Society for Aesthetic Plastic Surgery. Available at: <http://www.surgery.org/press/statistics-2003.php>. Accessed March 28, 2004
2. Niamtu J: Botulinum Toxin A: A review of 1,085 oral and maxillofacial patient treatments. *J Oral Maxillofac Surg* 61:317, 2003
3. Niamtu J: The use of botulinum toxin in cosmetic facial surgery. *Oral Maxillofac Surg Clin North Am* 12:596, 2000
4. Niamtu J: Aesthetic uses of botulinum toxin A. *Oral Maxillofac Surg* 57:1228, 1999
5. Klein AW: Paraffinomas of the scalp. *Arch Dermatol* 121:382, 1985
6. Palkhivala A: Injected silicone risks. *Dermatology Times*, June 2003, p 69
7. Olenius M: The first clinical study using a new biodegradable implant for the treatment of lips, wrinkles, and folds. *Aesthetic Plast Surg* 22:97, 1998
8. Friedman PM, Mafong EA, Kauvar AN, et al: Safety data of injectable nonanimal stabilized hyaluronic acid gel for soft tissue augmentation. *Dermatol Surg* 28:491, 2002
9. Lowe NJ, Maxwell CA, Lowe P, et al: Hyaluronic acid skin fillers: Adverse reactions and skin testing. *J Am Acad Dermatol* 45:930, 2001
10. Duranti F, Salti G, Bovani B, et al: Injectable hyaluronic acid gel for soft tissue augmentation. A clinical and histological study. *Dermatol Surg* 24:1317, 1998
11. Bosniak S, Cantisano-Zilkha M: Restylane and Perlane: A six-year clinical experience. *Operat Tech Oculoplast Orbital Reconstruct Surg* 4:89, 2001
12. Lemperle G, Morhenn VV, Charrier U: Human histology and persistence of various injectable filler substances for soft tissue augmentation. *Aesthetic Plast Surg* 27:354, 2003
13. Narins RS, Brandt F, Leyden J, et al: A randomized, double-blind, multicenter comparison of the efficacy and tolerability of Restylane versus Zyplast for the correction of nasolabial folds. *Dermatol Surg* 29:588, 2003
14. Keefe J, Wauk L, Chu S, et al: Clinical use of injectable bovine collagen: A decade of experience. *Clin Mater* 9:155, 1992
15. Lupton JR, Alster TS: Cutaneous hypersensitivity reaction to injectable hyaluronic acid gel. *Dermatol Surg* 26:135, 2000
16. Fernandez-Acenero MJ, Zamora E, Borbujo J: Granulomatous foreign body reaction against hyaluronic acid: Report of a case after lip augmentation. *Dermatol Surg* 29:1225, 2003
17. Honig JF, Brink U, Korabiowska M: Severe granulomatous allergic tissue reaction after hyaluronic acid injection in the treatment of facial lines and its surgical correction. *J Craniofac Surg* 14:197, 2003
18. Q-Med Inc, Annual Report 2003. Available at: <http://www.q-med.com/pdf/ar2003eng.pdf>. Accessed May 5, 2004
19. Carruthers A, Carruthers J: A prospective, randomized, parallel group study analyzing the effect of BTX-A (Botox) and nonanimal sourced hyaluronic acid (NASHA, Restylane) in combination compared with NASHA (Restylane) alone in severe glabellar rhytides in adult female subjects: treatment of severe glabellar rhytides with a hyaluronic acid derivative compared with the derivative and BTX-A. *Dermatol Surg* 29:802, 2003
20. Niamtu J: Image is everything: Pearls and pitfalls of digital photography and PowerPoint presentations for the cosmetic surgeon. *Dermatol Surg* 30:81, 2004
21. Egado JA, Arroyo R, Marcos A, et al: Middle cerebral artery embolism and unilateral visual loss after autologous fat injection into the glabellar area. *Stroke* 24:615, 1993
22. Teimourian B: Blindness following fat injections. *Plast Reconstr Surg* 82:361, 1988
23. Castillo GD: Management of blindness in the practice of cosmetic surgery. *Otolaryngol Head Neck Surg* 100:559, 1989
24. Strauch B, Baum T, Robbins N: Treatment of human immunodeficiency virus-associated lipodystrophy with dermofat graft transfer to the malar area. *Plast Reconstr Surg* 113:363, 2004
25. Hanke CW, Higley HR, Jolivet DM et al: Abscess formation and local necrosis after treatment with Zyderm or Zyplast collagen implant. *J Am Acad Dermatol* 25:319, 1991