

Perioral Soft-Tissue Rejuvenation Techniques to Enhance Esthetic Restorative Dentistry

Abstract: Every practitioner has the obligation to offer his or her patients the latest advances in their profession. Dentistry has made a shift over the past 50 years from caries restoration and prosthetic replacement to preventative and esthetic rejuvenation. Related dental specialties have also blossomed with new procedures and an expanded scope of practice. This shift has also included more comprehensive care and treatment of the oral and maxillofacial region. Modern esthetic dentists realize the facial soft tissues serve as a frame for their restorative artwork. Contemporary oral and maxillofacial surgery includes cosmetic facial surgery. Procedures for such surgery are taught in oral and maxillofacial surgery residency programs, are part of the oral and maxillofacial surgery board exams, and are covered by oral and maxillofacial surgery malpractice companies. Esthetic dentists should understand facial aging, as well as the basic procedures available for facial rejuvenation by the oral and maxillofacial surgeon. Contemporary esthetic dentistry goes beyond the oral cavity, and the smile is truly enhanced by simultaneous facial rejuvenation. This article discusses the process of perioral facial aging and various cosmetic facial surgery options.

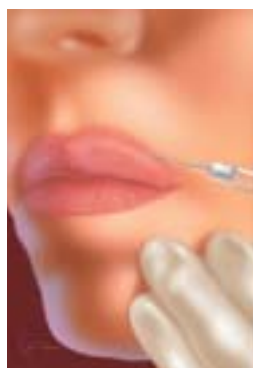
CE 1

Joseph Niamtu III, DDS

Board certified
American Board of Oral & Maxillofacial
Surgery

Fellow
American Academy of Cosmetic Surgery

Oral/Maxillofacial and Cosmetic
Facial Surgery
Richmond, VA



Perioral Facial Rejuvenation: Total Esthetic Dentistry

There is more to dentistry than the mouth.¹ Contemporary esthetic dentists realize a true esthetic result includes the teeth, as well as the surrounding soft tissues. It makes little sense to perform a beautiful full-mouth reconstruction, rejuvenating the teeth, and not pay attention to aging lips, perioral wrinkles, sagging jowls and neck skin, and submental fat deposits. This would be like surrounding the Mona Lisa with a plywood frame. The facial soft tissues should serve as the frame for the artwork of the esthetic restorative dentist. Contemporary oral and maxillofacial surgery includes cosmetic facial surgery.² Cosmetic facial surgery is taught in most oral and maxillofacial surgery programs and is part of the oral and maxillofacial surgery boards. It is even covered by oral and maxillofacial surgery malpractice insurance.

Facial aging is a universal phenomenon, but genetics and lifestyle contribute to the process. Sun damage and smoking can greatly accelerate the aging process. The facial skin loses the dense arrangement of collagen, which is replaced with elastic fibers. The epidermis thickens and dermal changes cause the skin to sag. On a deeper level, the submuscular aponeurotic system (SMAS) is a distinct layer of connective tissue that supports the skin from a deeper plane. The SMAS layer becomes lax and contributes

Learning Objectives:

After reading this article, the reader should be able to:

- discuss the importance of cosmetic facial surgery in contemporary oral and maxillofacial surgery.
- describe the aging process on various areas of the oral and maxillofacial region.
- identify and explain the procedures available for treating esthetic problems in the oral and maxillofacial region.

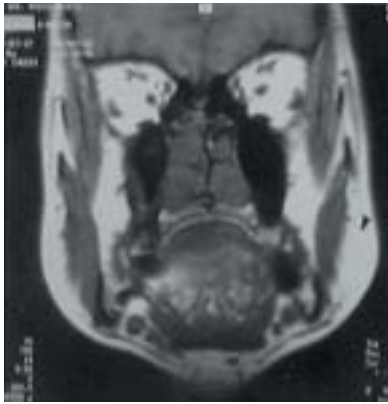

Figure 1—The white layers on the lateral portion of this computed tomography scan represent buccal fat deposits that have undergone gravitational descent causing jowl formation in a 55-year-old patient.



Figure 2—The same patient's face in her 20s and 80s, illustrating the effects of facial aging.

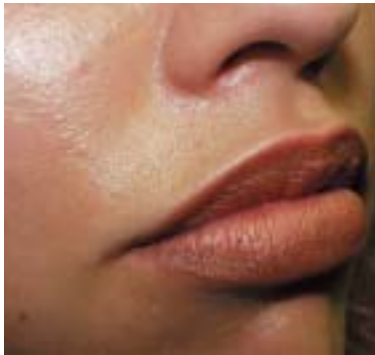

Figure 3—A defined white roll of the upper lip, which accentuates the "Cupid's bow" form of the esthetic lip.

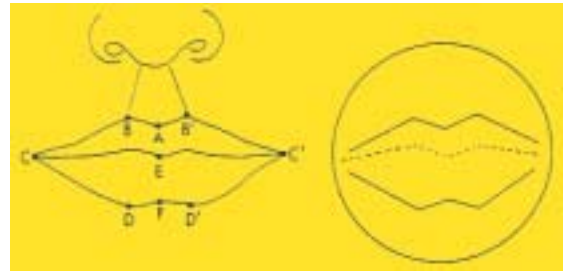


Figure 4—The esthetic upper lip has the shape of an *M*, and the lower lip border has the shape of a *W*.

to the generalized gravitational sagging of the face and neck (Figure 1).

Fatty deposits often accumulate in the chin and submental area, and the platysma muscle separates causing banding in the neck. This banding and excess skin is referred to as a turkey gobbler deformity. The nasolabial and mentolabial folds deepen, and the lips atrophy from various senescent changes, as well as from attrition of the teeth.

In the upper face, the eyebrows descend, and skin, fat, and muscle changes cause the eyelids to become droopy and puffy with herniated periorbital fat. The nasal tip descends, and fat atrophy occurs in the temporal regions. The skull shrinks, which further adds to the excess skin of the face. Figure 2 shows the right side of a woman's face in her 20s and the left side of her face in her 80s, illustrating the changes associated with facial aging.

Aging and Rejuvenation of the Periorbital and Lower Facial Regions

Obviously, youthful lips are germane to a pretty smile. Performing a \$20,000 restorative dental case without rejuvenating the lips does not serve the patient. Basic lip rejuvenation involves adding definition and volume to the lips. The white roll is the protuberant area at the junction of the skin and vermilion mucosa

(mucocutaneous junction). Lips with a definite white roll of the upper lip, which stands out and gives form to Cupid's bow (Figure 3), are considered attractive. The nasal philtrum should also have well defined columns, which can be seen in Figure 3 above the center of the lip.

The white roll in the upper lip is shaped like an *M*, and in the lower lip the vermilion-cutaneous junction is shaped like a *W* (Figure 4). Many people do not realize the lower lip is larger in most individuals (two thirds the lip volume). Various procedures exist for patients without definition at the vermilion-cutaneous junction. The most common technique has been augmentation with bovine collagen (Zyplast[®],^a). Zyplast[®] is a paste-like preparation containing lidocaine and is injected with a 30 gauge needle (Figure 5).

This injection is usually made without anesthetic, but local anesthetic infiltration or nerve block may be used. Some patients are allergic to bovine tissues; therefore, all patients must be tested for an allergy with an intradermal forearm injection of collagen 1 month before lip augmentation. Collagen is safe and predictable; however, it is resorbed over a period of 3 to 6 months and requires regular maintenance injections. Newer nonanimal-derived collagens are available but have the same

^aINAMED Corporation, Santa Barbara, CA 93111; (805) 683-6761

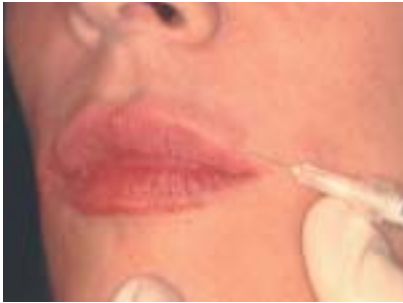

Figure 5—Injectable collagen augmentation of the white-roll area in the upper lip.

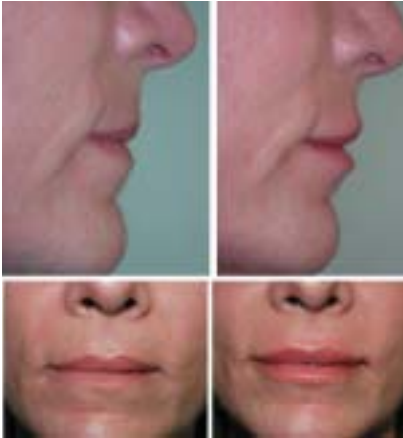

Figure 7—Before and after images of a patient treated with Zyplast (bovine collagen). Notice the improved lip esthetics, including more volume, definition, and pout.

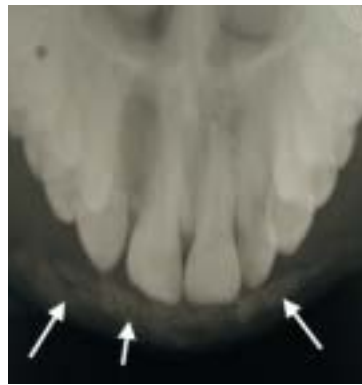

Figure 6—Shows an occlusal radiograph of a patient after injection with Radiance™ FN. The radiopaque nature of the material is shown as thin wisps of hydroxyapatite, visible in the upper lip area.



Figure 8—Top: Liposuction fat harvested from the abdomen. Middle: Harvested fat in the middle of the tubes after centrifuging. Bottom: Harvested fat being injected into the lip and nasolabial fold.

drawback of only lasting for 2 to 3 months. One of the most exciting and anticipated treatments for lips, lines, and wrinkles are the new fillers soon to be approved by the Food and Drug Administration (FDA). RESTYLANE[®] and PERLANE[™] are nonhuman-derived hyaluronic acid. These substances are molecular sugars derived from bacterial culture. Because they are nonhuman, no allergy testing is required. The most desirable quality of RESTYLANE[®] and PERLANE[™] is that they last considerably longer than collagen—from 8 months to 1 year, depending on the site of injection. RESTYLANE[®] is usually used in the lips, whereas PERLANE[™] has a larger particle size and is used for deeper lines and wrinkles. Some media mistakenly have claimed these substances are a replacement for Botox. However, a filler merely plumps whereas Botox chemically denervates motor nerves to induce facial muscle softening.

In addition to the aforementioned new fillers, some permanent fillers are due for FDA approval. Radiance[™] FN^c is a filler substance consisting of a hydroxyapatite paste. It is injected in small quantities to fill wrinkles and facial folds and plump up lips. Because this is an organic bone-like substance, it may be visible on routine dental x-rays. It appears as

radiopaque wisps in the lip or facial tissues (Figure 6). Radiance[™] FN will last 3 to 5 years in the soft tissues. Radiance[™] is used in an off-label manner because it is approved by the FDA for use in the body but not specifically for cosmetic uses. Artecoll^d is also a new filler awaiting FDA approval. This truly is a permanent filler made of methyl methacrylate microspheres (the same material as denture acrylic), which are mixed with bovine collagen. Artecoll is used for filling deeper facial wrinkles and folds. If overinjection or asymmetry occurs, it could be permanent. RESTYLANE[®], PERLANE[™], and Artecoll have been used in Europe, Canada, and Australia for over a decade.

Usually, no recovery time is necessary after injecting the fillers, and some patients will present for augmentation the day before a social affair. Besides providing definition at the vermillion-cutaneous junction, fillers may be injected deeper in the lip to add volume. Figure 7 shows a patient before and after lip

^bMedicis Inc, Scottsdale, AZ 85258; (800) 900-6389

^cBioForm, Inc, Frankville, WI 53126; (262) 835-9800

^dROFIL[®] Medical International NV, 4817 ZB Breda, Netherlands; +31 (0)76 515670

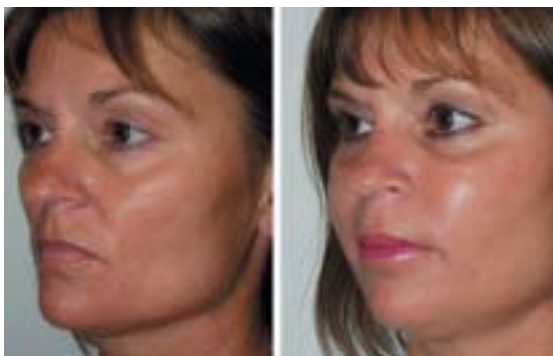

Figure 9—A woman with poor perioral esthetics because of thin lips, deep nasolabial folds, and flat malar (cheekbones) prominences. She is shown after undergoing fat transfer from her abdomen to her lips, nasolabial folds, and cheeks.

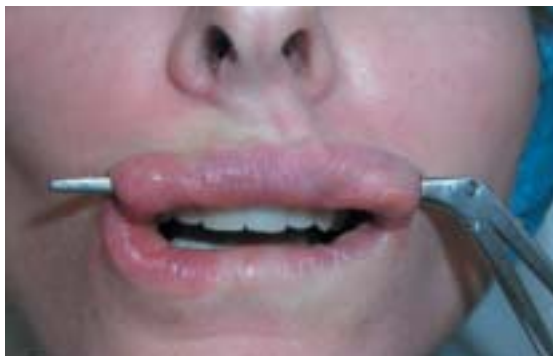

Figure 10B—The passing instrument making a tunnel in the upper lip.

augmentation with bovine collagen. The white-roll area, as well as the deeper tissues of the lip, was augmented to increase volume and definition. Note the improved “pout” from the augmentation.

Various injectable products are available for lip augmentation, including human fascia lata (FASCIAN™,e), human dermal preparations, and tissue-cultured preparations made from the patient’s own skin.³

Fat transfer is an older procedure that has found resurgence in lip and facial augmentation. Fat is harvested from the abdomen, processed by washing and centrifuging, and then injected into the lips. Extra harvested fat is then frozen, and the patient can return to the office for periodic reinjections. Although many of the fat cells die or are resorbed by the body, studies⁴ show after 3 injections, enough fat survives to have a permanent effect. Figure 8 shows the fat-transfer process, and Figure 9 shows a patient before and after fat-transfer treatment.

Alloplastic materials such as expanded polytetrafluoroethylene (GORE-TEX®.f) can



Figure 10A—Advanta™ implant.

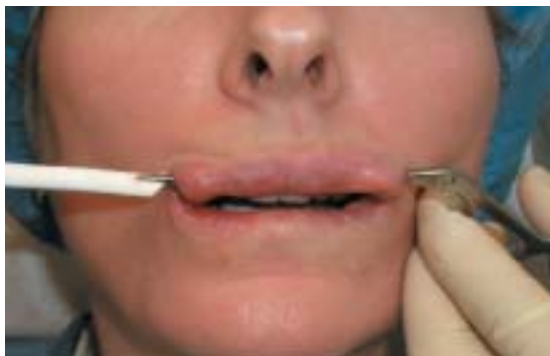

Figure 10C—The implant ready to be passed back through the tunnel.

be implanted in the lips to add definition or volume. Figure 10 shows a polytetrafluoroethylene implant (Advanta™ Facial Implant®) inserted into the lip for augmentation. Small stab incisions are made at the commissures, and the lip is tunneled with a passing instrument. The Advanta™ implant is then pulled through the tunnel as a permanent implant. Healing usually takes 3 to 5 days. The implant is permanent but may be removed if necessary. Figure 11 shows a patient before and after upper and lower lip augmentation with Advanta™ implants.

Perioral rhytids (wrinkles) or “lipstick lines” are a huge esthetic problem, especially for women. These vertical lip wrinkles result from the constant movement of the lip muscles. They are especially evident in smokers, presumably from the constant puckering involved in smoking cigarettes. These lines cause lipstick to run from the lips onto the facial skin. Although these lines can be injected with collagen for temporary plumping, laser technology has introduced a more permanent solution. Laser light from carbon dioxide

^eFascia Biosystems, LLC, Beverly Hills, CA 90210; (888) 332-7242
^fWL Gore & Associates, Inc, Flagstaff, AZ 86003; (800) 437-8181

^gAtrium Medical Corporation, Hudson, NH 03501; (800) 528-7486

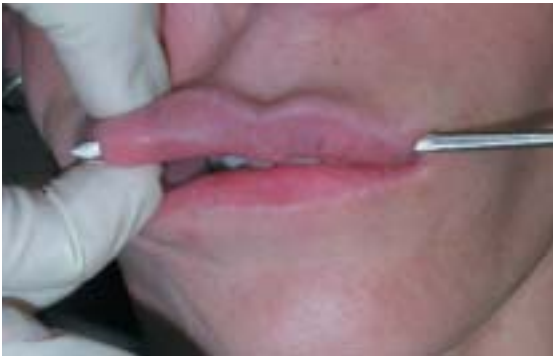

Figure 10D—The implant after it is passed through the tunnel.

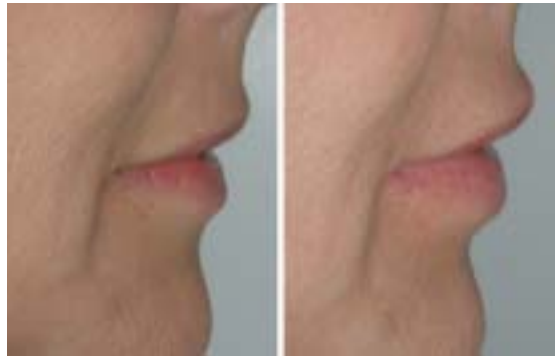

Figure 11—A patient before and after use of Advanta™ lip implants. Notice the increase in volume, pout, and projection in the after-picture. This product will enhance cosmetic dental procedures.

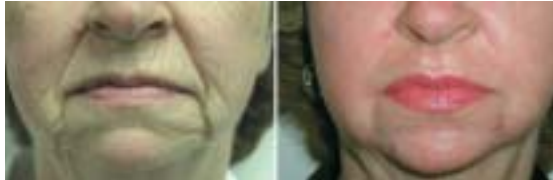

Figure 12—Radical improvement of perioral aging can be achieved with combination procedures. This patient underwent full-face CO₂ laser resurfacing, GORE-TEX® white-roll upper-lip and lower-lip augmentation, and fat transfer to both lips.

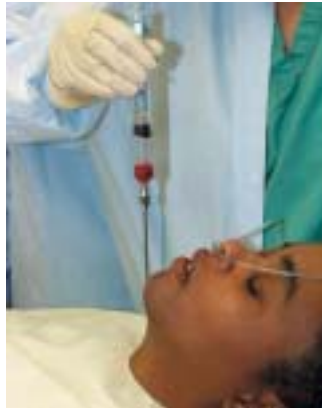

Figure 13—Liposuction of the submental region is performed with intravenous sedation and can recontour the submental and upper neck regions. Note the mixture of fat and blood in the syringe.

(CO₂) or erbium-yttrium aluminum garnet (Er:YAG) lasers cause controlled burns of the skin. Skin layers can be predictably removed from 30 μm to 300 μm. By lasering the skin down to the superficial layers of the dermis, thermal changes cause the formation of new collagen fibers, and the skin reforms over a tighter dermis, eliminating wrinkles. This process is called neocollagenation. Laser resurfacing of the lips or facial skin produces improvements of wrinkles and a generalized tightening of the skin that can last for years. This procedure takes about an hour to perform, and the patient develops erythema of the skin, which fades over several weeks. Most laser-resurfacing patients return to work 2 weeks after a full-face procedure. Figure 12 shows the rejuvenating effects of resurfacing on the perioral tissues with a CO₂ laser (UltraPulse® Encore^h).

When lip definition and volume augmentation are combined with laser resurfacing, significant rejuvenescent changes can occur. Denture patients have the most severe problems involving perioral rehabilitation. Because of tooth- and bone-support loss, as well as continued atrophy, these patients often appear more aged than they are.

Submental fatty deposits without skin lax-

^hLumenis™, Santa Clara, CA 95051; (800) 635-1313

ity can frequently be treated with submental liposuction. A dilute solution of local anesthesia (0.1% lidocaine with 1:1 million concentration of epinephrine) is infiltrated into the fatty deposits. Then a suction device is inserted just under the skin, and the excess fat is sculpted to a more esthetic form (Figure 13).⁵ Many patients also are retrognathic or micrognathic, and a chin implant can be simultaneously inserted to further improve the chin and submental esthetics.⁶ Cervicofacial liposuction is usually performed in the office with intravenous sedation and requires a recovery of 7 to 10 days. Figure 14 shows the intraoral placement of a GORE-TEX® chin implant. Note the mental nerves that have been dissected and preserved.

Figure 15 shows a picture of a patient before and after treatment with submental liposuction and a GORE-TEX® chin implant. A liposuction and chin implant procedure takes about 1 hour and requires about 1 week for recovery.

In those patients with redundant submental and neck skin, as well as droopy jowls, more aggressive procedures are required. Rhytidectomy (facelifting) is the only procedure that will

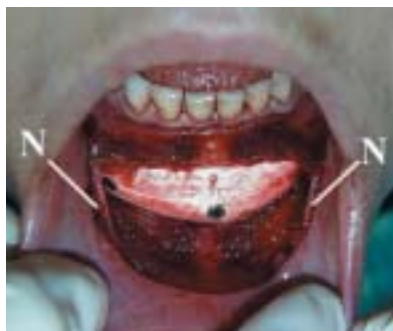

Figure 14—A GORE-TEX® chin implant has been placed through an intraoral incision. Note the mental nerves (N) that have been preserved laterally.

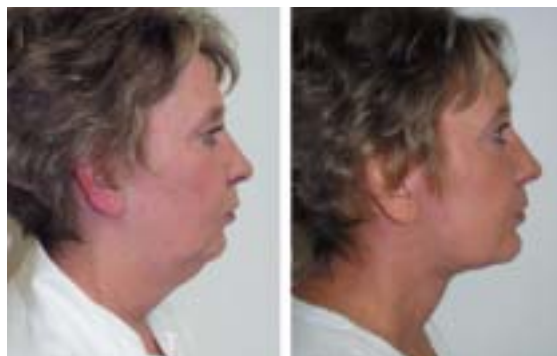

Figure 16—A rhytidectomy (facelift) procedure is required to address sagging jowls and excess neck skin. This before-and-after picture illustrates the amount of rejuvenation possible with this total lower facial rejuvenation. A GORE-TEX® chin implant also was used in this patient to further enhance her profile.

address this type of lower facial aging more definitively.

A facelift consists of dissecting the subcutaneous tissues and tightening the SMAS layer, as well as the skin. The incisions are primarily hidden in the hairline with the exception of the preauricular area where the same type of scar as that of a temporomandibular-joint surgery procedure remains. The sagging SMAS layer can be suspended by excision or various tightening procedures. After that, the skin is tightened over the suspended SMAS and the excess skin is excised. Excess facial and neck fat is liposuctioned, and the platysma is tightened in the midline and under the angle of the mandible. This multilayer operation provides ultimate lower facial rejuvenation, which can last up to a decade. A face-lift requires a 2-week recovery. Figure 16 shows a patient before and after a facelift. Note the drastic improvement of the sagging jowls and excess neck skin.

Summary

New and emerging technologies, as well as an expanded scope of practice, have influenced all aspects of general dentistry and the

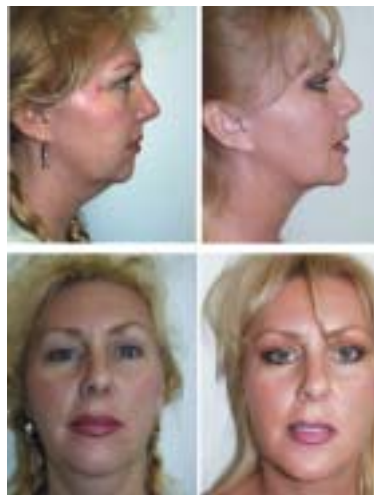

Figure 15—Reduction of submental fat and profile improvement using submental liposuction and GORE-TEX® chin implant.

dental specialties, including oral and maxillofacial surgery. Dentistry has seen a renaissance over the past century from caries restoration to total oral and maxillofacial health. All practitioners have the obligation to offer their patients the latest advances in their profession. Esthetic dentistry represents a means of treating the entire oral and maxillofacial region, in addition to the esthetic concerns of the teeth. Those practitioners who realize the holistic nature of esthetic rejuvenation will provide the most comprehensive care for their patients and will accent their dental artwork with an esthetic soft-tissue frame.

Disclaimer

The author has no conflict of interest with any of the products or procedures in this manuscript. He has no honorarium, stock holdings, or consulting agreements with the products or procedures described.

References

1. Niamtu J. Cosmetic oral and maxillofacial surgery options. *Journal of the American Dental Association*. 2000;131:756-764.
2. Niamtu J. New technologies in cosmetic facial surgery. *Va Dent J*. 2000;77:9-12.
3. Alster TS, West TB. Human-derived and new synthetic injectable materials for soft-tissue augmentation: current status and role in cosmetic surgery. *Plast Reconstr Surg*. 2000;105:2515-2528.
4. Coleman SR. Long-term survival of fat transplants: controlled demonstrations. *Aesthetic Plast Surg*. 1995;19:421-425.
5. Niamtu J. Lower third facial rejuvenation. *Plastic Surgery Products*. 2000:28-32.

Quiz 1

1. What does the facial skin lose with age?
 - a. dense arrangement of elastic fibers
 - b. abundant moisture
 - c. dense arrangement of collagen
 - d. abundant fatty deposits
2. The distinct layer of connective tissue that supports the skin from the deeper plane is referred to as:
 - a. submuscular aponeurotic system.
 - b. collagen connective tissue
 - c. turkey gobbler deformity
 - d. submuscular connective tissue
3. What occurs with age in the temporal regions?
 - a. herniated fat
 - b. fat atrophy
 - c. banding
 - d. fat depositing
4. What has been the most common technique used for patients lacking definition at the vermilion—cutaneous junction?
 - a. reduction with nonanimal collagen
 - b. augmentation with nonanimal collagen
 - c. augmentation with bovine collagen
 - d. reduction with bovine collagen
5. What is an advantage of nonhuman-derived hyaluronic acid compared with collagen?
 - a. It is safer and more predictable.
 - b. It is permanent.
 - c. It requires no allergy testing.
 - d. It has a smaller particle size.
6. How does Botox function?
 - a. It denervates motor nerves to induce facial muscle softening.
 - b. It innervates nonmotor nerves to induce facial skin tightening.
 - c. It is a filler that plumps.
 - d. none of the above
7. What older procedure has found resurgence in lip and facial augmentation?
 - a. fascia lata
 - b. fat transfer
 - c. tissue-cultured preparations
 - d. dermal preparations
8. Perioral rhytids are more permanently treated with:
 - a. creams
 - b. fillers
 - c. collagen
 - d. laser technology
9. According to this article, what type of lasers are used to cause controlled burns of skin for treatment of perioral rhytids?
 - a. CO₂ and Er:YGGs
 - b. Nd:YAG and CO₂
 - c. Er:YGGs and Er:YAG
 - d. CO₂ and Er:YAG
10. A facelift consists of:
 - a. dissecting the subcutaneous tissues.
 - b. tightening the SMAS layer.
 - c. tightening the skin.
 - d. all of the above

Please see tester form between pages 872 and 873.

This article provides 1 hour of CE credit from Dental Learning Systems, in association with the University of Southern California School of Dentistry and the University of Pennsylvania School of Dental Medicine, representatives of which have reviewed the articles in this issue for acceptance. Record your answers on the enclosed answer sheet or submit them on a separate sheet of paper. You may also phone your answers in to (888) 596-4605 or fax them to (703) 404-1801. Be sure to include your name, address, telephone number, and social security number.