

Advanta Facial Implants

Joseph Niamtu III, DMD

Oral/Maxillofacial and Cosmetic Facial Surgery, 10230 Cherokee Road, Richmond, VA 23235, USA

There has been a huge increase in patients seeking cosmetic surgery. Many factors are driving this increase. Foremost is the fact that the baby boomers are turning 50 years old at an alarming rate of one every 8 seconds. This generation is the one that “would not age” and the one that basked in the sun with an admixture of baby oil to develop a savage tan. Other factors affecting this increase include the fact that more specialties are performing cosmetic facial surgery. The past 20 years have brought about an increase in cosmetic procedures in dermatology; oral and maxillofacial surgery; ophthalmology; oculoplastic surgery; ear, nose, and throat; and other specialties. In addition, changes of great magnitude have occurred in the health care system. Many surgeons have transitioned from a hospital-based practice to an office/surgery center environment. This environment makes the surgical experience easier, less expensive, and more personal, with increased anonymity. Finally, technologic increases in anesthesia, equipment, and procedures have made it easier than ever to have cosmetic surgery. The media (including television reality shows) and individual physician marketing also have heightened the presence of cosmetic surgery. In short, this is a great time in history for cosmetic surgery. These factors have also led to a request for minimally invasive cosmetic procedures [1]. Today’s patients do not want to miss work or play and desire “wash and wear” surgical procedures. Botulinum toxin type A (Botox), Restylane, nonablative lasers, and facial implants are examples of minimally invasive cosmetic facial surgery.

Facial implants have been used for many years and have included a plethora of materials. Contemporary choices for fillers include fat, expanded polytetrafluoroethylene ([ePTFE] Gore-Tex; W.L. Gore Co., Flagstaff, Arizona), Silicone, Silastic, polyethylene, bovine collagen, human collagen, hydroxyapatite, acrylic microspheres, lactic acid, dermis, fascia, and others [2]. The remainder of this article addresses a specific brand of facial implant: Advanta (Atrium Medical, Hudson, New Hampshire).

Gore-Tex was developed by the W.L. Gore Company and has been used successfully for bioimplantation for 30 years [3–38]. ePTFE is basically Teflon, which is processed with a microporous configuration. This material has many unique properties. It is extremely biocompatible and does not form thick encapsulation as some materials do. For this reason, it is tissue friendly and can easily be removed if necessary. I began using Gore-Tex for facial implantation in 1996 and used it in multiple applications. I have placed over 100 Gore-Tex chin implants and this remains my material of choice for chin implantation. I also have used Gore-Tex cheek implants and these have worked well. I always anchor these implants with microfixation screws, which I believe has increased my success rate.

Despite having excellent experience with Gore-Tex chin and cheek implants, I have experienced less than satisfactory results with Gore-Tex soft tissue implants. In all fairness, any surgeon must factor in their learning curve and specific skill when judging any implant. I believe that techniques for implantation are in line with the standard of care and that most of the problems I experienced with Gore-Tex soft tissue implants were a result of the implant or level of placement. I have placed over 20 Gore-Tex multi-strand implants in nasolabial folds over the past

E-mail address: niamtu@niamtu.com

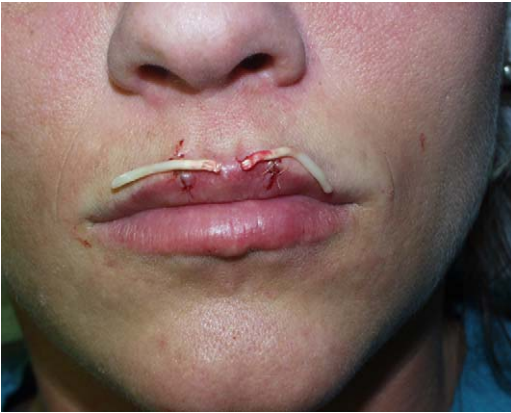

Fig. 1. Deformed, hardened, and contracted ePTFE implants removed 6 months after placement in the white roll area of the lip.

8 years. None of these have failed, and most patients are happy with their result. The biggest complaint is that the implants are palpable. I also have placed these multistrand implants in the lips and was not happy because they seemed to harden over time, becoming more visible and palpable. My biggest problems, however, have resulted from placing the small single-strand Gore-Tex implants superficially in the lip to reconstruct the “white roll.” I placed many of these implants by threading the implant with a trocar from one commissure to the other. Initially, the patients and I were very happy with the result. Over several months, many of these patients presented with hardened and contracted implants that showed distortion of the lip and became significantly more visible and palpable. After removing these implants

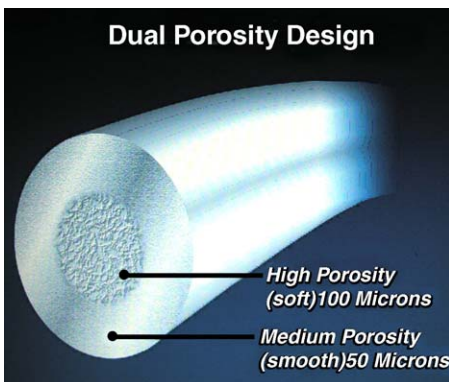


Fig. 2. The unique structure of the Advanta™ dual-porosity ePTFE facial implant. (Courtesy of Atrium Medical Corporation, Hudson, NH.)

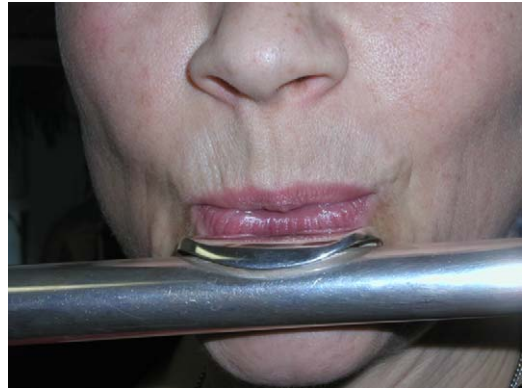

Fig. 3. This patient requested removal of her upper-lip implant due to the fact that it impeded her flute playing.

(which is an easy task), the implants were yellowed and contracted and frequently convoluted (Fig. 1).

Again, all clinicians must be fair when being critical of a product or technique. It may well be that these implants do not work when placed superficially in an area of significant movement. Although I still have patients with these implants who are pleased, I removed enough so that I ceased placing them. Due to this rate of implant removal, I took a several-year hiatus from placing lip implants (with the exception of injectable fillers).

While attending a cosmetic symposium sponsored by the American Academy of Cosmetic Surgery, I had a conversation with my friend and distinguished cosmetic dermatologist Dr. William Hanke. I related my previous problems with ePTFE implants in the lips and he told me of his experience with a new type of ePTFE facial implant called Advanta. He believed

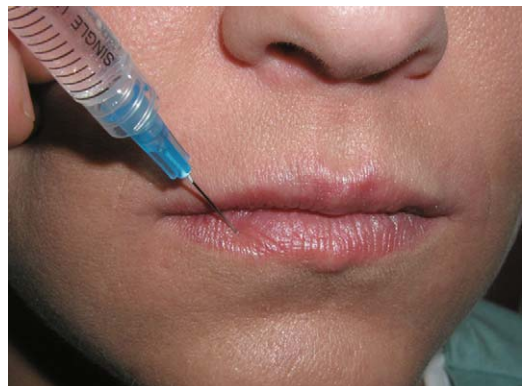

Fig. 4. Minimal infiltration across the lip vermilion and commissures is usually adequate for Advanta implant placement.




Fig. 5. It is necessary to measure the prospective implant with the mouth wide open. The error in this patient is 29% if the implant were measured in the closed-mouth position.

that the manufacturing process of this new product was superior and my experience would change as his did. After some time, Hanke [39] and Truswell [40] published their work, which led me to push ahead with this implant.

My investigations showed that the Advanta implants were different from the Gore-Tex implants I had used previously. They felt much more silky, soft, and pliable. The manufacturer attributes this look and feel to a sintering process in which the material is heated to impart these properties. In addition, the difference in this implant is the unique dual-core construction. Advanta implants are available in round or oval configurations and have an outer, medium-porosity smooth core of 50 μm and an inner, high-porosity soft core of 100 μm (Fig. 2).

This unique configuration and manufacturing process add up to make an implant that is different from what I have experienced in the past. When patients inquire about Advanta implants, I let them handle a sample to show them what will be going into their lip.

They appreciate knowing what the material looks and feels like.

Patient selection

Most any healthy patient who desires lip augmentation is a candidate for Advanta implants. I believe that any lip implant should be used with caution (or not at all) in patients who play woodwind instruments, who have oral habits such as nail biting or pencil biting, or who continually fidget with their lips (Fig. 3).

Also, patients who are emotionally resistant to foreign-body implantation are not candidates. This seems obvious, but some patients will express “not liking” an implant yet will consent to the procedure. They may later come to “fear” the foreign material and request removal. Many patients will present for lip augmentation on a whim after reading an article or seeing a movie star with pretty lips. An astute surgeon must “feel out” these patients to see whether they are appropriate candidates for such a procedure. One great thing about Advanta lip implants is that they take 10 minutes to put in and 10 minutes to remove, so the procedure is effectively reversible. I believe that treating a prospective patient with a temporary injectable filler is sometimes a good idea to see how they like having fuller lips. Some patients will specifically request lip implants for several reasons. First, they are permanent. Second, they are cost effective because in my practice, the fee for a single lip implant is \$1000 and the fee for a syringe of injectable filler is \$440. Because the filler must be repeated, the implant is more cost effective. Finally, some patients are “needle phobic” and would rather undergo a single surgical procedure instead of multiple needle procedures.

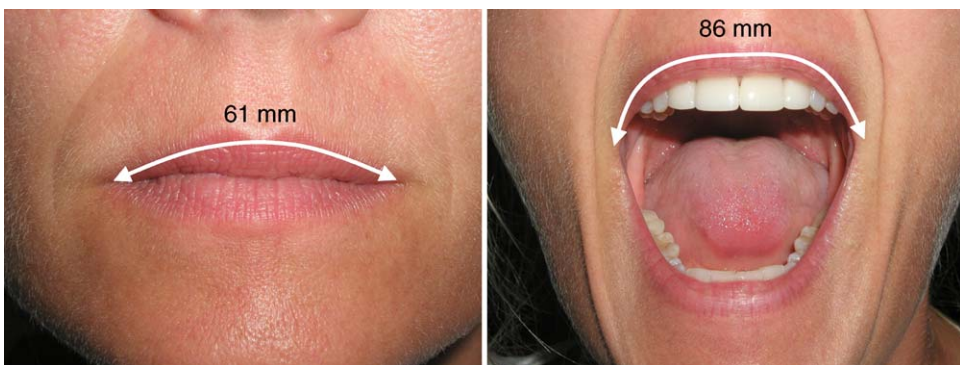


Fig. 6. The 4.0-mm round Advanta facial implant on a swaged trocar.

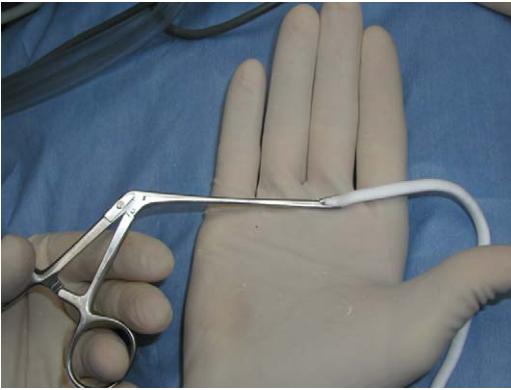

Fig. 7. A tendon passer with teeth and a tapered beak can be used to pass the implant.

It is important to let patients know in advance that they will be able to feel the implant (just like breast implants), but normal function such as smiling, kissing, and so forth is normally not affected. Patients also must realize that the implant may be visible in some extreme animations such as stretching the lips over the teeth. I remain impressed by how little these implants effect function.

Surgical placement

Placing Advanta implants in the lip is a simple procedure, but strict adherence to several principles must be maintained. Generally, I place these implants with local anesthesia. I use topical anesthesia on the mucosa, followed by local anesthetic infiltration across the lip from commissure to commissure. It does not require much anesthetic solution to render the lips insensate, and it is important to not overinject

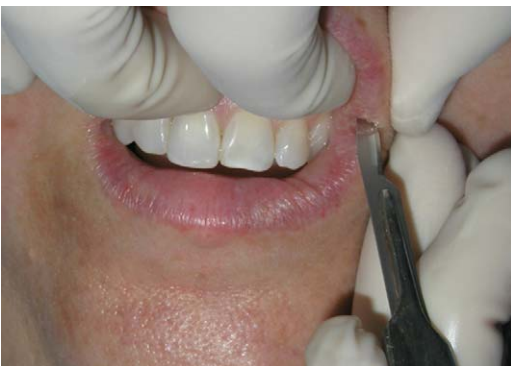

Fig. 8. The incision is made several millimeters medial to each oral commissure.



Fig. 9. Attempting to pull the implant through an incision that is not generous enough will result in a tapering of the implant.

the lip because the anesthetic volume will distort the lip and possibly skew the surgical judgment of placement (Fig. 4).

Most patients will request implants in both lips, but some patients will want to “test the waters” with a single implant.

Implant measurement

Like any new procedure or procedure that is new to a practitioner, a learning curve exists. The biggest pitfall in my experience is placing an implant in the lips that is too short. It is stated that the implant should be measured by placing it over the lips from one commissure to the other. Some practitioners neglect to say that the mouth should be maximally opened during the measurement or the implant will be too short (Fig. 5).

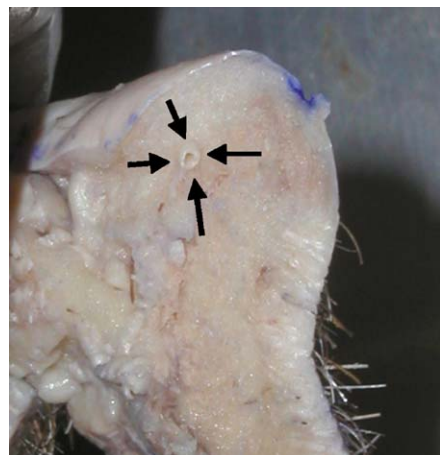


Fig. 10. The labial artery courses through the posterior one third of the lip and is usually not a problem in implant placement.

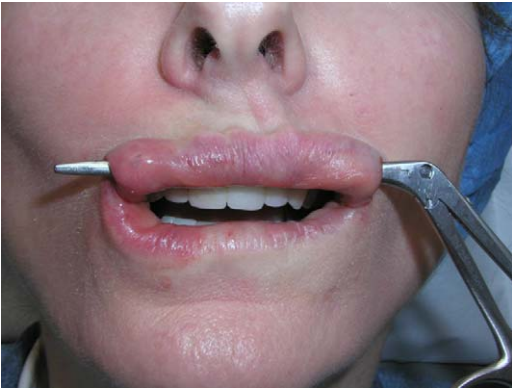

Fig. 11. The tendon passer is threaded from the entrance to the exit incision and the implant is then pulled back through the lip.

After adequate local anesthesia, I place the implant (which comes in 15-cm lengths) over the lip while the patient opens his or her mouth to the maximum opening. The implant should reach both commissures. In some patients, a single 15-cm implant can supply enough material to augment both lips, but it is a mistake to try to obtain two implants from a single strand in all patients because some patients have longer lips and the implant will fall short.

The Advanta implants for lip augmentation are available in various sizes and in round and oval configurations. I prefer the 5.0-mm round implant for most lip augmentation. In very small patients or those wanting minimal augmentation, I may elect to use a 4.0-mm implant. I initially used the oval implants but abandoned this configuration because no matter how a round implant is placed, it will remain round. An oval implant, on the other hand, may provide differ-

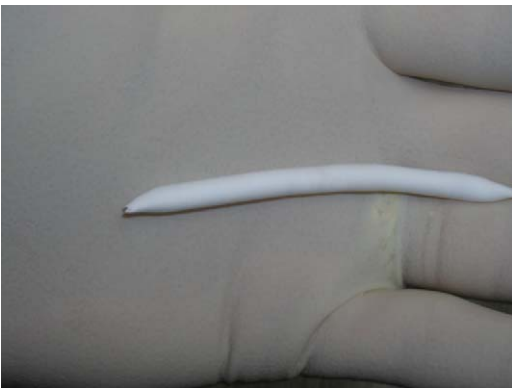

Fig. 12. The implant edges are tapered to enhance insertion and to tuck into the stab incisions.

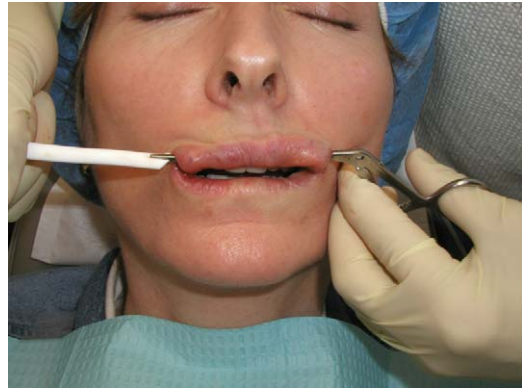

Fig. 13. The implant is grasped with the tendon passer and pulled back through the incision.

ent contour in the same area if twisted (if the oval implant does not lay flat, one part of the lip could be more augmented than the other). At the time of this publication, only the 4.0-mm implants are available on a swaged trocar (Fig. 6). It is my hope that Atrium Medical will make a suitable trocar for the 5.0-mm implant because it assists implant placement.

The basic premise of implant placement is to make stab incisions at both commissures and to thread the implant through the lip. The implant may be pulled through the lip with multiple modalities including a passing awl and suture, a passing instrument such as a tendon passer, or an included trocar. I most frequently use a tapered tendon passer with teeth (Fig. 7).

After adequate local anesthesia, a No. 11 scalpel blade is used to make a stab incision just medial to each commissure (Fig. 8). It is important to make the length of this incision large enough to accommodate

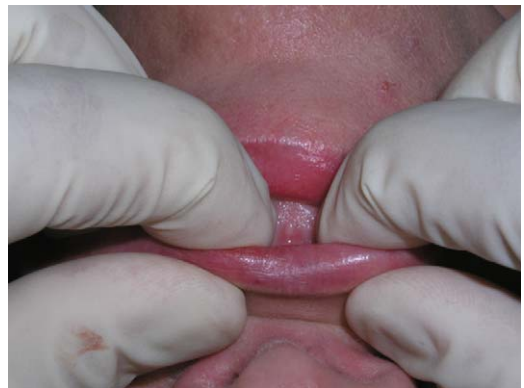

Fig. 14. After passing the implant, the lip is then stretched to fully accommodate the implant.

the implant with out distorting it. If the incision is not long enough, then the implant will exhibit ductility and will be tapered along the leading edge (Fig. 9), which will cause smaller augmentation on the leading edge and larger augmentation on the following edge. Another important principle to adhere to is the level of placement of the implant. Basically, I aim for the exact center of the lip to place the implant, which would be in a submuscular plane. If the implant is placed too superficially, then it will be visible and impede normal lip function. If the implant is placed too deeply, then the amount of augmentation is decreased and the labial artery is in jeopardy. The labial artery usually runs in the posterior one third of the lip (when viewed in cross-section) (Fig. 10) and is at the level of the anterior incisal plane in the lower lip [41].

After the stab incisions are made, the implant is threaded. I generally use a tendon passer (Byron Mentor, Byron Medical, Tucson, AZ [www.byron.com]) to thread the implant. Step 1 is to thread the implant from the entrance incision and out the exit incision (Fig. 11).

Again, it is imperative to remain in the same plane in the middle of the lip. As the tendon passer is advanced, the lip bunches. After the tendon passer is passed through the exit incision, the lip will need to be stretched to its normal length.

Passing this instrument will make a tunnel. The size of this tunnel should be just slightly smaller than the implant diameter. If the tunnel is too wide, then the implant will migrate; if too small, the implant will not lie correctly. A blunt instrument such as a knitting needle may be used to dilate the tunnel if necessary. Step 2 is to taper the edges of the implant to facilitate the threading and the position of the implant tail at the commissure (Fig. 12). Step 3 is to firmly grab the implant at the leading tapered edge and pull it through the tunnel (Fig. 13).

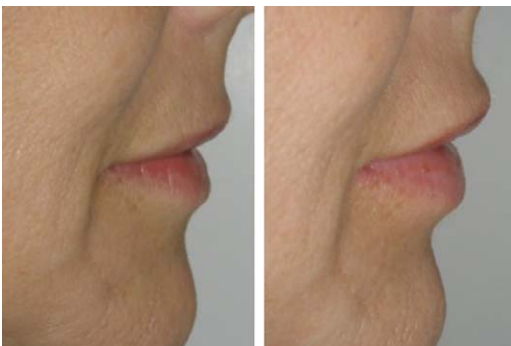

Fig. 15. A patient before (left image) and after (right image) upper- and lower-lip Advanta implants.

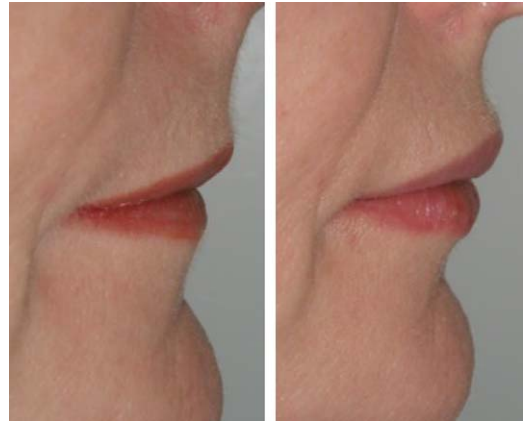

Fig. 16. A patient before (left image) and after (right image) upper- and lower-lip Advanta implants.

Having a tendon passer with teeth is helpful because it takes significant traction to pull the implant through the tunnel; it will frequently slip off the instrument if not firmly secured. Step 4 is to restretch the lip to its normal length to accommodate the implant in a natural lip position (Fig. 14).

It is important to make sure that the tapered implant tails lie deep in the incision, just shy of the commissure, and do not extend outside of the incision. The final step is to close the incisions. I use 6-0 nylon suture because my experience with resorbable suture has been that the wounds dehiscence.

Postoperatively, these patients are covered with cephalexin, 500 mg, every 6 hours for 5 days. The patient is asked to ice the lips for 48 hours and refrain from excessive lip function for a week. Postoperative swelling is variable. I have had patients return to work the next day and have had several patients experience severe lip swelling that took a week to

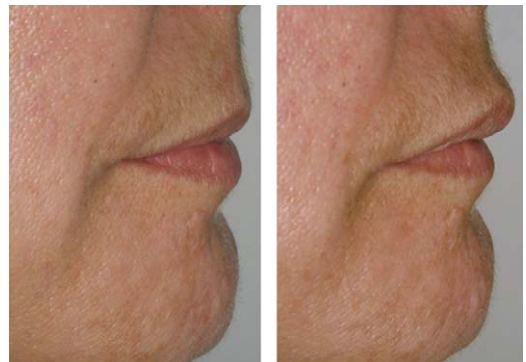

Fig. 17. A patient before (left image) and after (right image) Advanta implant in the upper lip only.

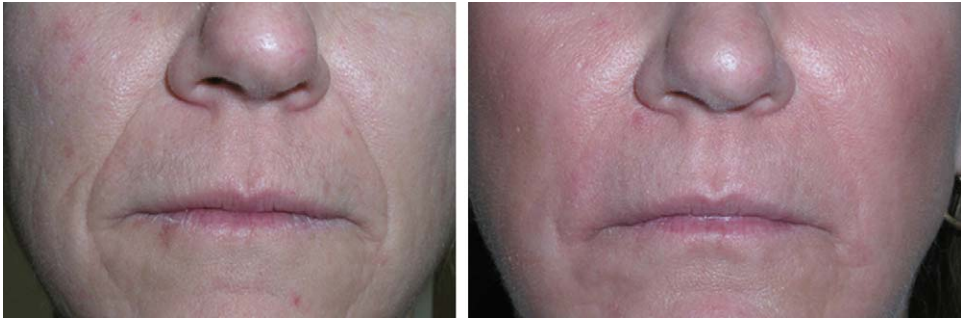

Fig. 18. This patient was treated with Advanta implants in the nasolabial folds with concomitant carbon dioxide laser resurfacing.

resolve. Preoperatively, patients must be made aware of this variable healing. Appropriate analgesics are prescribed for several days. The sutures are removed on the fifth postoperative day.

Clinical results

Figs. 15 through 18 show before and after photographs of Advanta implant lip augmentation.

Alternate site implant placement

Although I use Advanta facial implants primarily for lip augmentation, they can be used for multiple

facial applications including augmentation of nasolabial folds, glabellar lines, mandibulolabial folds (drool lines), and acne scars.

To treat the nasolabial folds, the technique is similar to lip implant placement. The implant is placed in the subdermal plane. It is extremely important to make sure the implant lies within or just medial to the valley of the fold (this is a problem area for the novice surgeon). Many tissue planes come together in the nasolabial fold region and, when placing an implant (or filler) in this area, the implant can frequently displace laterally. When this happens, the implant increases the lateral portion of the nasolabial fold and makes it appear deeper. Accentuating a nasolabial fold in a patient who presented for effacement is a problem. Again, by placing the

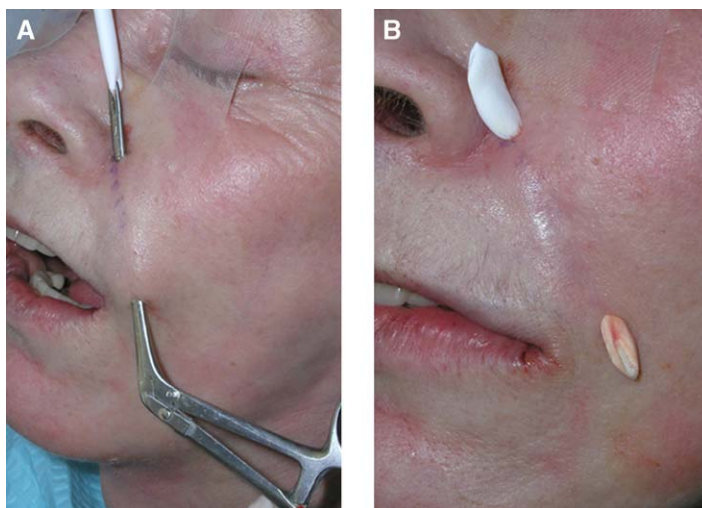


Fig. 19. (A) Placement of Advanta implants in the nasolabial region is similar to lip placement. (B) The implant will lie in the subdermal plane.

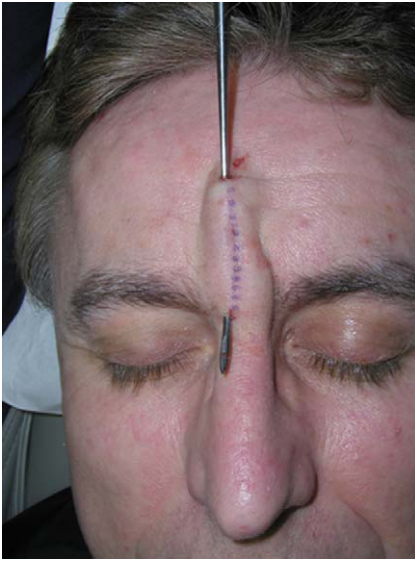

Fig. 20. A tunnel is made and a passing awl inserted to place an implant in the treatment of glabellar lines.

implant just nasally to the fold, accurate placement can be achieved. It is also important to inform the patient that an implant will not make the fold go away but will blunt the fold by decreasing the valley. It is also important for the patient to realize that the fold will be blunted in repose but still appear as a fold with animation such as smiling.

To treat the nasolabial fold, an entrance stab incision is made just inferior to the ala (although some surgeons will place the incision intranasally) and an exit stab incision is made at the inferior portion of the fold. The stab incisions are oriented to Langer's lines and are made as small as possible to accommodate

the implant. These generally heal without a scar, but on occasion, I will use the carbon dioxide laser to resurface these scars to better blend them. The implant is measured (with the mouth open) and its ends are tapered. A trocar, tendon passer, or awl and suture are used to pull the implant from the superior incision through the inferior incision (Fig. 19). The skin is then stretched to passively accommodate the implant and the ends are again trimmed to just fall within the stab incisions. The incisions are then closed with 6-0 nylon suture.

Glabellar lines

Occasionally, patients will present with the complaint of deep glabellar lines that are resistant to Botox and fillers. I have treated this area successfully with ePTFE implants. In other cases, I have used ePTFE implants in combination with Botox and carbon dioxide laser resurfacing for a maximum result. The method of placement is the same as in nasolabial folds and the implant is placed in the subdermal plane. I find it helpful to also treat this area with Botox when placing a glabellar implant because I believe that the reduced movement facilitates healing. Fig. 20 shows placement of an ePTFE glabellar implant.

Fig. 21 shows before and after photographs of a patient who received an ePTFE implant, Botox, and laser resurfacing.

Mandibulolabial folds (drool lines)

Downturned corners of the mouth or depressions in this area are difficult to treat. Although I have not placed Advanta implants in this area, other

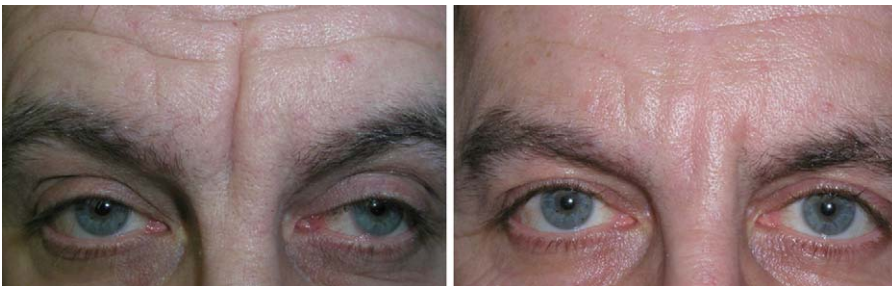

Fig. 21. A patient before (*left image*) and after (*right image*) being treated with ePTFE implant, Botox, and carbon dioxide laser resurfacing.

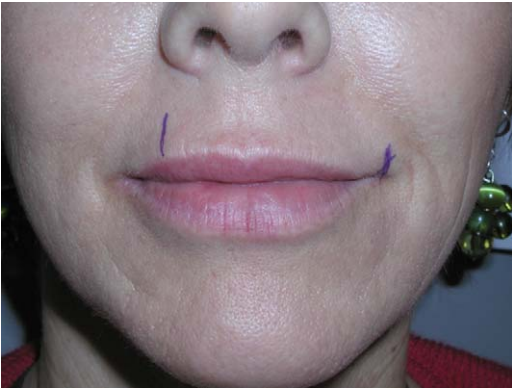

Fig. 22. This case resulted in an implant that was too short. The ends of the implant are marked; it is obvious that the patient's right side is too short.

practitioners frequently treat this area (James Gilmore, MD, personal communication, January 2004). The technique is the same but the implant is obviously smaller.

Complications

As with any procedure, there can exist complications with Advanta implants. I have placed about 50 of these implants and have never seen a complication that involved implant failure, rejection, or infection. Most complications have resulted from improper placement early in the learning curve. I placed implants in the lips that were too short in several patients (Fig. 22). Both of these patients returned for replacement with a longer implant. After placing an upper-lip implant in a flute player, she

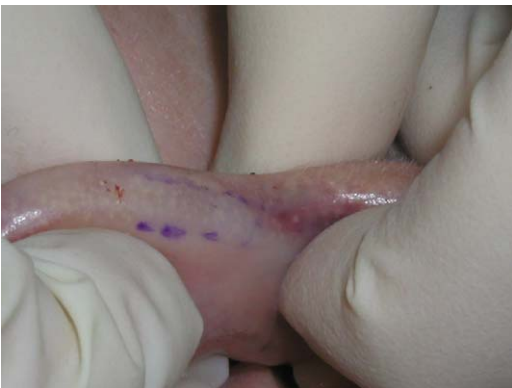

Fig. 23. This implant had the tail placed too superficially in the lip.

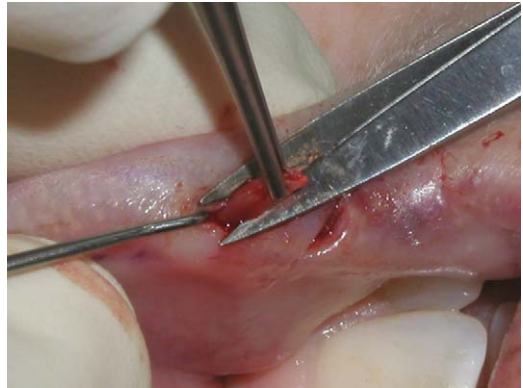

Fig. 24. In the same patient as in Fig. 23, the superficial portion of the implant is trimmed to reduce the palpable and visible bulge.

stated that it affected her ability to play high notes. It was removed and her flute playing returned to normal. One patient experienced prolonged swelling for over a month. Surgical exploration showed the swelling to be a result of a mucous retention phenomenon presumably from injury to the minor salivary glands at the time of placement.

In two patients, the implant tail was placed too superficially (one in the inferior nasolabial fold and one in the lip). The protruding tail was palpable and visible to the patient (Fig. 23). The implant was serviced by making a small incision over the implant tail and retrieving it with a skin hook. The tail was then trimmed and replaced into the incision (Fig. 24). The patients healed without complication and were pleased with the repair.

In cases in which implant removal is necessary, the procedure is easy. An incision is made over one

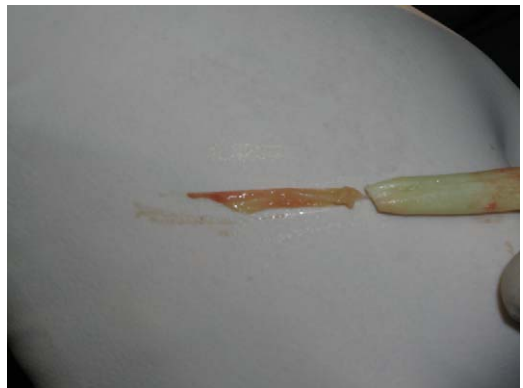

Fig. 25. Advanta implants are easily removed when necessary and may have a thin capsule attached.

of the tails of the implant and the area is bluntly dissected with a hemostat. After the implant tail is visible, it is grasped with a skin hook and then grasped with a hemostat. The lip is firmly grasped and traction is placed on the implant, which will generally extrude. If the implant is adherent, a small freer elevator can be used to dissect along the tunnel to free up the implant. The explant will usually have a small, thin capsule attached (Fig. 25).

Summary

Advanta facial implants represent a new method of ePTFE technology and appear to be different from previous ePTFE products. The implants appear to work well when used for lip augmentation; I have 18 months' experience with this implant. Placement of these implants is simple, and as long as attention is focused on several important factors, the implants are predictable. In my practice, lip augmentation is a frequently requested procedure. Although most of these patients desire injectables such as Restylane, a certain segment of this population desires a more permanent option. Advanta lip implants have proved to be an acceptable option by the surgeon and patient. The complication rate is low and the implants are serviceable. The procedure is reversible without extensive damage to normal tissue. The Advanta facial implant appears to be a useful option in the armamentarium of the cosmetic oral and maxillofacial surgeon.

References

- [1] The American Society for Aesthetic Plastic Surgery. Available at: <http://www.surgery.org/press/statistics-2003.php>. Accessed: May 2004.
- [2] Brown LH, Frank PJ. What's new in fillers? *J Drugs Dermatol* 2003;2(3):250-3.
- [3] Niamtu J. Facial implant applications for cosmetic facial surgery. *Plastic Surgery Products Novicom Publications* 1998;8(5):26-9.
- [4] Panossian A, Garner WL. Polytetrafluoroethylene facial implants: 15 years later. *Plast Reconstr Surg* 2004;113(1):347-9.
- [5] Ham J, Miller PJ. Expanded polytetrafluoroethylene implants in rhinoplasty: literature review, operative techniques, and outcome. 6. *Facial Plast Surg* 2003;19(4):331-9.
- [6] Niamtu J. Perioral soft tissue rejuvenation techniques. *Compend J* 2003;22(11):729-36.
- [7] Niamtu J. Alloplastic chin augmentation. *Cosmetic facial surgery. Oral Maxillofacial Surg Clin N Am* 2000;12(4):765-9.
- [8] Niamtu J. Cosmetic surgery options in oral and maxillofacial. *J Am Dent Assoc* 2000;131(6):756-64.
- [9] LaFerriere KA. The adjustable sling in corrective surgery for the aging neck: a promising technique when used with caution. *Arch Facial Plast Surg* 2003;5(6):502.
- [10] Godin M, Costa L, Romo T, et al. Gore-Tex chin implants: a review of 324 cases. *Arch Facial Plast Surg* 2003;5(3):224-7.
- [11] Steinsapir KD. Aesthetic and restorative midface lifting with hand-carved, expanded polytetrafluoroethylene orbital rim implants. *Plast Reconstr Surg* 2003;111(5):1727-37.
- [12] Romo III T, Baskin JZ, Scalfani AP. Augmentation of the cheeks, chin and pre-jowl sulcus, and nasolabial folds. *Facial Plast Surg* 2001;17(1):67-78.
- [13] Choe KS, Stucki-McCormick SU. Chin augmentation. *Facial Plast Surg* 2000;16(1):45-54.
- [14] Constantinides MS, Galli SK, Miller PJ, et al. Malar, submalar, and midfacial implants. *Facial Plast Surg* 2000;16(1):35-44.
- [15] Scalfani AP, Romo III T. Biology and chemistry of facial implants. *Facial Plast Surg* 2000;16(1):3-6.
- [16] Singh S, Baker Jr JL. Use of expanded polytetrafluoroethylene in aesthetic surgery of the face. *Clin Plast Surg* 2000;27(4):579-93.
- [17] Beaty MM. Treatment of neck laxity with a Gore-Tex cervical sling for patients with heavy neck tissues. *Facial Plast Surg* 2001;17(2):117-22.
- [18] Brody HJ. Complications of expanded polytetrafluoroethylene (e-PTFE) facial implant. *Dermatol Surg* 2001;27(9):792-4.
- [19] Maas CS, Denton AB. Synthetic soft tissue substitutes: 2001. *Facial Plast Surg Clin N Am* 2001;9(2):219-27.
- [20] Louis PJ, Cuzalina LA. Alloplastic augmentation of the face. *Atlas Oral Maxillofac Surg Clin N Am* 2000;8(2):127-91.
- [21] Cox III AJ, Wang TD. Skeletal implants in aesthetic facial surgery. *Facial Plast Surg* 1999;15(1):3-12.
- [22] Homsy CA. Complications and toxicities of implantable biomaterials for facial aesthetic and reconstructive surgery. *Plast Reconstr Surg* 1998;102(5):1766-8.
- [23] Lewis RP, Schweitzer J, Odum BC, et al. Sheets, 3-D strands, trimensional (3-D) shapes, and sutures of either reinforced or nonreinforced expanded polytetrafluoroethylene for facial soft-tissue suspension, augmentation, and reconstruction. *J Long Term Eff Med Implants* 1998;8(1):19-42.
- [24] Garner WL. Gore-Tex facial implants. *Plastic Surgery Educational Foundation DATA Committee. Plast Reconstr Surg* 1997;100(7):1899-900.
- [25] Saccoanno F, Bernardi C, Vittorini P. The expanded polytetrafluoroethylene (ePTFE) in the surgical treatment of Parry-Romberg syndrome: case report. *Aesthetic Plast Surg* 1997;21(5):342-5.
- [26] Still II EF. Gore-Tex in facial augmentations. *Plast Reconstr Surg* 1997;99(5):1468.
- [27] Scalfani AP, Thomas JR, Cox AJ, et al. Clinical and histologic response of subcutaneous expanded poly-

- tetrafluoroethylene (Gore-Tex) and porous high-density polyethylene (Medpor) implants to acute and early infection. *Arch Otolaryngol Head Neck Surg* 1997; 123(3):328–36.
- [28] Milam SB. Failed implants and multiple operations. *Oral Surg Oral Med Oral Pathol Oral Radiol Endod* 1997;83(1):156–62.
- [29] Maas CS. ePTFE (Gore-Tex) facial augmentation. *Plast Reconstr Surg* 1996;97(5):1076–7.
- [30] Sherris DA, Larrabee Jr WF. Expanded polytetrafluoroethylene augmentation of the lower face. *Laryngoscope* 1996;106(5 Pt 1):658–63.
- [31] Levine B, Berman WE. The current status of expanded polytetrafluoroethylene (Gore-Tex) in facial plastic surgery. *Ear Nose Throat J* 1995;74(10):681–4.
- [32] Schoenrock LD, Chernoff WG. Subcutaneous implantation of Gore-Tex for facial reconstruction. *Otolaryngol Clin N Am* 1995;28(2):325–40.
- [33] Owsley TG, Taylor CO. The use of Gore-Tex for nasal augmentation: a retrospective analysis of 106 patients. *Plast Reconstr Surg* 1994;94(2):241–8.
- [34] Cisneros JL, Singla R. Intradermal augmentation with expanded polytetrafluoroethylene (Gore-Tex) for facial lines and wrinkles. *J Dermatol Surg Oncol* 1993;19(6): 539–42.
- [35] Maas CS, Gnepp DR, Bumpous J. Expanded polytetrafluoroethylene (Gore-Tex soft-tissue patch) in facial augmentation. *Arch Otolaryngol Head Neck Surg* 1993;119(9):1008–14.
- [36] Conrad K, Reifen E. Gore-Tex implant as tissue filler in cheek-lip groove rejuvenation. *J Otolaryngol* 1992; 21(3):218–22.
- [37] Lassus C. Expanded PTFE in the treatment of facial wrinkles. *Aesthetic Plast Surg* 1991;15(2):167–74.
- [38] Neel III HB. Implants of Gore-Tex. *Arch Otolaryngol* 1983;109(7):427–33.
- [39] Hanke CW. A new e-PTFE soft tissue implant for natural-looking augmentation of lips and wrinkles. *Dermatol Surg* 2002;28:901–8.
- [40] Truswell W. A new implant for facial soft tissue augmentation. *Arch Facial Plast Surg* 2002;4:92–7.
- [41] Larrabee WF, Makielski KH. *Surgical anatomy of the face*. New York: Raven Press; 1993.