



The endoscopic brow and midface lift

Stephen W. Watson, MD, DDS^{a,*}, Joseph Niamtu, III, DDS^b,
Larry L. Cunningham, Jr, DDS, MD^c

^a*Willow Bend Cosmetic Surgery Center, 5824 W. Plano Parkway, Suite 101, Plano, TX 75093, USA*

^b*Private Practice, 11319 Polo Place, Midlothian, VA 23113, USA*

^c*Division of Oral and Maxillofacial Surgery, University of Kentucky, 800 Rose Street, Room D-508,
Lexington, KY 40515-0297, USA*

In recent years, endoscopic technology has revolutionized facial rejuvenation. This technology has led to minimal incisions, shorter recovery times, and lasting results. This revolutionization is especially evident with brow lift and midface procedures. The endoscopic brow lift was introduced in the early 1990s. Since that time, several methods have been used to improve the long-term results, including extensive undermining of the flap, muscle plication, and a variety of fixation techniques.

Facial cosmetic surgery has three goals: to restore, to rejuvenate, and to enhance. Restoration means reinstatement or reconstruction of a former, normal, or unimpaired state. Rejuvenation is the reinstatement or reconstruction of a youthful, fresh, new appearance. Enhancement is the state of having been made better, improved, or augmented, as in value, attractiveness, and so forth. The endoscopic brow and midface lift enhances the abilities of the cosmetic facial surgeon to accomplish these three goals. In addition to these goals of cosmetic surgery, there are two very important concepts that also have evolved with the emergence of advanced technology. The first concept is to work from the inside out whenever possible. The second concept is to reposition, or augment, before removing tissue. Aesthetic results are more natural and last longer when these concepts are observed.

The techniques used for the endoscopic brow and midface lift were designed with the aforementioned goals and concepts in mind. The most important step is to release attachments between the bone and the soft tissues. This step is accomplished by working in the subperiosteal plane, which can be done safely through minimal incisions using endoscopic instruments and imaging equipment that has been well described in other articles in this issue. This technique also focuses on repositioning the orbicularis oculi muscles superiorly and laterally, rather than on excision of “redundant” tissue. In addition, the intraoral dissection lends itself well to simultaneous malar augmentation when indicated.

Surgical technique

Measurements and markings should be accomplished before the administration of anesthesia and with the patient in an upright position (Fig. 1, Box 1). Two percent lidocaine 1:100,000 epinephrine is administered in each planned incision and standard Klein's tumescent infiltration is performed from the vertex of the skull to the nasal radix and all areas to be dissected. The entire maxillary vestibule is infiltrated with lidocaine 1:100,000 epinephrine from the piriform

* Corresponding author.

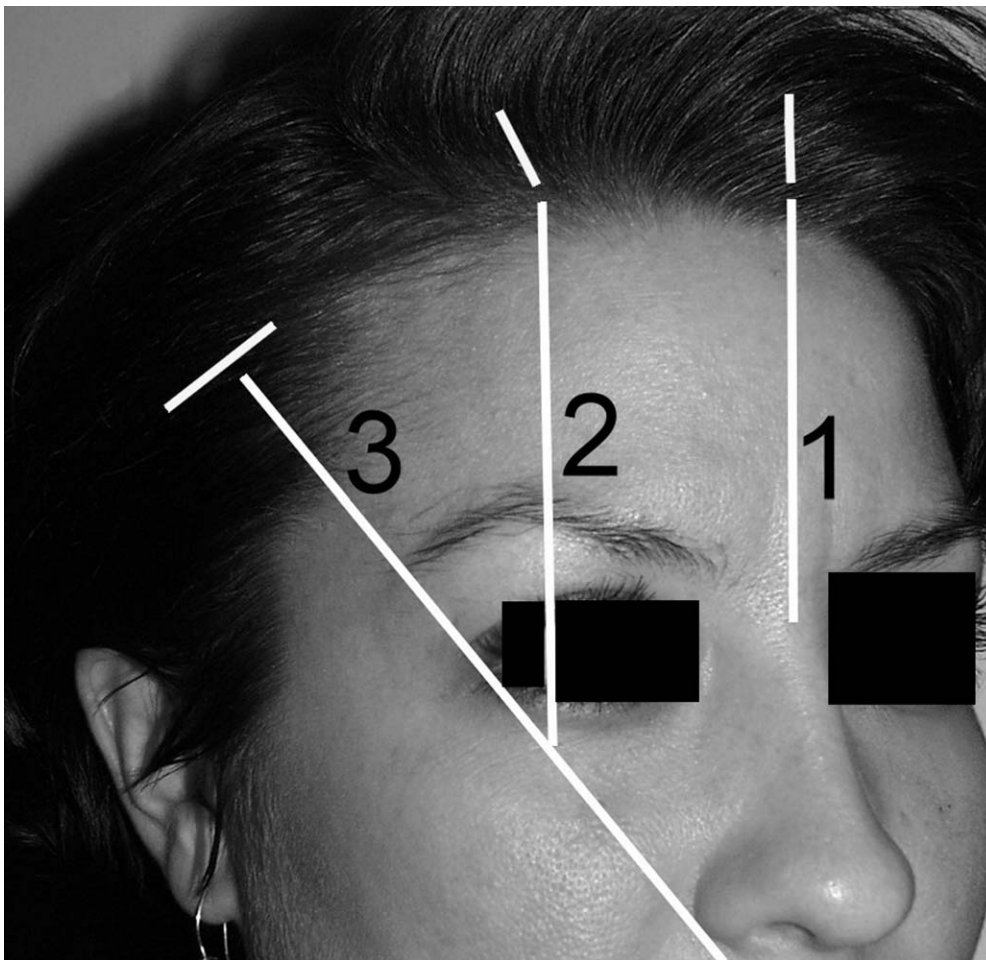


Fig. 1. The positions of the incisions for the endoscopic brow lift are illustrated by the yellow lines. Incision 1 is marked in the midline. Incision 2 is made in a line tangent to the lateral limbus of the eye, and incision 3 is made perpendicular to a line from the nasomalar groove to the lateral canthus.

aperture to the zygomaticotemporal suture, extending to the infraorbital rims. The frontozygomatic suture is also infiltrated with lidocaine 1:100,000 epinephrine from a transcutaneous approach.

The intraoral incision and midface dissection are performed first. The incision is similar to a maxillary osteotomy except that no midline incision is required (Fig. 2A). The second author

Box 1. Sites of incisions marked preoperatively

- A 1-cm midline incision 1.5 cm behind the central hairline.
- A 1.5-cm incision at the junction of the middle and outer thirds of the brow. This incision is usually tangent to the lateral limbus of the pupil. This incision will represent the area of maximum brow elevation and may differ in position from patient to patient.
- A 2-cm incision in the temporal hairline on a line perpendicular to the alarcanthal line. This incision lies caudal to the temporal crest. This incision lies caudal to the temporal crest.
- A vestibular subperiosteal incision is made 5 mm above the attached gingival from the canine tooth to the first molar bilaterally (see Fig. 2A).

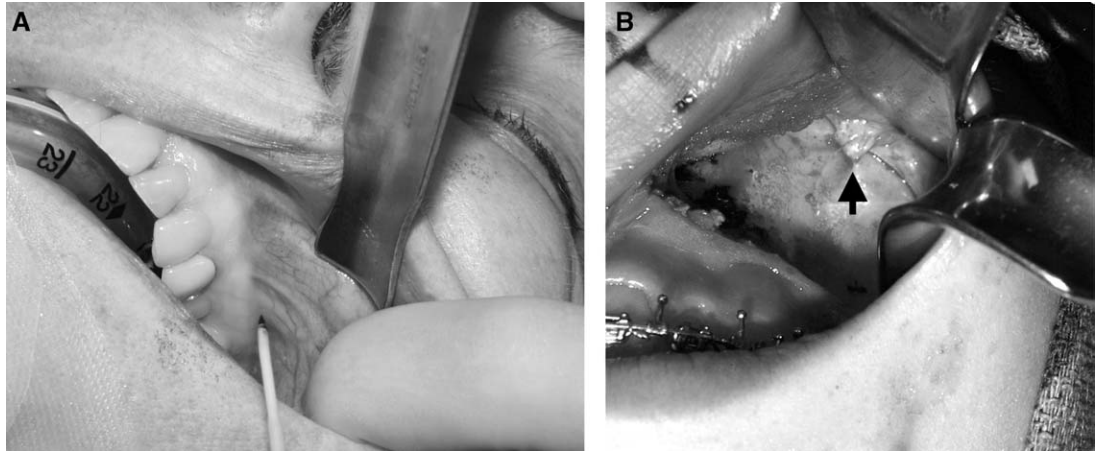


Fig. 2. (A) The incision for the midface dissection is made in the maxillary vestibule 3 to 4 mm above the mucogingival line. (B) The black arrow indicates the infraorbital nerve, which should be protected during this dissection.

prefers 4.0 MHz radiosurgery with a microneedle to make the intraoral incision, whereas the first author uses electrocautery. Using a periosteal elevator, subperiosteal dissection is performed from the piriform aperture (some practitioners do not extend to this area) to the attachment of the masseter tendon on the zygoma. In the cephalad direction, the dissection is extended to the level of the inferior orbital rim. Care should be taken to protect the infraorbital nerve (Fig. 2B). In addition, the elevator is used to dissect over the frontozygomatic suture with caution to stay in the subperiosteal plane to avoid frontal nerve injury. The frontozygomatic area includes an osteocutaneous retaining ligament (thought to correspond to McGregor's Patch), and it is easy to slip into the plane of the superficial temporal fascia, risking injury to the frontal branch of the facial nerve (cranial nerve VII; Fig. 3).

After the intraoral and midface dissection is completed, attention is directed to the brow. A No. 15 blade is used to make incisions in the scalp above the medial brows, above the brow height, and in the temporal scalp. Each incision is approximately 2 cm in length and approximately 0.5 cm behind the hairline. The right temporal incision is made perpendicular to the hairline, and mosquito forceps are used to dissect bluntly over the temporalis fascia. A blunt dissector is then used to widen this field of dissection over the entire temporalis fascia (Fig. 4).

The right middle incision (made above the brow height) is then made through periosteum, and a No. 9 periosteal elevator is used to release a subperiosteal plane over the forehead. The right midline incision is then made down through periosteum, and again, a periosteal elevator is used to release down to the midforehead. These same incisions are duplicated on the left side. An endoscopic brow dissector is then used to release a subperiosteal plane to the arcus marginalis. An arcus marginalis dissector is then used to release the arcus marginalis under endoscopic-guided vision. At this point, the continuous-wave carbon dioxide laser is used to release the periosteum at the arcus marginalis. It is also used to release and partially ablate the procerus and corrugator musculature (Fig. 5). This laser procedure is performed with the aid of an endoscopic camera so that the procerus and corrugator musculature can be carefully released in a curvilinear fashion well above the supraorbital nerves bilaterally (Fig. 6). Care must be taken, however, to maintain the subperiosteal release just below the brow, except in the area of the supraorbital nerve, or only the forehead and not the brow will be lifted. Next, completion of the frontozygomatic dissection from the temporal incision to connect a tunnel to the midface incision is performed (Fig. 7).

After completion of the soft tissue dissection, attention is turned to placement of anchoring screws. Monocortical drill holes are made with a 3-mm guarded drill bit. An anchor screw is placed in each of the lateral incisions at the junction of the middle and outer thirds of the brow. The authors prefer Lactosorb endobrow screws (Walter Lorenz, Jacksonville, FL), which require tapping the drill holes before screw placement (Fig. 8A, B). These screws are preferred because

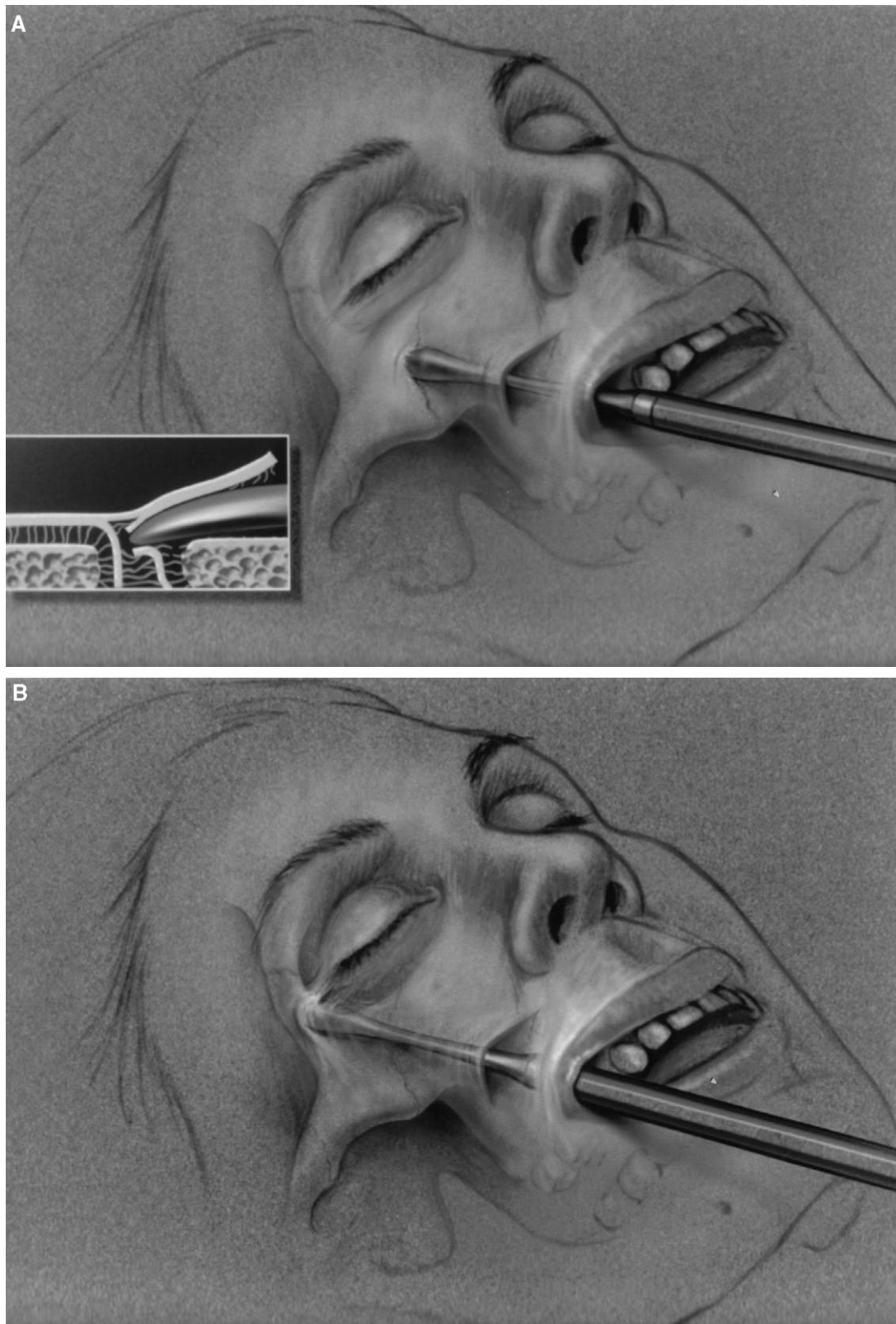


Fig. 3. (A, B) Schematic representations of the midface dissection. Maintaining the dissection in a subperiosteal plan minimizes the risk to the facial nerve in the area of the frontozygomatic suture (*inset*).

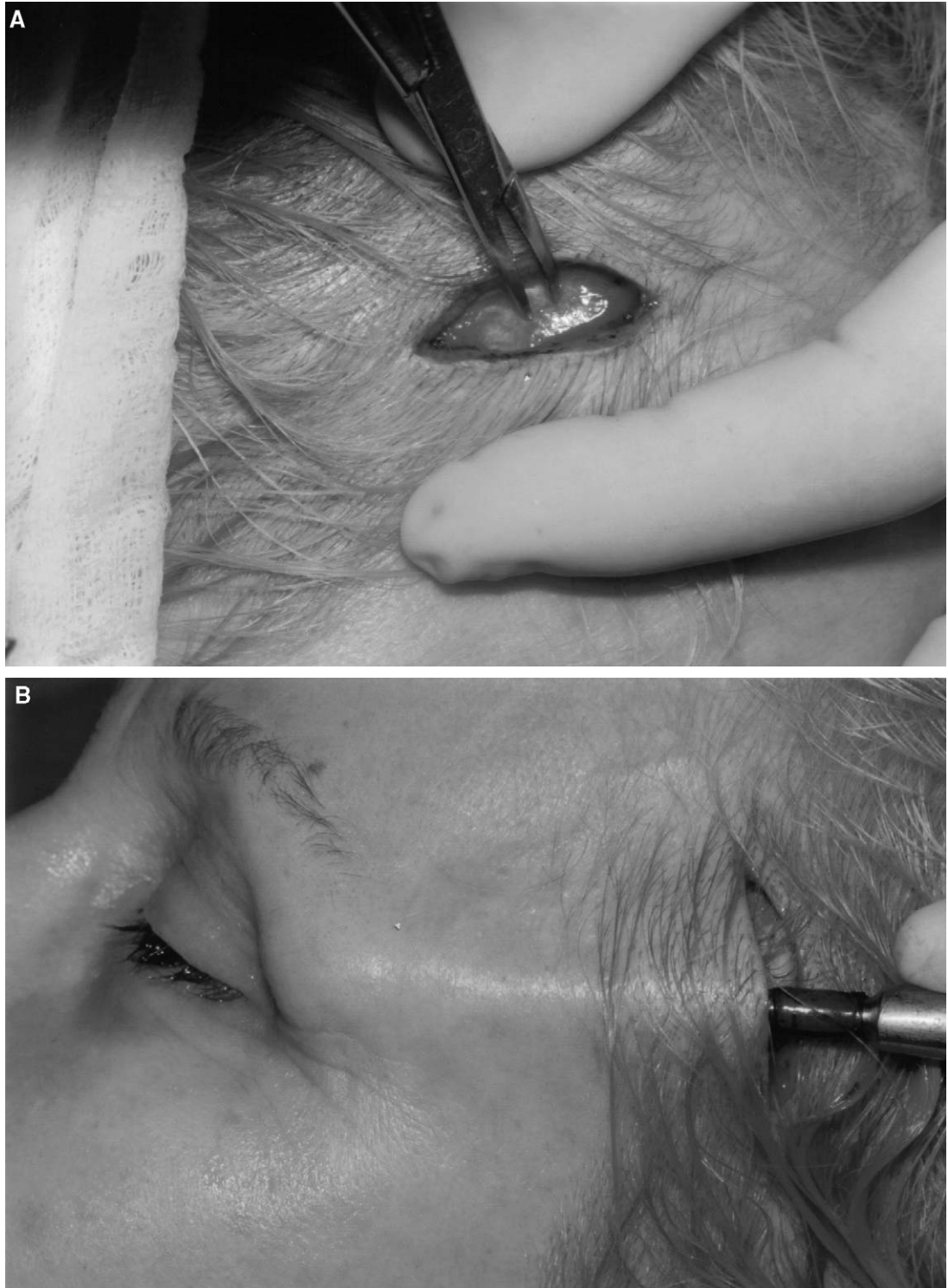


Fig. 4. (A) Dissection down to the temporalis fascia is completed with mosquito forceps. (B) A blunt dissector is used to widen this field of dissection over the entire temporalis fascia.

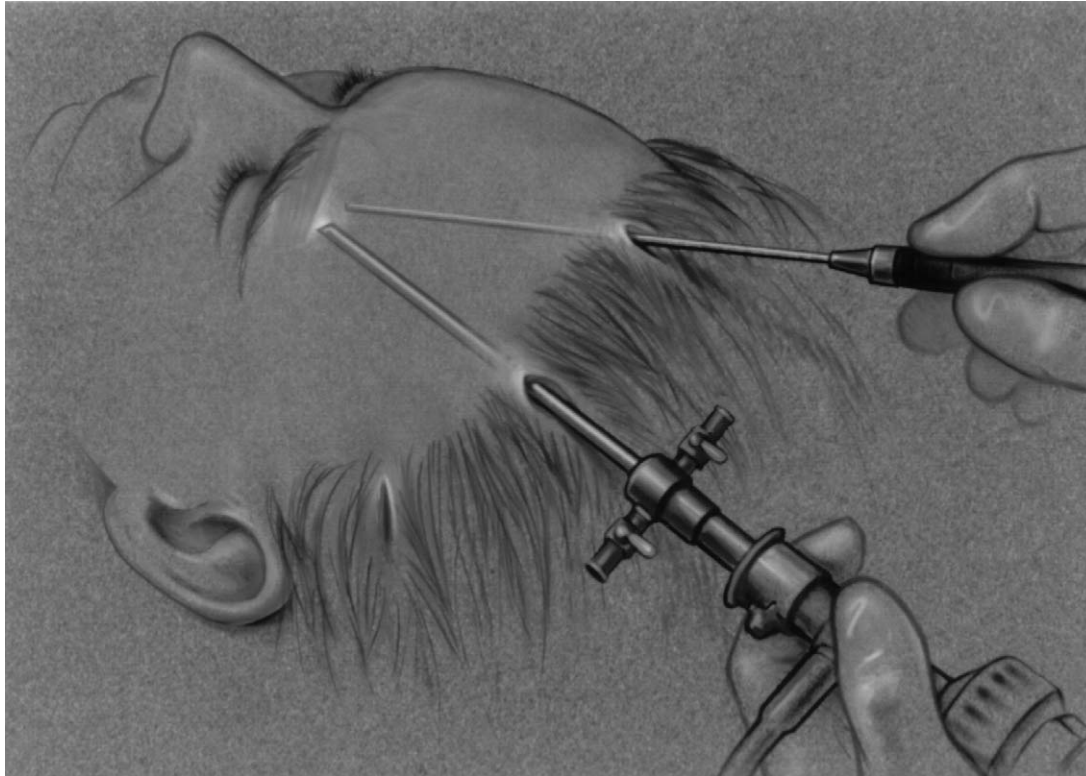


Fig. 5. Schematic representation of the use of endoscopic instruments for release of the arcus marginalis, procerus, and corrugator muscles.

they are resorbable and manufactured with a hole in the head of the screw allowing easy placement of the suspension sutures.

A stab incision is then made anterior to the lateral access incisions and to a depth just below the dermis of the skin, leaving the fascia intact. A 2-0 polydioxanone suture (PDS) is placed through the incision and through the Lactosorb screw, securing it with moderate amount of tension to complete the lift of the brow (Fig. 8C). Attention is then turned to the temporal incisions. Similar “stab” incisions are made parallel to the temporal incisions, and a 2-0 PDS suture is placed through each stab incision and secured posteriorly and superiorly in superficial layer of the temporalis fascia (Fig. 9). These sutures are secured with a moderate amount of tension to give lift to the midface. Resorbable sutures are then used to close each of the six endoscopic brow incisions, and 3-0 chromic suture is used to close the intraoral incisions. If indicated, simultaneous midface lifting can be combined with the endoscopic browlift by simply adding a suspension suture through the malar fat pads bilaterally. This suspension should be completed before temporal stabilization; the steps are illustrated in Fig. 10. The combination of minimally invasive endoscopic brow and midface lift can produce significant rejuvenation as shown in Fig. 11.

Discussion

The described technique has proved to be very successful in treating patients with moderate-to-severe aging affects of the brow and midface. Swelling and healing times are reduced, and the rejuvenation effects are lasting. As previously mentioned, intraoral subperiosteal dissection is an invaluable technique used in patients undergoing endoscopic browlifts, as is laser-assisted release of the periosteum at the level of the brow. The advantages of this subperiosteal vestibular

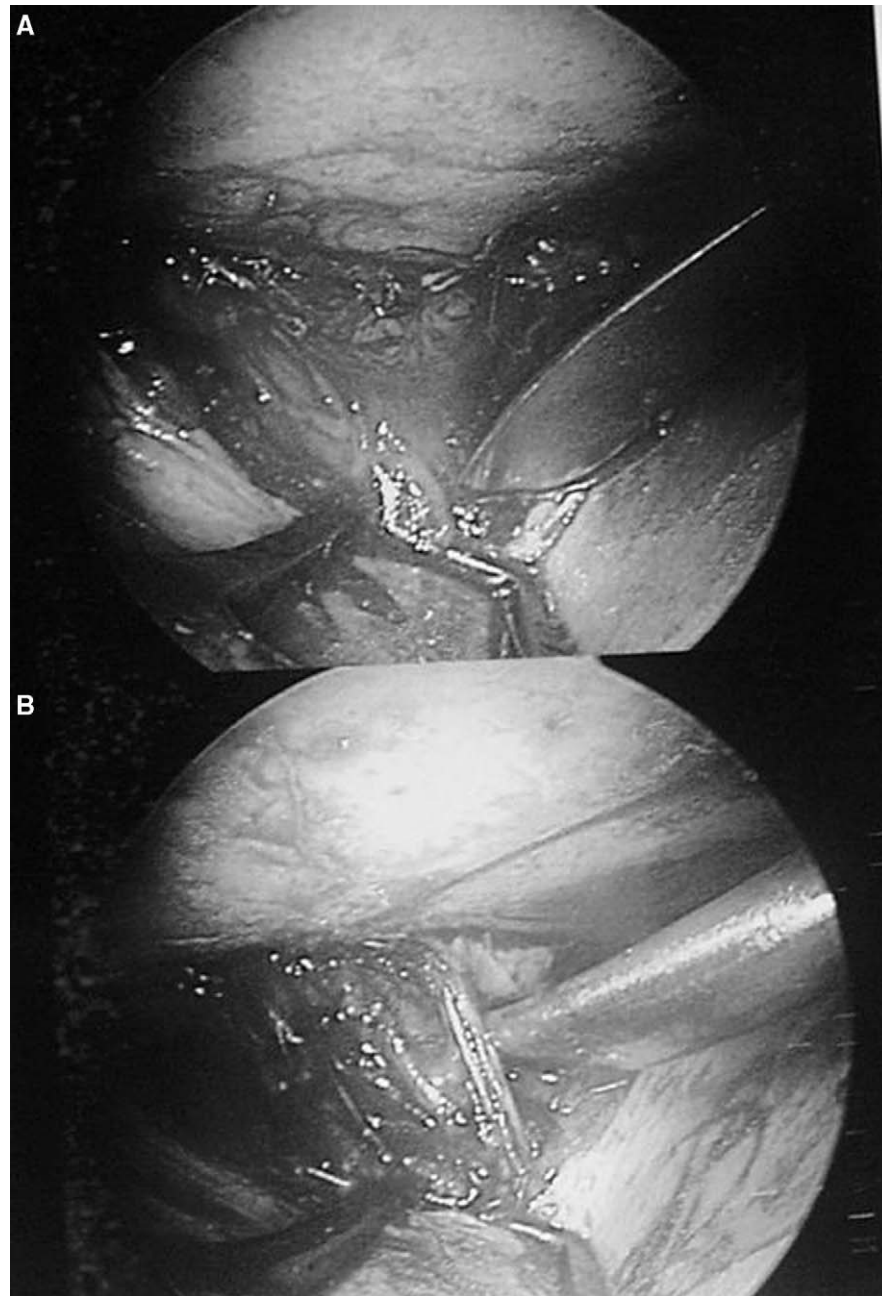


Fig. 6. Endoscopic view of the periosteal release just above the brow after laser incision. The top image shows the supraorbital nerve and the bottom image shows a back-action endoscopic elevator used to stretch the incision to further release the brow.

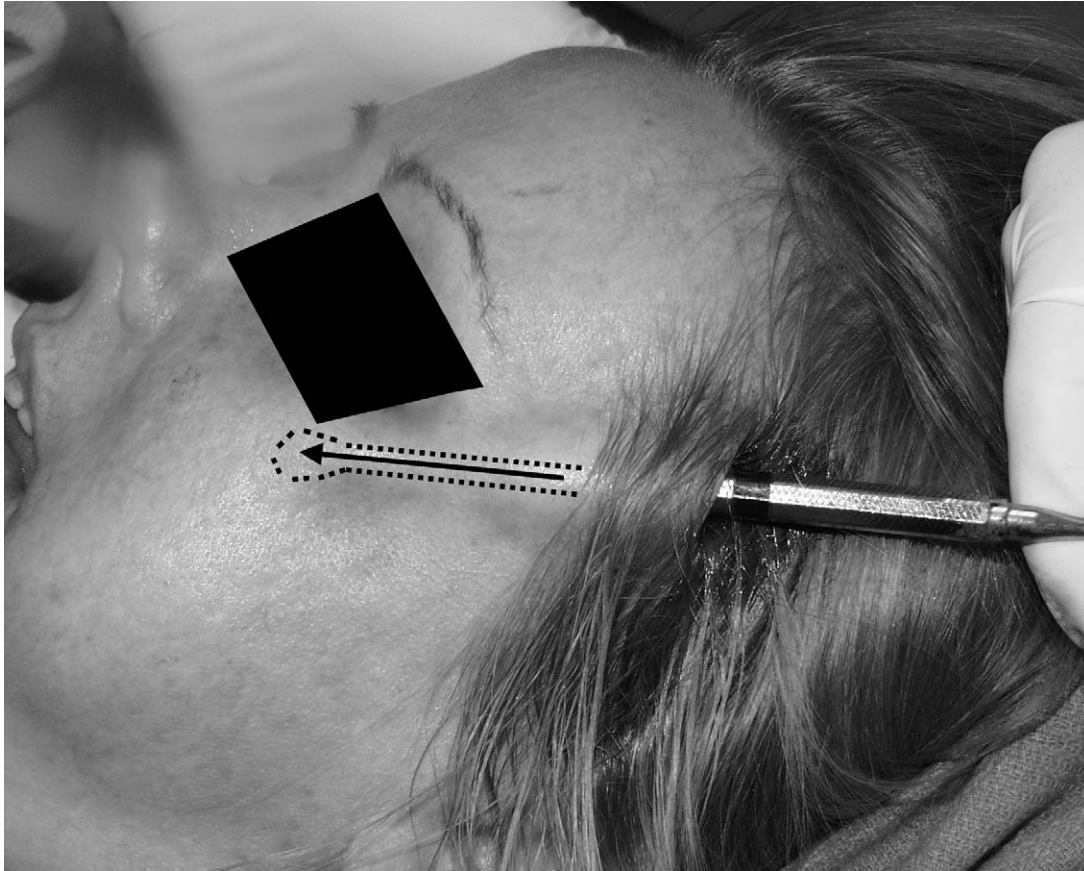


Fig. 7. The temporal and maxillary tunnels are connected from the temporal incision, completing the midface dissection.

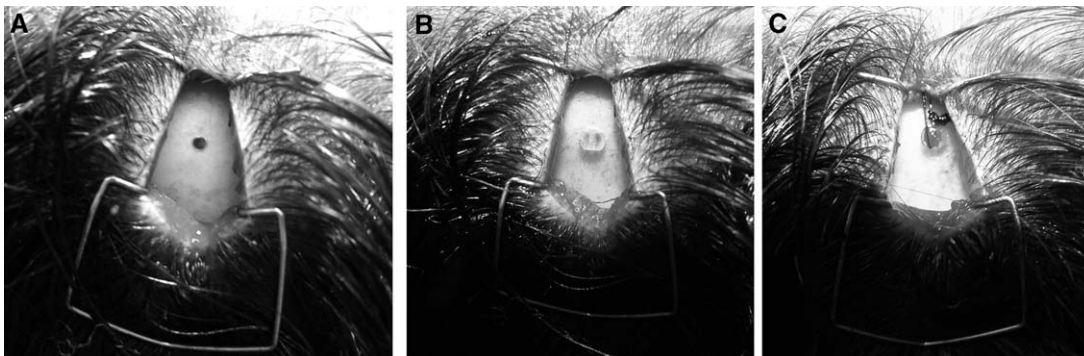


Fig. 8. (A) Monocortical drill hole, (B) the Lactosorb screw in position, and (C) the PDS suture fixation to the screw.

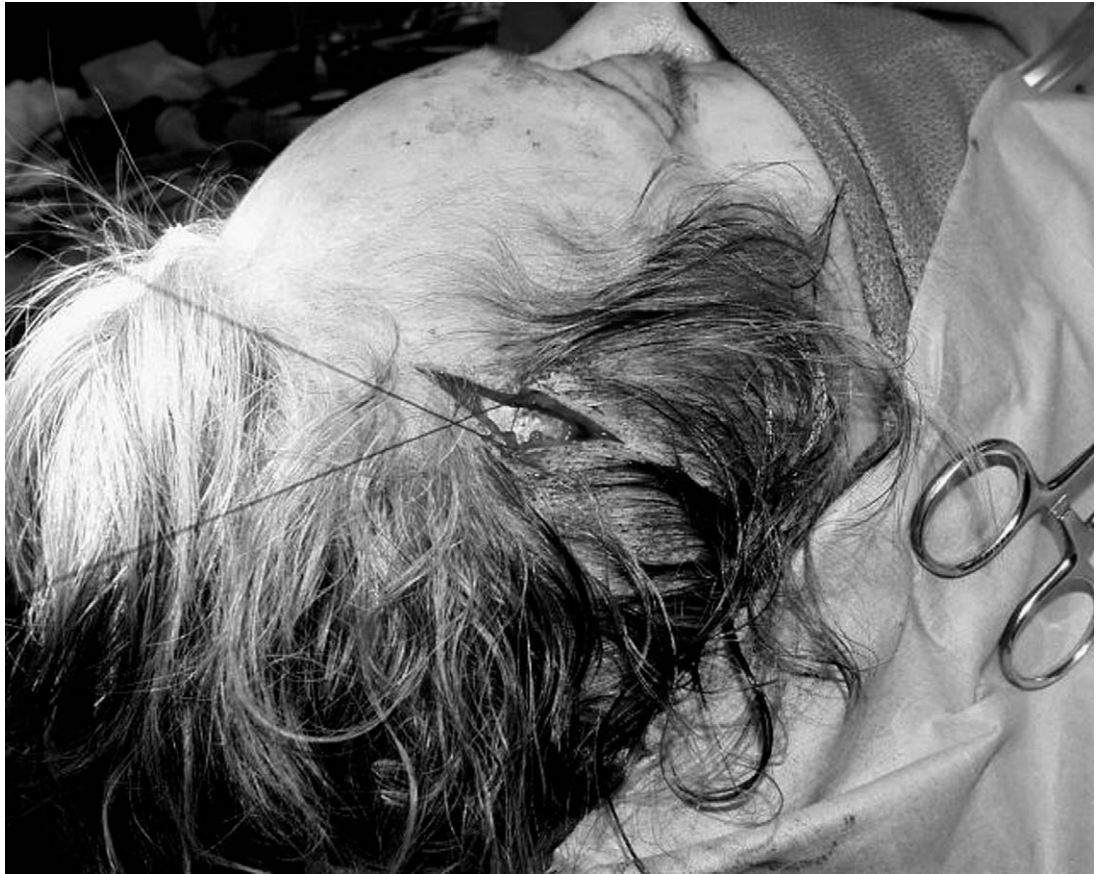

Fig. 9. Lift of the lateral forehead is accomplished by elevating and securing the inferior temporoparietal fascia to the superficial layer of the deep temporal fascia.

approach to the midface are improved elevation of the midface structures, improvement of the nasolabial folds, and enhancement of the cheek prominences. Proponents of the endoscopic technique claim that the limiting factor for eyebrow elevation is the periosteum and that a release of the periosteum would help elevate the brow. In addition to releasing the periosteum at the arcus marginalis, a subperiosteal release over the zygomatic buttress and lateral orbital rim decreases flap tension and contributes to the longevity of the result. The intraoral approach also allows for broad subperiosteal detachment of the masseter muscle to release the deep musculoaponeurotic system.

Summary

Improvements in technology have increased the level of patient care in all aspects of medicine and surgery. This is no less true in the area of cosmetic surgery. The use of endoscopy has led to improved aesthetics with respect to postoperative scarring, decreased healing time for patients, and an increase in overall patient satisfaction. Because the endoscopic brow and midface lift accomplishes the three primary goals of facial cosmetic surgery (restoration, rejuvenation, and enhancement) while adhering to the concepts of working from inside out and repositioning rather than excising, it could be concluded that there is no longer any indication for either the coronal or trichophyllic brow lifts. An argument could be made that a direct brow lift may be indicated in cases of extreme brow ptosis with deep frontal rhytids to allow concealment of the scar; however, even moderate-to-severe brow ptosis can be corrected endoscopically when deep forehead rhytids are not present.

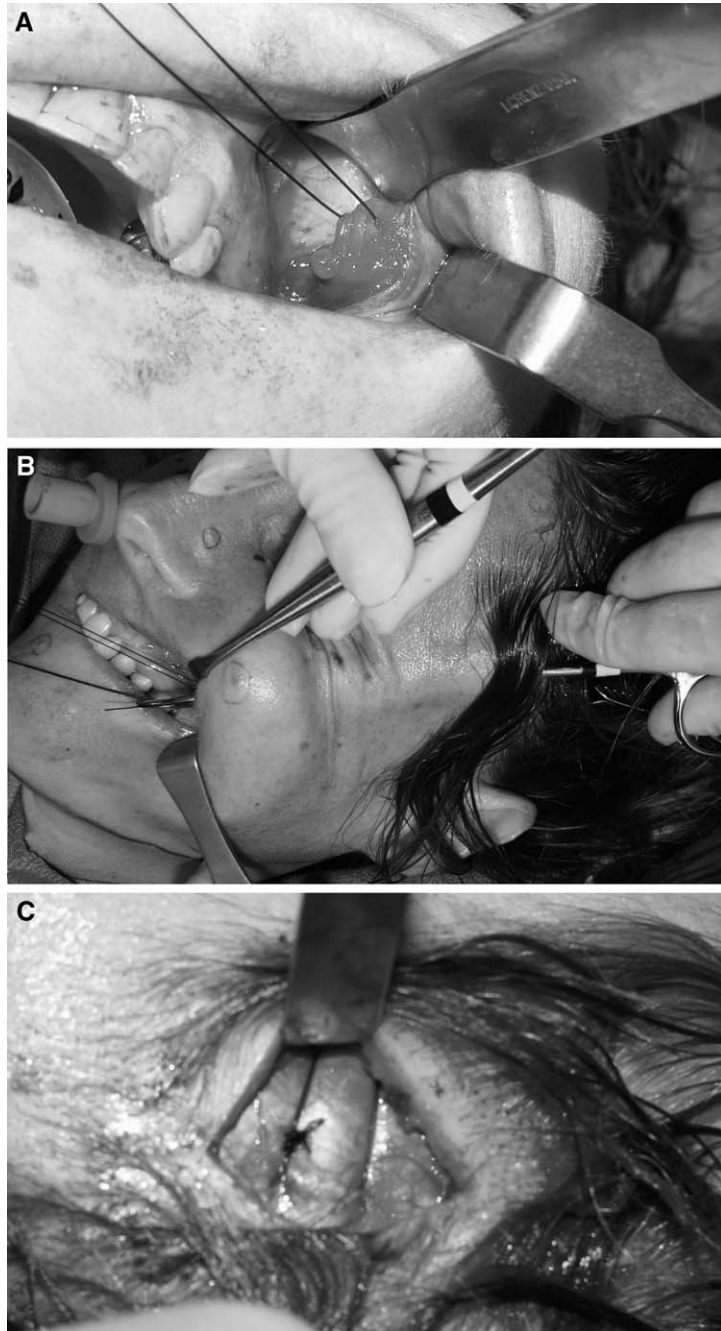


Fig. 10. The midface can be formally lifted efficiently with the following approach: (A) capture of the malar fat pad, (B) passing the suture superiorly through the subperiosteal tunnel, and (C) attachment to the deep temporal fascia, completing the midface suspension.

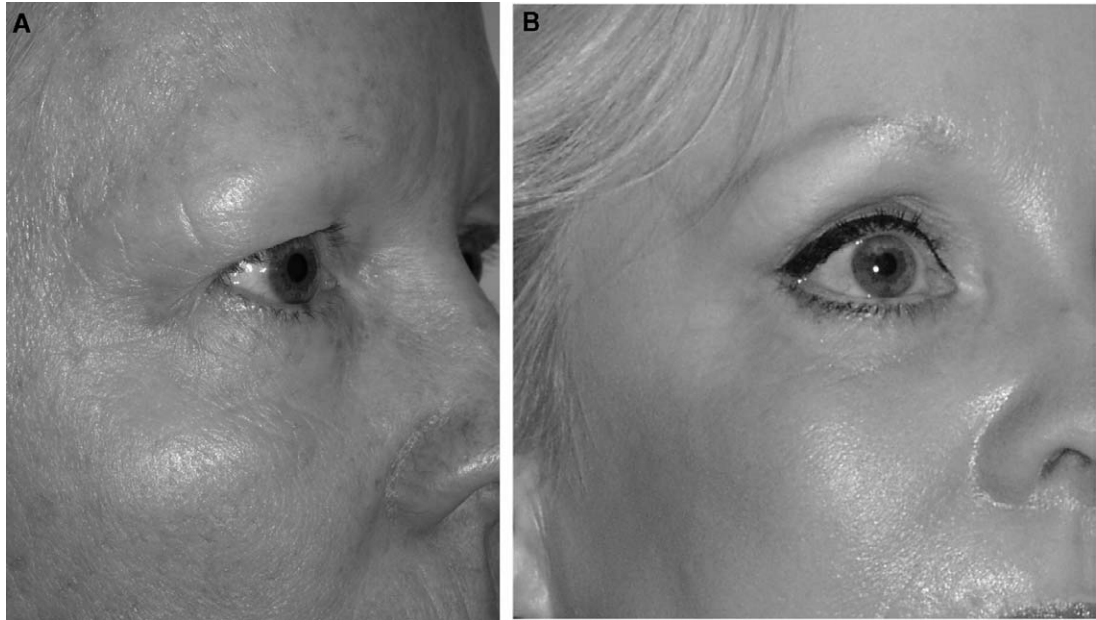


Fig. 11. Before (*left panel*) and after (*right panel*) images of a patient who had endoscopic brow and midface lift, lower transconjunctival blepharoplasty, and full-face carbon dioxide laser resurfacing. Note the improvement of the midface and decrease of the infraorbital tear trough deformity from the malar fat elevation.

Further readings

- Biggs TM. Some thoughts on fixation in endoscopic brow lift. *Plast Reconstr Surg* 2002;110:355–6.
- Chasan PE, Kupfer DM. Direct K-wire fixation technique during endoscopic brow lift. *Aesthetic Plast Surg* 1998;22:338–40.
- Daniel RK, Tirkanits B. Endoscopic forehead lift. Aesthetics and analysis. *Clin Plast Surg* 1995;22:605–18.
- Daniel RK, Tirkanits B. Endoscopic forehead lift: an operative technique. *Plast Reconstr Surg* 1996;98:1148–57.
- Freund RM, Nolan WB III. Correlation between brow lift outcomes and aesthetic ideals for eyebrow height and shape in females. *Plast Reconstr Surg* 1996;97:1343–8.
- Hamas RS. Endoscopic management of glabellar frown lines. *Clin Plast Surg* 1995;22:675–81.
- Hamas RS. How to handle rigid endoscopes in office surgical facilities. *Plast Reconstr Surg* 1996;98:574–5.
- Hamas RS. Reducing the subconscious frown by endoscopic resection of the corrugator muscles. *Aesthetic Plast Surg* 1995;19:21–5.
- Hamas RS, Rohrich RJ. Preventing hairline elevation in endoscopic browlifts. *Plast Reconstr Surg* 1997;99:1018–220.
- Hobar PC, Flood J. Subperiosteal rejuvenation of the midface and periorbital area: a simplified approach. *Plast Reconstr Surg* 1999;104:842–51.
- Hwang IP, Pratt DV, Jordan DR. Cerebrospinal fluid leakage during endoscopic forehead lifting. *Am J Ophthalmol* 1999;128:531–2.
- Isse NG. Endoscopic facial rejuvenation. *Clin Plast Surg* 1997;24:213–31.
- Isse NG. Endoscopic facial rejuvenation: endoforehead, the functional lift. Case reports. *Aesthetic Plast Surg* 1994;18:21–9.
- Isse NG. Endoscopic forehead lift. Evolution and update. *Clin Plast Surg* 1995;22:661–73.
- Kennedy BD, Pogue MD. Fixation techniques for endoscopic browlift. *J Oral Maxillofac Surg* 1999;57:588–94.
- McKinney P, Sweis I. An accurate technique for fixation in endoscopic brow lift: a 5-year follow-up. *Plast Reconstr Surg* 2001;108:1808–10.
- Nassif PS, Kokoska MS, Homan S, et al. Comparison of subperiosteal vs subgaleal elevation techniques used in forehead lifts. *Arch Otolaryngol Head Neck Surg* 1998;124:1209–15.
- Romo T III, Sclafani AP, Yung RT, et al. Endoscopic foreheadplasty: a histologic comparison of periosteal refixation after endoscopic versus bicoronal lift. *Plast Reconstr Surg* 2000;105:1111–7.
- Sozer O, Biggs TM. Our experience with endoscopic brow lifts. *Aesthetic Plast Surg* 2000;24:90–6.
- Withey S, Witherow H, Waterhouse N. One hundred cases of endoscopic brow lift. *Br J Plast Surg* 2002;55:20–4.