

Rejuvenation of the Lip and Perioral Areas


Joe Niamtu III

It would have been a lot easier to write this chapter 10 years ago, as there were significantly fewer options available for lip and perioral enhancement in the mainstream armamentarium of the cosmetic surgeon. Collagen and fat injections, cutaneous dermabrasion for wrinkles, and some selected surgical lifting procedures generally summed up the available options. The introduction of CO₂ laser resurfacing in the early 1990s and the US Food and Drug Administration (FDA) approval of Restylane (Medicis Inc, Flagstaff, AZ) were landmarks in treatment options. Much has happened in a short time, and the remainder of this chapter will deal with this exponentially expanding arena.¹⁻¹¹

societies still go to great lengths to draw attention to the lips (Figure 2-2). It can be said that the lips are the only exposed sexual organ in our contemporary society, although in some societies this facial region is covered for modesty per local religious customs. Historically, full lips have come in and out of fashion. Pictures of movie stars from the 1940s and 1950s reveal that the use of dark lipstick with large lips was fashionable in that period. Moving ahead a decade or so into the 1960s, lips were seen to be often deemphasized with clear or gloss lipstick. Big voluptuous lips are currently back again and will continue to come in and out of fashion. I personally believe that the other reason that lip enhancement has become so popular is the fact that the baby boomers have entered their fifth decade and are driving cosmetic surgery. More women are in the

workplace and have discretionary income to spend as they please. In addition, minor cosmetic enhancements are no longer a stigma. In the 1960s, a Clairol hair color advertisement stated, “Only her hair dresser knows for sure,” as if coloring one’s hair was a secret of the universe! Today, many women have multicolored hair and brag about it! In celebrity circles, it has become fashionable to brag about cosmetic procedures, and the entire experience has come out of the closet. With the advent of Botox (botulinum toxin A; Allergan Inc, Irvine, CA) and other “lunchtime” procedures, minimally invasive cosmetic enhancements have become a cottage industry for many specialties. Who is better trained to deal with the lips than oral and maxillofacial surgeons? Few specialties have as much experience in treating the lips and perioral areas,

1 Over the millennia, women have been accentuating their lips for purposes of beauty, courtship, and sexuality (Figure 2-1). Some



22 **FIGURE 2-1** Humans have adorned their lips for as long as there has been recorded history.

FIGURE 2-2 The lips play an important part in beauty, courtship, and mating. Some cultures go to extreme measures to accent the lips.

2 Diagnosis and Treatment Planning

and cosmetic rejuvenative options can be a mainstream part of our practices.

Lip Anatomy

An esthetic lip means different things to different people, as beauty is in the eye of the beholder. Statistically and artistically, the upper lip consists of one-third of the total lip volume, and the lower lip, being larger, consists of two-thirds of the lip mass (Figure 2-3).

The esthetic upper lip has a “lazy M” configuration at the vermilion–cutaneous junction, commonly referred to as “Cupid’s bow” (Figure 2-4). This junction has a “white roll,” which is a defining outline and the result of light reflection from this area. The lower lip is more curvilinear and also frequently has a similar white roll. The other defining feature of the upper lip is the philtral complex, which consists of the philtrum and the philtral columns. This area is frequently overlooked when performing esthetic lip augmentation.

In youth, the perioral skin is smooth, and nasolabial folds are minimal until the third decade. Females frequently develop “lipstick lines” that manifest as vertical rhytids radiating

outwards from the vermilion–cutaneous junction. These lines are frequently accentuated in smokers and are not usually seen in males, presumably from the presence of hair follicles in the area. Females disdain these lines, not only from the cosmetic aspect of looking old, but also because lipstick tends to run outwards from the lines, producing an undesirable appearance.

As people age, the lips undergo atrophy for multiple reasons. The effects of gravity and actinic damage coupled with the decreased vertical dimension resulting from enamel tooth wear often produce changes in the lips that make them seem to disappear (Figure 2-5). The skin at the commissures begins to sag, and the formation of mandibulolabial folds causes depressions at the corners of the mouth, which are often referred to as marionette lines. The descent of the malar fat pads coupled with the loss of perioral volume and deepening of the nasolabial folds shape the aging midface.

Treatment Options for the Lips and Perioral Areas

Today’s facial surgeons have more options than ever before to rejuvenate the perioral area. For decades, bovine collagen was the standard of care for facial and lip fillers. It is a product that was generally well suited for augmentation but presented significant drawbacks. First and foremost is the fact that it is an animal-derived substance and can cause allergy reactions, thus preinjection testing is a necessity. Second, it does not last long, frequently being resorbed within 4 to 6 weeks. Alternate fillers with obvious advantages have been used in other countries for decades but were slow to gain FDA approval. In December 2002, the hyaluronic acid-based filler Restylane gained FDA approval and began the revolution in new fillers. Restylane is hyaluronic acid and is derived from bacterial fermentation. Since it is a natural

resident of many body tissues, allergic reaction is quite rare and is usually related to protein loads from the bacterial processing. The other huge advantage is the fact that studies have shown Restylane to last as long as 8 months.¹¹ This longevity is related to a process termed isovolumic degradation (Figure 2-6).

As the hyaluronic acid molecules become phagocytized, water is drawn into the molecule from the surrounding tissue, thus replacing the lost molecular volume. For this reason, the hyalurons last longer in vivo and have become the filler of choice for most practitioners.

Sculptra (poly-L-lactic acid; Dermik Aesthetics, Bridgewater, NJ) has received FDA approval for the treatment of lipoatrophy in human immunodeficiency virus (HIV) patients. Antiretroviral medications have greatly improved the survival of HIV patients but cause atrophy of facial fat, especially in the midface and temporal regions. Sculptra comes packaged as a solid that must be diluted with saline 24 hours before injection (Figure 2-7).

Unlike most other fillers, Sculptra does not provide immediate augmentation. When the poly-L-lactic acid particles are injected, an inflammatory response is initiated and results in the formation of new collagen in the area. This process usually takes 3 to 4 weeks and the effects can last

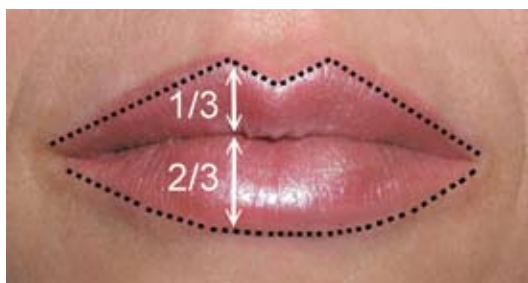


FIGURE 2-3 The upper lip is smaller than the lower lip and represents one-third of the total lip volume.

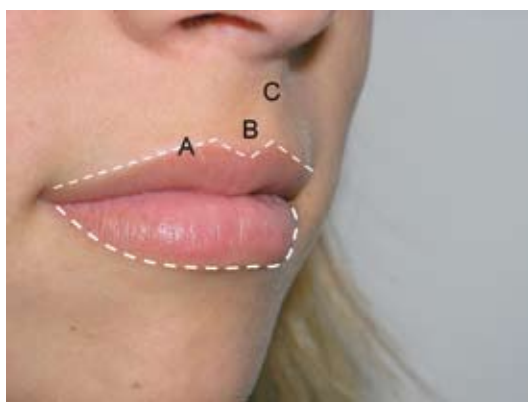


FIGURE 2-4 Defining features of esthetic lips. The “lazy M” of the upper lip and the curvilinear outline of the lower lip are shown by the broken lines. A = white roll; B = philtrum; C = philtral column.

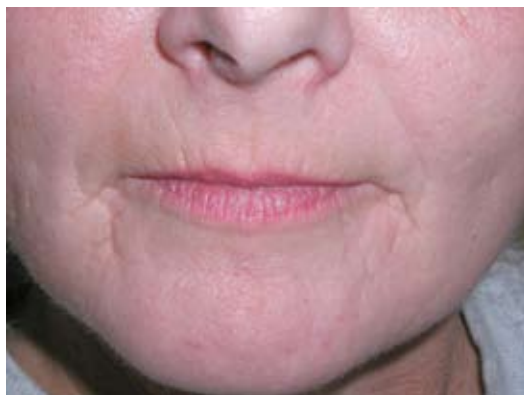

FIGURE 2-5 The senescent changes of the lips and perioral area are manifested by loss of lip volume and skin changes from aging and sun damage.



FIGURE 2-6 Process of isovolumic degradation. Water molecules are drawn into the hyaluronic acid complex as the product is naturally degraded; thus the molecule retains its shape and fullness over the degradation process.

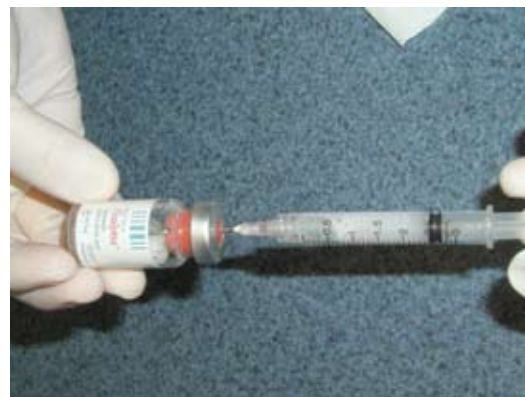

FIGURE 2-7 Sculptra consists of L-poly-lactic acid and requires premixing prior to injection.

4

3

23

1 to 2 years. As of the time of writing this chapter, Sculptra is only FDA approved for the treatment of HIV-associated lipoatrophy.

5 Most maxillofacial surgeons are well experienced in the use of hydroxyapatite (HA) for hard tissue grafting. Radiesse (Bioform Biomedical, San Mateo, CA) contains HA particles of 25 to 125 microns in an aqueous gel and is FDA approved as a radiographic marker and a filler for vocal cord abnormalities. It is used off-label to augment facial wrinkles, folds, and lips. Because of the calcific nature of HA, the product can last for 12 to 18 months. In my opinion, it is a filler that is best used by experienced injectors as it is very technique sensitive. Improper injection techniques can result in lumpy areas. Again, the fact that some fillers last a long time can be an advantage, but in terms of complications, this can be a distinct disadvantage. Figure 2-8A shows Radiesse being injected, and Figure 2-8B shows a before and after image of Radiesse augmentation of the nasolabial folds. This filler is generally injected in the immediate subdermal (superficial subcutaneous) area.

7 Fat has been used as an injectable filler for the past 100 years. It has fallen in and out of favor, but recent techniques popularized by Coleman had initiated renewed interest in fat use.¹⁰ The development of tumescent local anesthesia has popularized and simplified fat harvesting and injection.^{2,4,8} Fat injection has multiple advantages. It is readily available in most patients, is a natural tissue, and has the feel of native tissue when injected. Various techniques exist for fat harvest and injection. I inject tumescent local anesthesia (0.1% lidocaine and 1:1,000,000 epinephrine) in the periumbilical region and wait for 15 minutes. A 10 cc syringe with a harvesting cannula is used to harvest the needed amount of fat from a stab incision in the umbilicus. The fat is harvested in the immediate subcutaneous area. Volumes from 10 to 90 cc of fat are typically harvested at a single session. The fat can be centrifuged, although I prefer to allow gravity to separate the supernatant from the fat. The fat is emulsified by pushing it back and forth between two 10 cc syringes coupled with a female–female Luer-Lock connection until the fat becomes a creamy consistency. The fat is then injected in the face and/or lips in various tissue planes. In order to provide vascularity to nourish the harvested adipocytes and to slow resorption, the fat is injected in deep, intermediate, and superficial tissue planes. It can be injected with dedicated blunt cannulas (Coleman Fat Injection Cannulas, Byron Medical, Tucson, AZ) or simply with an 18 gauge needle. Care must be taken when injecting fat (or any filler, for that matter) in order to avoid inadvertent intravascular injection. Blindness has been documented with fat and filler injections,

8 especially in the upper face and periorbital areas. Although many theories exist, I feel that some adipocytes will survive and become viable, and much of the injected fat will be resorbed over time. For this reason, multiple injection sessions may be required to obtain a lasting result. Excess fat can be frozen at the time of harvest and injected later, or multiple harvesting and injection sessions can be performed. Since the fat will invariably resorb, overcorrection is usually performed

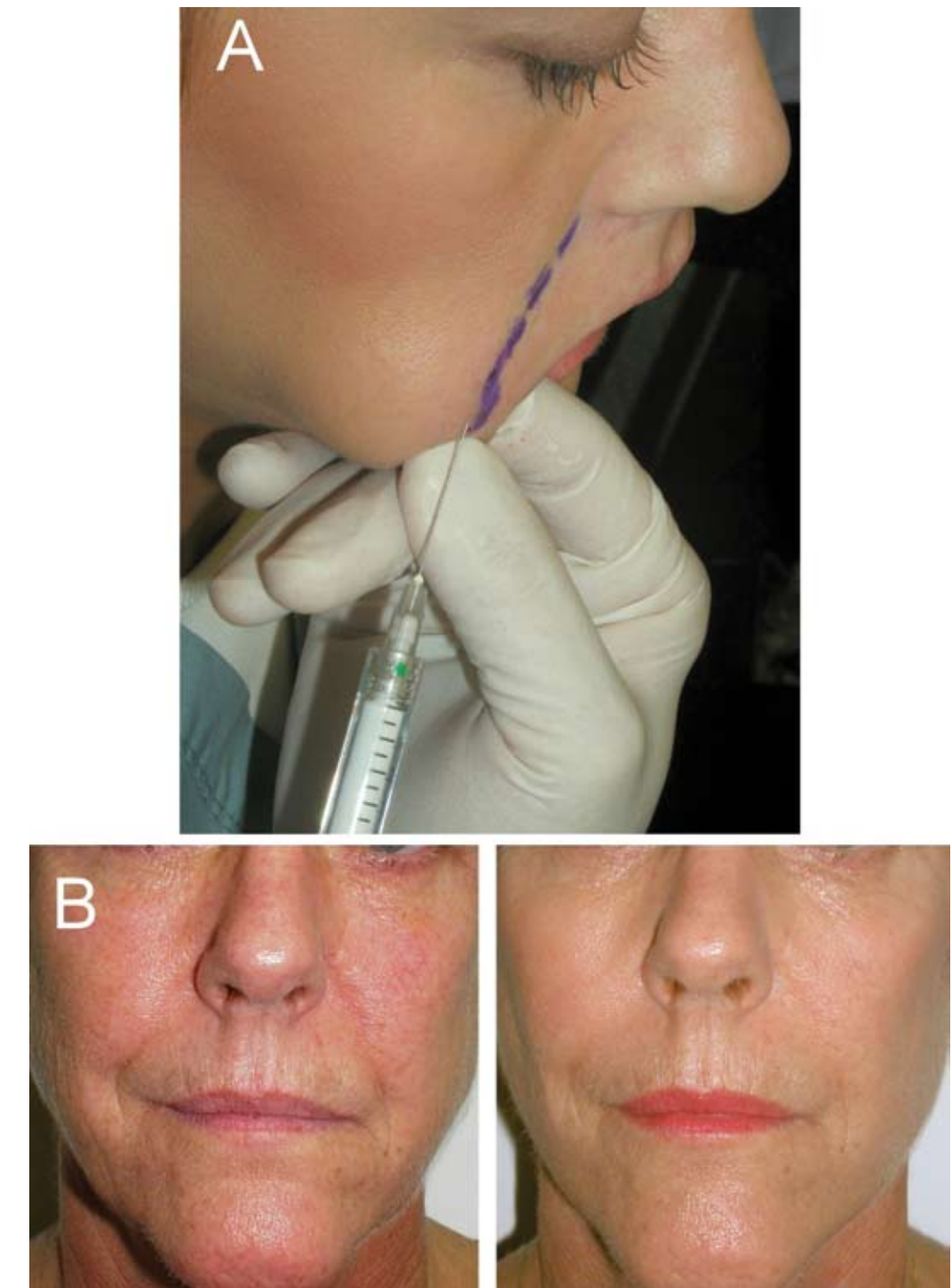


FIGURE 2-8 A, Radiesse being injected into the subcutaneous plane in the nasolabial fold. B, Before and after image of a patient injected for nasolabial improvement with Radiesse.

especially in the upper face and periorbital areas. Although many theories exist, I feel that some adipocytes will survive and become viable, and much of the injected fat will be resorbed over time. For this reason, multiple injection sessions may be required to obtain a lasting result. Excess fat can be frozen at the time of harvest and injected later, or multiple harvesting and injection sessions can be performed. Since the fat will invariably resorb, overcorrection is usually performed

when injecting. This produces a relative cosmetic deformity and may take up to several weeks to look normal.

Figure 2-9 shows a young male patient who had undergone radiation treatment for a malignant orbital tumor in childhood. The radiation stunted the temporomandibular joint and facial growth on the right side. The patient was treated with fat that was harvested from the abdomen and injection into the face (Figure 2-10).

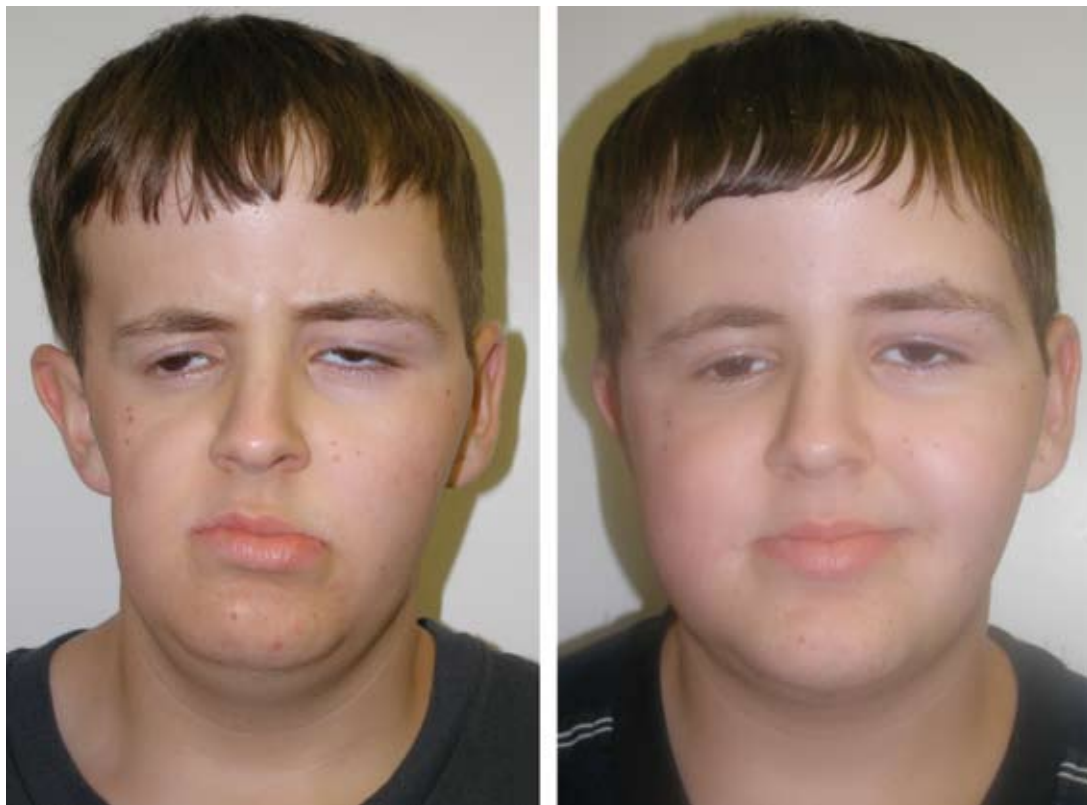

FIGURE 2-9 A young male patient who had undergone radiation treatment for a malignant orbital tumor in childhood, stunting the temporomandibular joint and facial growth on the right side. The patient was treated with a single session of 100 cc of harvested fat from the periumbilical region.

Silicone is a filler that has also fallen in and out of favor for facial and lip augmentations. It has been used in a nonscientific manner for years by professionals and, unfortunately, also by nonprofessionals. Early techniques used such additives as olive oil, and nonmedical-grade silicone for machine lubrication was also injected. Although the FDA performed multiple studies, the studies were poorly controlled and provided little to advance silicone as a safe filler. The injection of large amounts (lakes) of silicone in the tissues and the problems encountered with breast implants largely caused silicone to fall out of favor with most injectors. When large amounts of silicone are injected, they are known to migrate to distant sites via tissue planes. This problem, coupled with foreign body giant cell reactions and even tissue necrosis, caused the FDA to outlaw the use of injectable silicone in the 1980s. Finally, several liquid injectable silicone preparations were approved by the FDA as a tamponade treatment with retinal detachment. Silikon 1000 (purified polydimethylsiloxane) is a highly purified long-chain polydimethylsiloxane trimethylsiloxy-terminated silicone oil marketed by Alcon Laboratories (Fort Worth, TX). The viscosity of liquid injectable silicone is measured in centistokes (cs). One centistoke is the viscosity of water. A liquid of 1,000 cs (Silikon 1000) has the viscosity of honey. Those practitioners who have used

injectable silicone for decades will argue that no better filler exists. Silicone is a thick gel and feels extremely soft and natural when injected. It is a permanent filler and when used correctly provides excellent results. When a filler is classified as permanent, one must keep in mind that although the actual filler material may persist, aging, ptosis, and continued actinic damage will continue with the aging process in any given area. Tough lessons have been learned in terms of injecting large volumes of silicone into the tissues and the process is contraindicated. The proper method for silicone injection is the microdroplet technique. Microdroplets (0.01 cc) of liquid injectable silicone are placed in the subdermal plane. Small amounts of silicone (0.1 cc per lip quadrant) are injected in these tiny microdroplets. The body will form reactive collagen around the microdroplets and wall them off, which produces the augmentation and keeps the silicone at the injection site. These small amounts of silicone are injected on a monthly basis until the desired results are obtained. In actuality, the treatment is stopped short of the desired result, as continued collagen will continue to form. This treatment is not an immediate phenomenon and may take 3 to 9 months to achieve a result. Silicone is injected as a facial filler for off-label use. Figure 2-11 shows silicone injected into the nasolabial area of a patient with HIV-associated lipoatrophy. I would

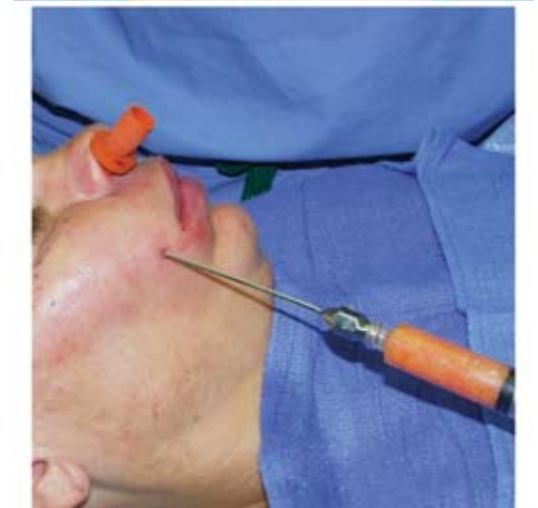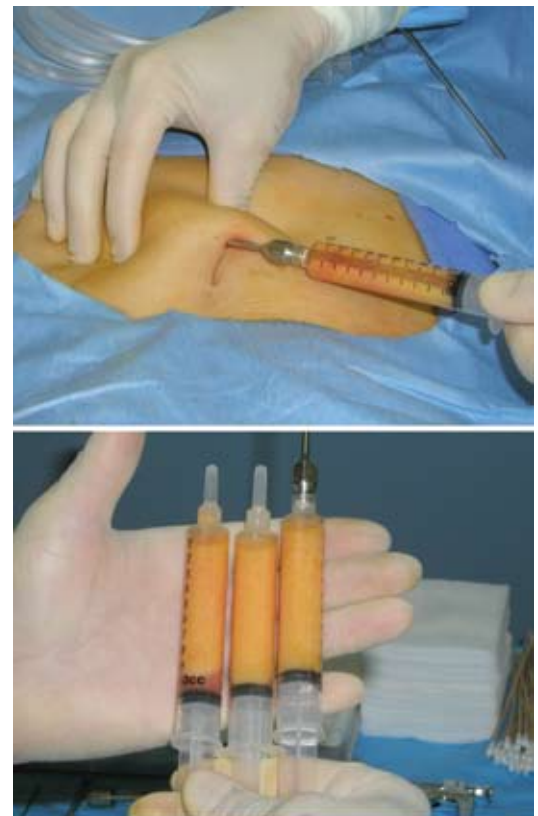


FIGURE 2-10 The periumbilical region is a favored region for fat harvest (top photo). The harvested fat is decanted or centrifuged in syringes to separate the fat from other fluids (middle picture) and then is injected into the facial tissues in multiple tissue planes.

caution any injector to carefully consider the use of silicone as a facial filler, as any complication would result in significant collegial criticism. It should be used by only the most experienced injectors, and it is never a mainline treatment for a patient who has never had fillers. Being an FDA-approved product with an off-label use, it is illegal to advertise cosmetic silicone injections, and its use must be consistent for the product. Lipoatrophy in HIV patients would be an example of an accepted indication. The liquid injectable silicone

is drawn from the vial with an 18 gauge needle and injected with a 25 to 30 gauge needle. It is important for the injector to keep his/her finger off the syringe plunger when going in and out of the skin so that the silicone is not inadvertently deposited in the epidermis, which will cause fibrous bumps. Figure 2-11A shows a silicone injection in the nasolabial folds of a patient with HIV lipoatrophy from antiretroviral drugs, and Figure 2-11B shows the silicone vial and injection syringe.

Human Collagens

Human cadaveric collagens such as Dermalogen (Collagenesis Inc, Beverly, MA), Cymetra (LifeCell Corporation, Branchburg, NJ), Fascian (Fascia Biosystems, Beverly Hills, CA), and Alloderm (LifeCell Corporation, Branchburg, NJ) were introduced and used but have fallen out of favor for newer fillers.

Isolagen (Isolagen Inc, Houston, TX) is a filler made from cultured autologous fibroblasts. A punch biopsy is harvested from the posterior auricular area and sent to the company for fibroblast tissue culture. Again, this product is not significant in the filler marketplace. Although the product came from the actual patient, the need to harvest, send off, culture, resend, and inject appears to be too much of a process for the average injector and doctor.

Combination Fillers

Artecoll (Artes Inc, San Diego, CA) is a filler consisting of 30 to 42 micron polymethylmethacrylate (PMMA) beads in a bovine collagen vehicle. This product has been used in Europe since 1994 and is currently under FDA investigation to be marketed as Artefill in the United States. The allure of this filler is the fact that it is permanent.

I feel that permanent fillers can have permanent complications, and these fillers should be used very judiciously and only by very experienced injectors.

Dermalive and Dermadeep (Euromedical Systems, Ltd, UK) are fillers that have been used in Europe since 1998. These products are semi-permanent biphasic implants that consist of a fluid carrier and a solid phase in a 60% (hyaluronic acid) and 40% (nonresorbable acrylic hydrogel) volume, respectively. After injection, the hyaluronic acid resorbs first, and then the hydrogel particles become encased in new collagen and endure for up to 12 months. This product is currently not FDA approved.

The extensive and ever-expanding armamentarium of facial fillers will continue to present treatment options for doctors and patients. What is more important than the actual filler used are the techniques of injection and the results. Some fillers work better in the hands of some doctors, and one should adhere to what works for one's patients.

Techniques of Filler Injection

Anesthesia

Pain control is important in any practice, but especially in an elective cosmetic practice where patients do not really have life-threatening reasons to be there in the first place. The injection of fillers is performed in different ways by different doctors. Almost everyone uses topical anesthesia, but the use of local anesthesia is variable. Personally, I use local anesthetic blocks or infiltrations for all lip enhancements but not usually for skin injection unless the patient's skin is sensitive to topical anesthetics.¹²⁻¹⁹ On presentation, the patient is put in a consult room and topical anesthesia is applied. We prefer a combination of 20% benzocaine, 6% lidocaine, and 4% tetracaine and

purchase this product from Bayview Pharmacy, Baltimore, MD.

If the patient is scheduled for nasolabial fold or skin wrinkle augmentation, no additional anesthesia is used unless the patient is too uncomfortable. For lip injection, I use infraorbital and mental nerve blocks or, more commonly, local anesthetic infiltration in the upper or lower anterior vestibule from cupid to cupid region. This usually provides adequate local anesthesia for treating the lips.

Treatment Decisions

Experienced patients may know exactly what they want in terms of lip enhancement, but many patients "leave it up to the doctor" as to what to do. It is extremely important to deliver what the patient desires if it is in fact rational or possible. Some patients have unrealistic expectations, and when altering the lips with long-lasting fillers it is imperative to "do the right thing." It is helpful to take before and after pictures to show patients average treatments. Patients who have esthetic lips to begin with are the best candidates for novice injectors as it is easy to make them look better. Patients with thin, ill-defined, or senescent lips are difficult for even the most experienced injector.

The absolute key to learning about fillers is to be conservative. I tell my patients that injecting fillers is a sculpting process and not a single treatment. All patients are rescheduled for a 2-week follow-up. At this follow-up, it is decided if any touch up is needed or if any asymmetries exist and if the patient is satisfied. Furthermore, it must be decided in advance (usually in the informed consent) on who will pay for any touch-up or re-injection.

In general, when performing a consult for fillers, the doctor should determine what exactly the patient wants and select the appropriate filler. The patient should be instructed about the positive and negative effects of the filler, and the recovery and longevity should also be discussed. Overselling a result or longevity can cause problems, so it is always preferable to be realistic. Generally, I discuss with patients their desires, which are usually outline and plumping for the lips and decreasing fold and lines on the skin. Almost every single patient will express a desire to avoid overdone lips.

If the patient has a well-defined Cupid's bow, then I will usually not address this and confine the injection into the deeper portion of the lip to increase volume. Many patients only need plumping in the middle one-third of the lip and will look unnatural with fullness extending to the commissures. This is variable and must be discussed with the patient. If the patient has a poorly defined white roll or Cupid's bow, then this area is augmented with the intention to duplicate a white

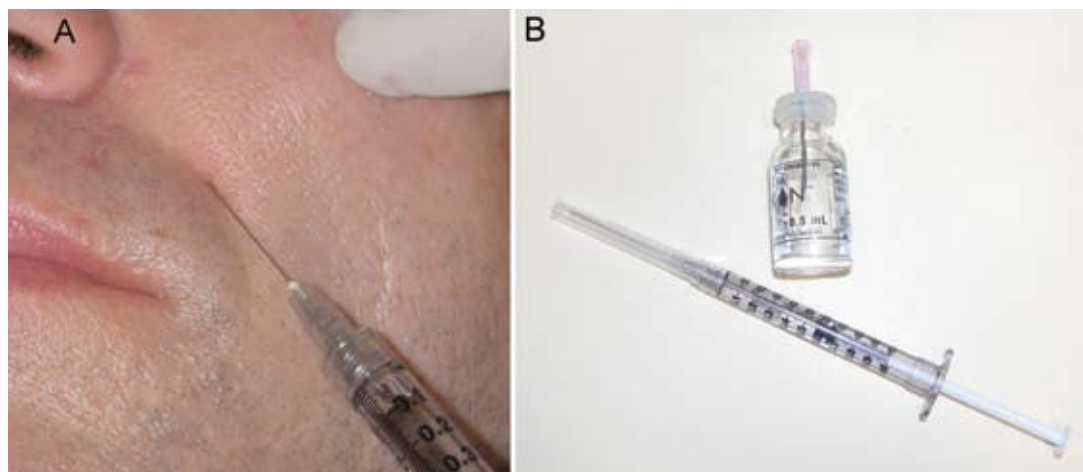


FIGURE 2-11 A, Silicone injection in the nasolabial folds of a patient with human immunodeficiency virus lipoatrophy from antiretroviral drugs. B, The silicone vial and injection syringe.

6 Diagnosis and Treatment Planning

roll using filler to outline the “lazy M” configuration discussed above. Some patients may want or need augmentation of both the lip outline and the deeper volume. Although most patients desire better looking lips, many older patients will present with the desire to efface lipstick lines. This can be a difficult thing to do with fillers only. By injecting multiple vertical lines, one can build a series of “speed bumps” if not careful. Although one can inject these lines individually, I prefer to address them by either recreating the white roll or plumping the entire lip, which will stretch the lines. I also explain to these patients that alternate procedures such as laser resurfacing may be necessary to achieve their desired result.

When addressing nasolabial folds, I explain that fillers will not eliminate the folds, but rather will blunt them. I further explain that adults would look unnatural if they had no nasolabial folds. One problem that exists with lips, folds, and wrinkles is when the patient will not purchase the adequate amount of filler to do the job. Fillers are obviously expensive, but underfilling an area will usually disappoint a patient. In my experience, a single syringe may suffice to augment an upper lip and possibly a portion of the lower lip. If both lips need attention, then two syringes are probably necessary. Similarly, it is a rare situation where a single syringe of filler will augment two nasolabial folds. This must be explained to patients or they may be unhappy or feel that the treatment did not work.

Oral commissures are an area that can also take a lot of filler and produce minimal results. When patients request filler injection to “turn up the corners of the mouth,” they should be made aware that it may take multiple syringes and that the results will be mild to moderate. Other facial wrinkles may respond very well to dermal injection. The glabella, cheeks, and lateral canthal region are popular areas for filler injection. It is also favorable to use Botox in some areas such as the upper face when contemplating fillers. By reducing the movement of underlying muscles, the fillers will frequently last longer.

Injection Techniques

Several common injection techniques exist. Linear threading is a method of injecting a continual line of filler while keeping the syringe moving forward or backwards. This is the same mechanism used when putting a line of toothpaste on a tooth brush. Serial puncture is another technique and involves injecting separate beads or boluses of fillers in a similar means as decorating a cake with medallions from a frosting injector. This technique puts down small beads of filler. In reality, most injectors use a combination of both these techniques. Linear threading is good for generalized injecting and serial puncture techniques are good for filling in gaps or

fine-tuning small areas. When using serial puncture techniques, it is important to keep the filler beads close together so as not to have a bumpy appearance. Figure 2-12 shows a diagram of linear threading and serial puncture.

Lips

After the patient discusses their desires, I usually end up injecting either the white roll area or the deep portion (parenchyma) of the lip or both. Some patients may also get separate injections in the vertical lip rhytids or at the oral commissures. Still others may on occasion get injected in the mentolabial region and marionette lines. Eighty percent of my lip injections involve deeper injection and 20% involve outline techniques.

White Roll Outline

The goal here is to accentuate the white roll and Cupid’s bow area to provide definition, especially in the “lazy M” region. As mentioned above, photographs are taken, topical and local anesthetics are performed, and the lips are wiped with alcohol.

The most difficult step for the novice injector is where to put the filler. Zylplast, Zyderm, Cosmoplast, and Cosmoderm are superficial-dermal fillers. Restylane and Captique are mid-dermal fillers. Restylane Fine Line and Perlane, not yet available in the United States (at the time of this writing), are a superficial-dermal filler and a deep-dermal filler, respectively. Silicone, fat, Radiesse, and Sculptra are subcutaneous fillers. Figure 2-13 shows the placement of a mid-dermal filler.

Since the lip does not have an organized epidermis–dermis complex, the filler is actually being injected into the potential space just under the mucosa. This pertains more to the “outlining of the lazy M,” while augmenting the white roll (Figure 2-14). In this space, the filler should flow freely with little syringe resistance, and there is generally antegrade fill and sometimes retrograde fill as well. When in the correct space, the filler will flow and not “well up” as a lump. If the filler is too superficial, there will be considerable pressure on the syringe plunger, the tissue will “well up” as a lump of filler, and there will be no

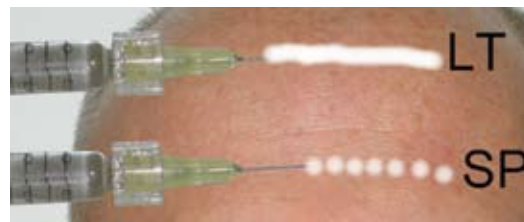

FIGURE 2-12 Linear threading and serial puncture are common injection techniques.

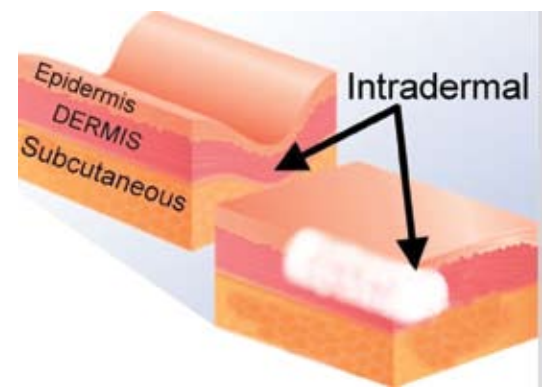


FIGURE 2-13 Most common fillers are placed in the mid dermis. When injecting in the proper plane, there is not extreme skin blanching (indicating too superficial placement) or the inability to see the area fill (indicating too deep placement).

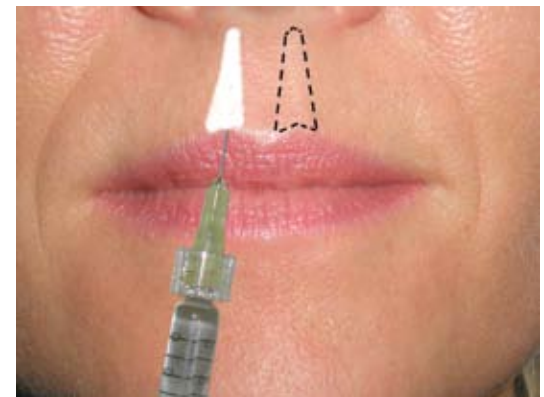

FIGURE 2-14 The “lazy M” configuration of the upper lip and the curvilinear configuration of the lower lip are augmented with a fine bead of filler to reconstruct the white roll at the vermilion–cutaneous junction.

forward flow. On the other hand, if the filler is placed too deeply, it spreads out and does not provide the desired “roll” effect (Figure 2-15). In other words, if you are attempting to make a roll outline, you want to be in the potential space just under the lip mucosa at the vermilion–cutaneous junction. Severe blanching may be a sign of a too superficial injection and can disrupt the vascularity, causing tissue loss.

Deep Injection

If the surgeon is trying to add volume to the lips, then a deeper injection is warranted to provide pout and to generally make the lip larger from within. This can be done in addition to white roll augmentation or as an isolated procedure. To increase the general lip volume, the needle is inserted deeper into the lip, in about the outer one-third to one-half of the lip thickness. With this technique, I usually inject at the wet–dry line and use the linear threading technique, where I am injecting on the way out (Figure 2-16).

17

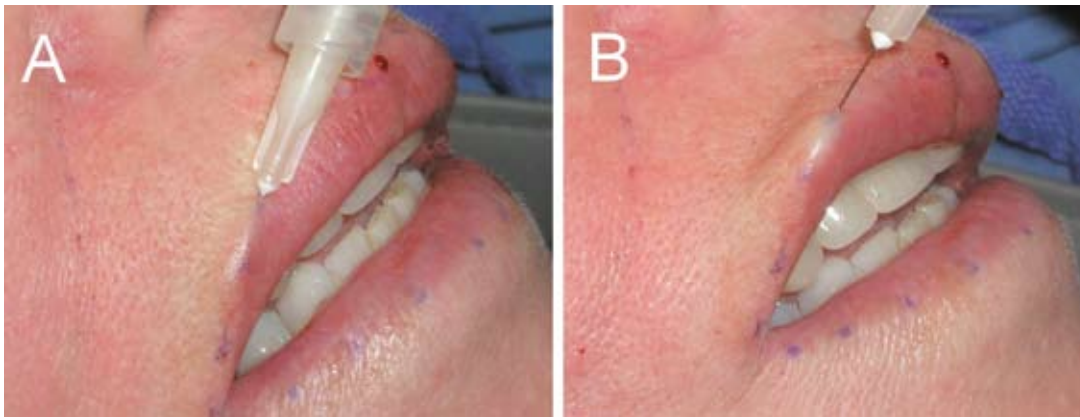


FIGURE 2-15 A, The proper injection plane at the vermilion–cutaneous junction for white roll augmentation. The filler should flow antegrade and retrograde freely with little syringe pressure. B, An improper plane, where the filler is welling up in a bolus and blanching the tissue. There is greater syringe pressure felt as compared with the correct plane.

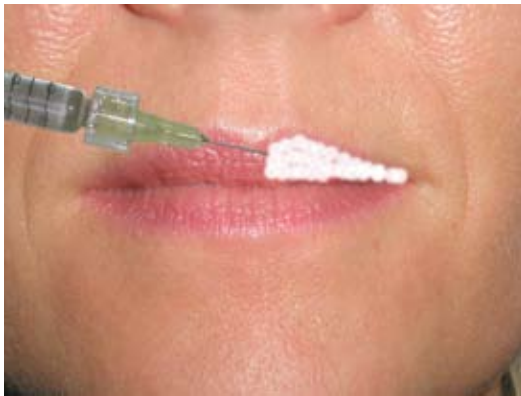

FIGURE 2-16 Deeper lip injection is used to increase the volume and pout of the lip as well as to show increased vermilion mucosa. The needle is inserted at the wet–dry line.

Frequently, I will confine most of the injection to the central one-third of the upper and lower lips and taper the filler as I extend to the commissure. Some patients look better with the middle one-third augmented (what I call the kissing part of the lip), whereas others can use augmentation out to the commissures. Again, it is better to err on the conservative side as you can always add more.

Philtral Column Augmentation

Esthetic lips usually have a well-developed philtral complex. The philtrum is distinct and the paired philtral columns are well defined. I feel that this is one of the most undertreated areas when performing lip augmentation. Basically, the filler is injected intradermally to accentuate the existing columns or make new ones (Figure 2-17). The philtral column is frequently triangular with the apex under the nostril and the base at the central portion of Cupid's bow at the vermilion–cutaneous junction. I pinch this area

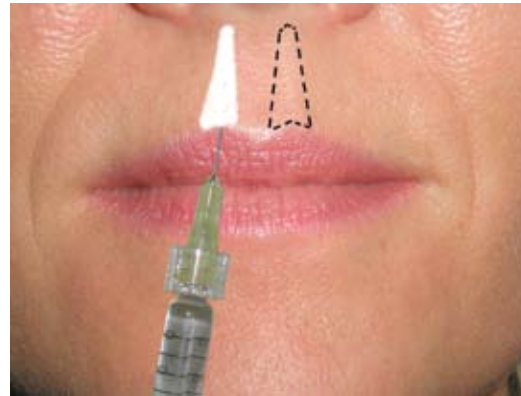

FIGURE 2-17 The philtral columns are an often overlooked feature in augmenting the lips. Small amounts of filler in this area make a nice difference in total lip esthetics.

while injecting to corral the filler in the desired area and maintain the triangular shape.

Figures 2-18 through 2-22 show before and after pictures of filler injections.

Besides the lips, other perioral wrinkles can be simultaneously injected. As stated above, the vertical lipstick lines can be injected separately, but care must be used not to create “speed bumps” along the lip.

The marionette lines (mandibulolabial folds) are frequently injected by intradermal linear threading. Filling depressed commissures can also be accomplished, but in my opinion, it requires a large volume of filler and frequently does not meet the patient's expectations. Sometimes, face-lift surgery is required to pull the jowls and related tissues in a posterior–superior vector, which can make a difference in perioral facial folds. The mentolabial fold is sometimes augmented to improve lower facial esthetics.

Figure 2-23 shows a patient before and after injection of the mentolabial folds to improve the

perioral esthetics in a patient with short lower one-third facial height.

Nasolabial Folds

The nasolabial folds represent the second most requested filler treatment in my practice and in those of most of my colleagues. As the deepening of the nasolabial folds begins by the third decade, it is often the first sign of aging that a patient sees and wants fixed. As most people age, the nasolabial folds deepen and are frequently a driving force in a patient's decision to have face-lift, laser, or other surgical procedures. One main problem that must be discussed with potential filler patients for nasolabial fold treatment is the fact that the folds will not “go away.” Failure to fully explain the anticipated result will lead to a disappointed patient and doctor. I explain to all patients that nasolabial folds are a natural part of facial aging, and an adult without any nasolabial folds would look abnormal, as would an infant with a mustache. I further explain that our goal in treating nasolabial folds is to blunt them, not eliminate them. I tell the patient they are a valley and we want to make them less deep. The next most critical factor is letting the patient know that it will probably take multiple syringes of filler to make a difference. Fillers are expensive, and many patients only desire a single syringe to split between both nasolabial folds. For all but the most minor folds, this is an insufficient amount. In my experience, most patients will require at least 2 syringes to make a difference and it may take up to 4 syringes for deep folds.

Although I rarely inject the lips without local anesthesia, I rarely use local anesthesia for nasolabial folds or other skin injections. I generally apply topical anesthesia for 10 minutes prior to injection. If this is not sufficient, then infraorbital blocks or mucosal local anesthetic infiltration is performed intraorally on the mucosal side of the nasolabial folds.

A significant and common mistake, especially with the novice injector, is to inject in the very center of the nasolabial fold. Since various tissue planes merge in this area, injecting filler material in the center of the fold can cause the filler to migrate laterally. If this happens, one can actually make the nasolabial fold bigger! In order to control the flow and location of the filler in the nasolabial fold, the filler should be injected slightly medial to the actual fold. The filler can also be massaged into the center of the fold. This is one area where I commonly use linear threading and then fill in the gaps with serial puncture. Again, when using hyaluronic acid fillers, significant swelling usually ensues immediately, so it is important not to overcorrect the folds as it becomes difficult to tell what is filler and what is swelling. I have all filler patients return in 2 weeks for follow-up and possibly touch-up.

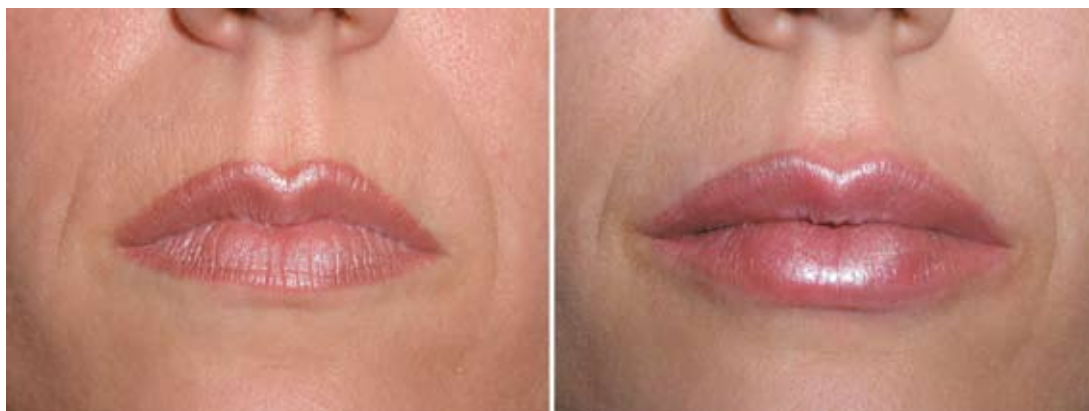

FIGURE 2-18 Before and after images of the lips after Restylane augmentation.

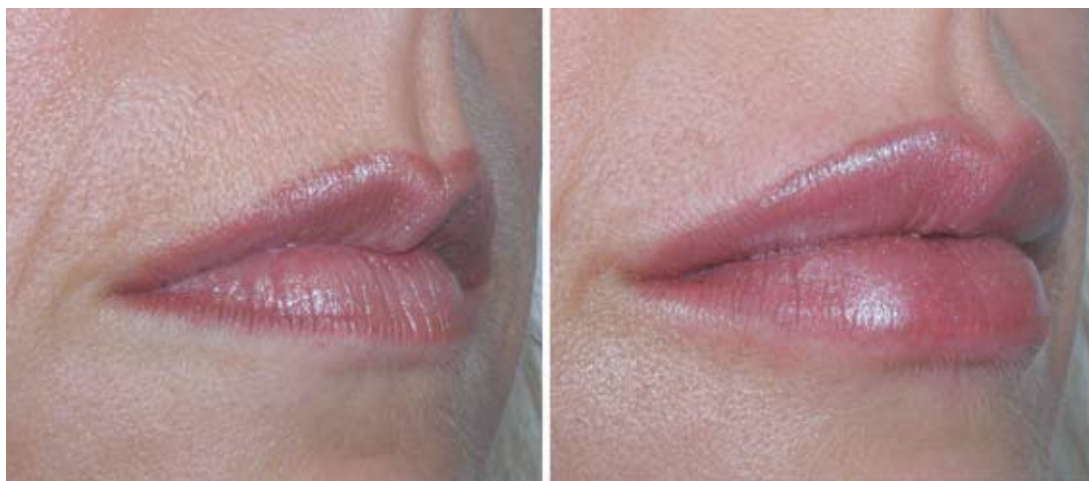

FIGURE 2-19 The same patient shown in Figure 2-18, shown in the oblique view.

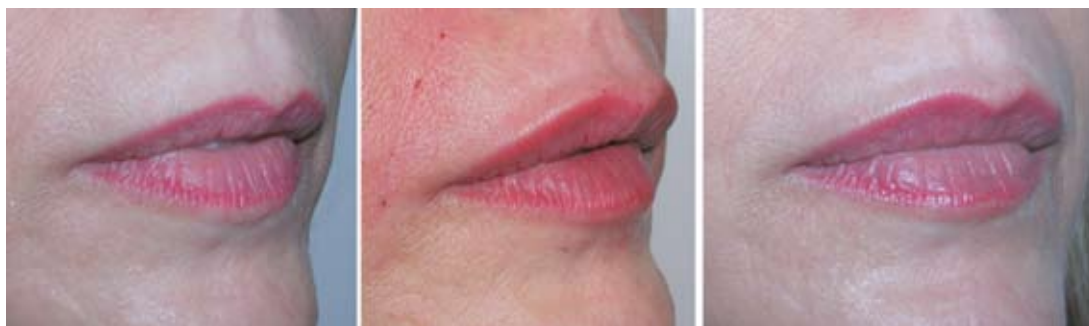

FIGURE 2-20 This patient is shown before, immediately after, and 3 weeks after Restylane augmentation of the upper and lower lips.

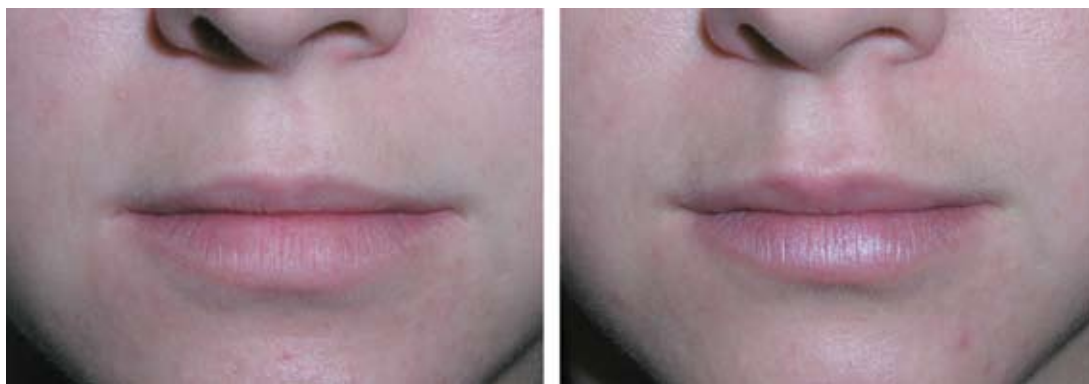

FIGURE 2-21 Before and after images of philtral augmentation with Restylane.

Taking preinjection digital pictures is also important when injecting fillers anywhere. Patients forget what they looked like and pictures are necessary to truly evaluate a result. Figure 2-24 shows a rendering of nasolabial fold injection.

Adjunctive Procedures

Advanta Lip Implants

A discussion of lip fillers is not complete without the discussion of lip implants. Over the past decade, I have placed many Gore-Tex implants in the face.^{8,9} Although many lip implant cases are still doing well, my experience with Gore-Tex lip implants was not favorable, especially when using small strands to augment the white roll. This implant material frequently became hard and torturous. After the urging of several respected colleagues, I embarked on a study with Advanta lip implants (Atrium Medical Inc, Hudson, NH). This implant, like Gore-Tex, is made from expanded polytetrafluoroethylene (ePTFE), but the manufacturing process is quite different. The Advanta implants are designed with a dual porosity structure, as shown in Figure 2-25. This unique design feature is responsible for the implants remaining pliable. I have placed several hundred Advanta lip implants, and I feel it is a worthwhile and predictable procedure. Early in the learning curve, I had placed several implants that were too short and required removal and replacement with larger implants. I have had one infection that necessitated removal. Several patients decided they did not want implants and I removed them. Other than that, my response and results have been extremely acceptable for both doctor and patients.

Lip implants, like other implants, are not for every patient. I usually request that a patient try fillers prior to placing an implant to make sure they like the look. I tell them that although the implant will not impede normal oral function, such as puckering and smiling, they will be able to feel the implant. I liken this to breast implants. I do not like to place them in smokers (although I have), and I do not place them in patients who play woodwind or similar instruments. I explain to the patient that the implant is reversible as they are easy to remove. Implant reversal involves minimal tissue encapsulation, and a simple cut down to the implant with moderate traction will remove them without damaging other tissue.

Procedure

Advanta implants come in various sizes and round or oval configurations. I usually use a 5 or 6 mm implant for major augmentation and 4 to 4.5 mm implants for minor augmentations. I prefer to use the round implants, although the oval ones are favored by some surgeons. The procedure takes only minutes and can be performed with local anesthetic infiltration.

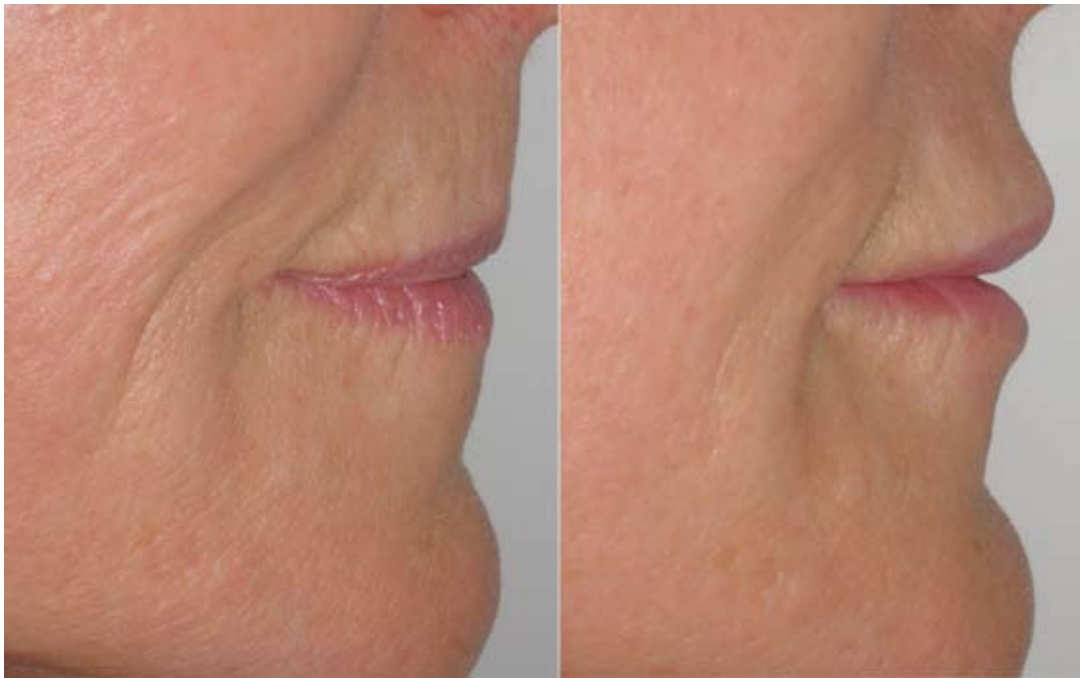

FIGURE 2-22 This patient had significant senescent changes and very hypoplastic lips. Restylane injection has restored youthful contours for this patient.

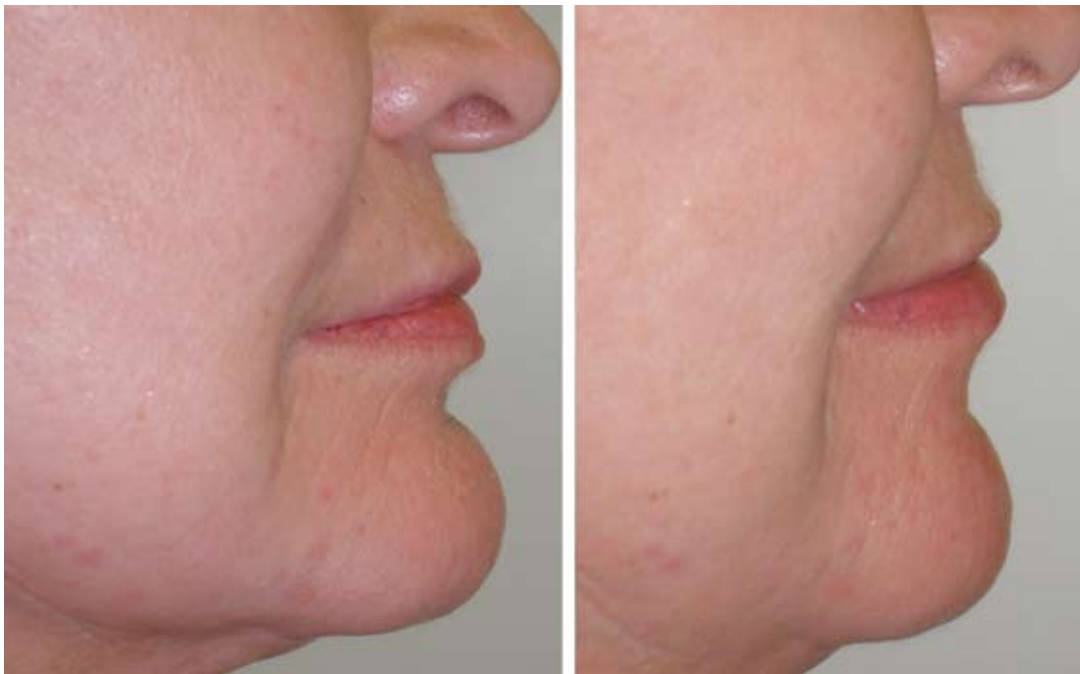

FIGURE 2-23 Before and after images from Restylane injection for mentolabial fold augmentation to improve the lower one-third facial esthetics.

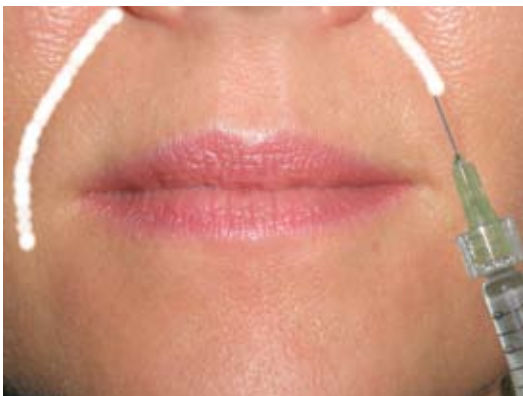

FIGURE 2-24 The nasolabial folds are injected with care to stay slightly medial to the fold, so as not to deposit filler laterally, which will make the fold bigger. A combination of linear threading and serial puncture is used.




FIGURE 2-25 The Advanta lip implant has a unique dual porosity structure that makes it different from previous expanded polytetrafluoroethylene (ePTFE) facial implants.

After sufficient local anesthesia, a stab incision is made several millimeters anterior to the commissure. If upper and lower implants will be used, then a single incision on each commissure is adequate. The pretense to placing this implant is to have the implant sit in the middle of the lip. The labial artery is located posterior in the lip at about the edge of the incisors and is rarely violated. After making the stab incision, the lip needs to be tunneled to make a space for the implant. Most of the various implant sizes can be purchased with a passing trocar that is attached to the implant. This is by far the easiest and most efficient means of tunneling and passing the implant. A passing awl or tendon passer can also be used to create the tunnel. It is imperative to stay in the same plane in the middle of the lip or the implant will not sit naturally. If a trocar is used, then the implant is simply pulled through the lip from one incision to the other. A tendon passer can be used to make the tunnel and is then passed through the lip to secure the implant and to pull it back through the tunnel. It is important to make the stab incisions big enough so as not to constrict the implant when pulling it through or it will be smaller than the actual size. The implant is ductile and some constriction is inevitable, but controllable. After the implant is passed, the lip must be stretched laterally to make sure it lies passively over the implant. I grasp the middle of the lip with both hands and stretch it laterally. I repeat this several times to ensure a passive implant. The implant then needs to be trimmed. I taper the end of the implant with scissors with several millimeters protruding from the incision. Figures 2-26 through 2-29 show typical implant placements. The lip is stretched one more time and the implant tails should fall just inside the incision. It is important that the implants do not protrude outside the incision or they can extrude

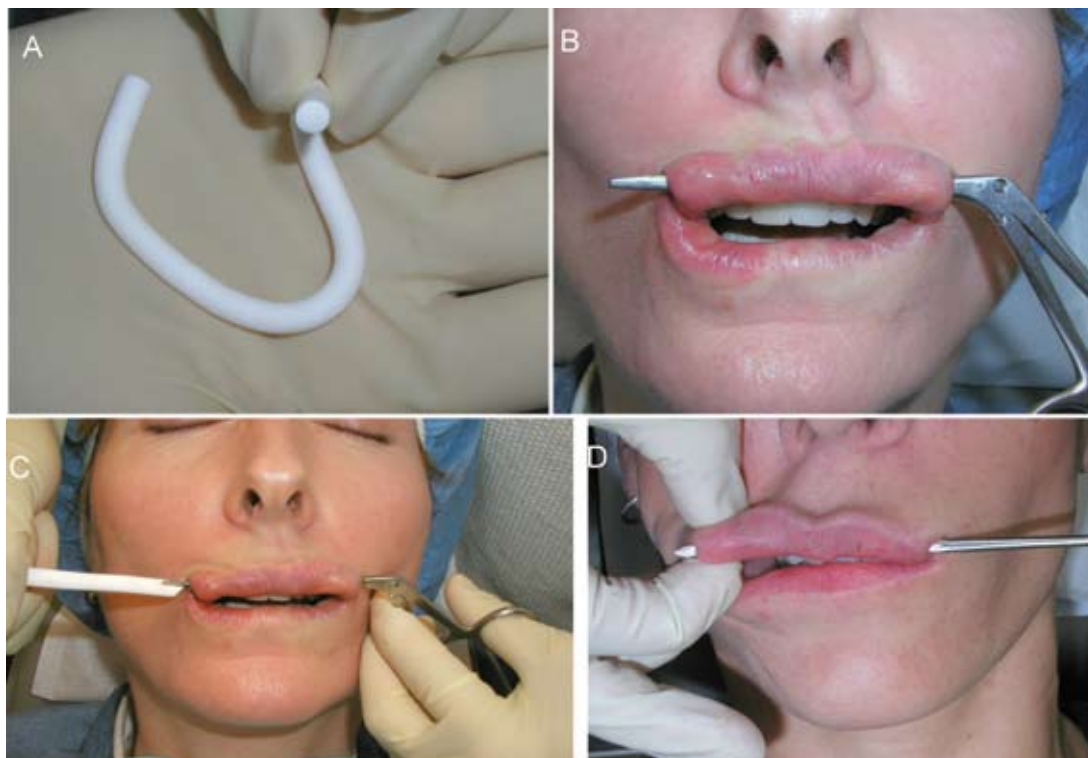


FIGURE 2-26 A, A 5 mm round Advanta lip implant. B, A tendon passer that has been tunneled through the middle of the lip. C, The implant before pulling through the tunnel. D, The implant in place prior to trimming.

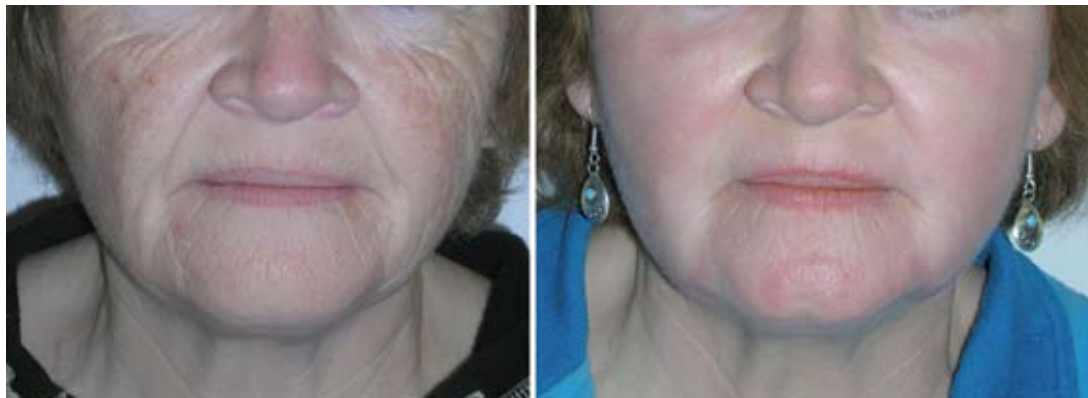

FIGURE 2-27 Before and after images of Advanta implant placement in the upper and lower lips.

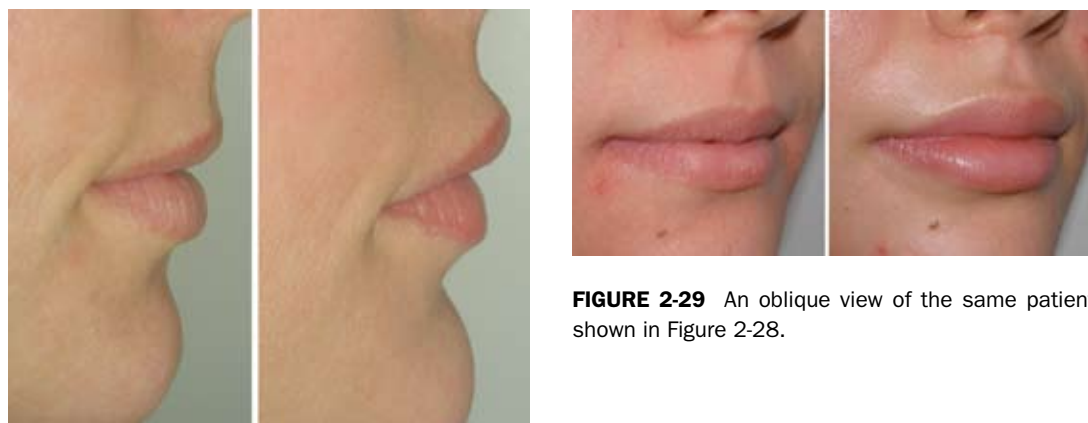

FIGURE 2-28 Before and after images of Advanta implant placement in the upper and lower lips.

through the suture lines. The incisions are then closed with 4-0 gut suture. Patients are placed on antibiotics and analgesics. The healing is generally a weekend procedure, but I have seen several patients develop severe swelling that takes up to 5 days to resolve. With extreme swelling, tapering steroids are used.

Skin Resurfacing

Although fillers and implants can rejuvenate the perioral area, nothing can come close to the impact that aggressive CO₂ skin resurfacing has on this area. Cosmetic surgeons can put all the filler they want in a patient's lips and it will indeed make the lips bigger and the stretch from the filler may hide some rhytids. No filler, however, can cut through decades of skin aging like CO₂ laser resurfacing can. The aging skin is frequently a sallow color and, especially in the perioral area, can take on a pebbly appearance from actinic damage. Solar lentigos and other actinic and age-induced lesions are also quite common, in addition to dreaded vertical lipstick lines.

Laser skin resurfacing works by ablating the epidermis and upper dermis to induce a wound that produces neo collagen when healing. This ablation destroys sun damage and basal layer pigmentation, and when the wound heals it has new skin, no adverse pigment, and is a "younger" color. I never laser the perioral area as a solitary cosmetic unit. I feel that one can get away with solitary periorbital laser skin resurfacing, because the periorbital areas are recessed and blend in when confined to the skin within the bony orbit. The perioral area is quite different. I have seen too many patients treated at other offices with isolated perioral resurfacing, and they end up with a very apparent distinction between the treated and nontreated areas. A laser "milk mustache" is not uncommon. Because of this, I always perform a full face laser when treating the perioral area, to minimize the color disparity and blend the areas.^{20,21}

Figure 2-30 shows a before and after image of a patient treated with periorbital CO₂ laser resurfacing. Note the extreme improvement of this area. In order to not overtreat this area, I will sometimes perform multiple laser procedures spaced 3 months apart.

Complications

There does not exist a cosmetic procedure that is complication free. Fillers are no different. Most complications seen with fillers concern treatment problems such as the following:

- Overcorrection
- Undercorrection
- Allergic reaction
- Bruising, swelling
- Unmet patient expectations

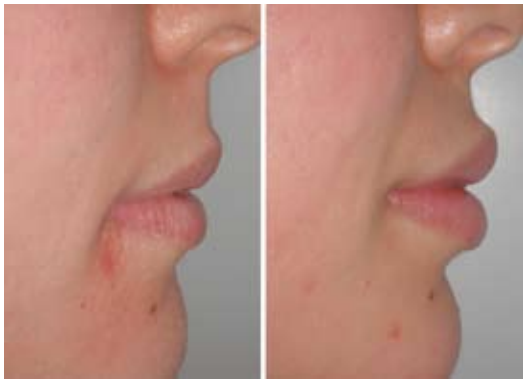

FIGURE 2-30 This patient was treated with aggressive CO₂ laser resurfacing using the Lumenis Encore laser. No other single modality can provide the rejuvenation commensurate with CO₂ laser resurfacing.

- Lumpiness
- Asymmetry

Many of these problems are consistent with a learning curve and become less common with experience. A well-designed informed consent can help improve communications when problems arise. Unfortunately, if a patient is not happy with the results, they often think the doctor did something wrong. It is important to address preoperatively what will transpire with asymmetry or undercorrection. Who will pay for the extra filler? In addition, I always undersell the longevity of fillers. Promising a patient that a filler will last for an extended time can cause problems if it does

not persist. I tell them that every patient metabolizes fillers at a different rate and that I cannot guarantee specific longevity. Patients are informed that a given filler will usually last for a given amount of time, but there are no promises.

Conclusion

Perioral aging eventually affects all individuals and no specialist is more trained to treat this area than oral and maxillofacial surgeons. Perioral rejuvenation is fun and a much appreciated service by patients. By starting with conservative and low-risk procedures, oral and maxillofacial surgeons can learn these techniques and add them to their ever-expanding armamentarium.

REFERENCES

1. Niamtu J. Perioral soft tissue rejuvenation techniques. *Compendium* 2003;22:729–36.
2. Niamtu J. Fat transfer gun used as a precision injection device for injectable soft tissue fillers. *J Oral Maxillofac Surg* 2002;60:838–9.
3. Niamtu J. Cosmetic oral and maxillofacial surgery: the frame for cosmetic dentistry. *Dent Today* 2001;20:88–91.
4. Niamtu J. Clinical technique for fat transfer. In: *Cosmetic facial surgery: an issue of Oral and Maxillofacial Surgery Clinics of North America*. Vol 12. Philadelphia (PA): W. B. Saunders; 2000. p. 641–7.
5. Niamtu J. Cosmetic surgery options in oral and maxillofacial. *J Am Dent Assoc* 2000;131:756–64.
6. Niamtu J. Cosmetic oral and maxillofacial surgery. *Va Dent J* 2000;77:XX–XX.
7. Niamtu J. Facial implant applications for cosmetic facial surgery. *Plast Surg Prod Mag* XXXX;8:26–9.
8. Niamtu J. New lip and wrinkle fillers. In: *Minimally invasive cosmetic surgery: an issue of Oral and Maxillofacial Surgery Clinics of North America*. Vol 17. Philadelphia (PA): W. B. Saunders; 2005. p. 17–27.
9. Niamtu J. Advanta facial implants. In: *Minimally invasive cosmetic surgery: an issue of Oral and Maxillofacial Surgery Clinics of North America*. Vol 17. Philadelphia (PA): W. B. Saunders; 2005. p. 29–39.
10. Coleman SR. Facial recontouring with lipostructure. *Clin Plast Surg* 1997;24:XX–XX.
11. Narins RS, Brandt F, Leyden J, et al. A randomized, double-blind, multicenter comparison of the efficacy and tolerability of Restylane versus Zyplast for the correction of nasolabial folds. *Dermatol Surg* 2003;29:588–95.
12. Niamtu J. Head and neck local anesthetic blocks for cosmetic surgery. In: Friedberg BL, editor. *Minimally invasive anesthesia for minimally invasive surgery*. New York (NY): McGraw-Hill Publishers. [In press]
13. Niamtu J, Carruthers Jean. Pain control in cosmetic facial surgery. In: Dover JS, Alam M, Carruthers J, Carruthers A, editors. *Procedures in cosmetic dermatology soft tissue augmentation*. Philadelphia (PA): Elsevier Saunders; 2005. p. 147–59.
14. Niamtu J. Local anesthetic blocks of the head and neck for cosmetic facial surgery Part V. Techniques for the head and neck. *Cosmet Dermatol* 2005;18:65–8.
15. Niamtu J. Local anesthetic blocks of the head and neck for cosmetic facial surgery Part IV. Techniques for the lower face. *Cosmet Dermatol* 2004;17:714–20.
16. Niamtu J. Local anesthetic blocks of the head and neck for cosmetic facial surgery Part III. Techniques for the maxillary nerve. *Cosmet Dermatol* 2004;17:645–7.
17. Niamtu J. Local anesthetic blocks of the head and neck for cosmetic facial surgery Part II. Techniques for the upper and midface. *Cosmet Dermatol* 2004;17:583–7.
18. Niamtu J. Local anesthetic blocks of the head and neck for cosmetic facial surgery Part I. A review of basic sensory neuroanatomy. *Cosmet Dermatol* 2004;17:515–22.
19. Niamtu J. Simple technique for lip and nasolabial fold anesthesia for injectable fillers. *Dermatol Surg* 2005;31:1330–2.
20. Niamtu J. Complications of laser resurfacing. *Cosmet Surg Times* XXXX;33:21.
21. Niamtu J. Common complications of laser resurfacing and their treatment. In: *Cosmetic facial surgery: an issue of Oral and Maxillofacial Surgery Clinics of North America*. Vol 12. Philadelphia (PA): W. B. Saunders; 2000. p. 579–93.

30

31

Chapter 2: Author Query Form

Author: Joe Niamtu III

Chapter: Rejuvenation of Lip and Perioral Areas

- 1 AU: change okay?
- 2 AU: input okay?
- 3 AU: okay to delete, since aging midface is already clear?
- 4 AU: should this be “isovolumic” or “isovolumetric”?
- 5 AU: using Dorland’s preferred spelling
- 6 AU: deleted because actual duration is given
- 7 AU: change okay?
- 8 AU: “for”? or “in”?
- 9 AU: input okay?
- 10 AU: Okay to set Figure 4 here?
- 11 AU: formalized wording okay?
- 12 AU: input okay?
- 13 AU: as meant?
- 14 AU: pls provide manufacturers
- 15 AU: pls provide manufacturer
- 16 AU: as meant?
- 17 AU: deleted, because is repetition of previous statement
- 18 AU: as meant?
- 19 AU: as meant?
- 20 AU: edits okay?
- 21 AU: input okay?
- 22 AU: pls remember to provide BC Decker with all patient permission letters for printing of any recognizable facial photographs
- 23 AU: to confirm terminology pls
- 24 AU: Please verify figure numbering
- 25 AU: pls provide manufacturer location; city and state or city and country.
- 26 AU: pls provide editor(s) of volume
- 27 AU: pls verify that title is complete
- 28 AU: pls provide inclusive page extent
- 29 AU: pls provide year of publication
- 30 AU: pls provide inclusive page extent
- 31 AU: pls provide year of publication