

Selected Readings in Oral and Maxillofacial Surgery

Aesthetic Maxillofacial Applications of Botox

Joseph Niamtu, III DDS

Oral/maxillofacial & Cosmetic Facial Surgery

10230 Cherokee Rd.

Richmond, VA 23235

804-794-0794

Fax 804-379-2858

niamtu@niamtu.com

www.lovethatface.com

We, as professionals have witnessed a true paradigm shift in cosmetic facial surgery with the advent of Botox (botulinum toxin A, BTA). Today, more than ever, cosmetic facial rejuvenation and surgery is flourishing. The baby boomers have entered their fifth decade and the people that would never age, have suddenly began to droop, wrinkle and sag. Although conventional surgical rejuvenation procedures have been around for over a century, there is extreme interest in “quickie” procedures. Dolly Parton pretty well summed it up when she recently said on an interview with Larry King that “If I bag, drag or sag, I will get plucked, sucked and tucked”. People want aesthetic enhancement without surgery. They want what I call “wash and wear” or “drive through” surgery. Between patient desires and corporate hype, minimally invasive procedures have become all the rage in cosmetic facial surgery. This is good and bad. It is good because this has driven technology to produce innovative ways to simplify and mitigate traditional cosmetic surgery procedures. Lasers, endoscopic technique, MAC anesthesia and Botox are good examples of technology driven facilitation of cosmetic facial enhancement. The down side to minimally invasive procedures is that they are often times over promoted as to the true effect. We all see commercials for “lunch time facelift” “facelift cream” etc. The reason this is bad is that it defrauds consumers and gives cosmetic surgery a bad name. A good credo for minimally invasive procedures is “if it sounds too good to be true, it probably is”. A notable if not archetypical example of the ultimate conservative procedure is Botox. This is probably the only time a product has lived up to its claim for extraordinary results. Botox is in fact a paradigm shift as previous treatments for facial wrinkling were either unpredictable, aggressive, and required significant recovery. Now, a patient can truly improve their wrinkles on their lunch hour with no down time! In

addition, more and more uses for Botox have been discovered and among other things it is now used to treat hyperhidrosis, migraine headache, cerebral palsy, anal fissure, and sympathetic dystrophy.

I have two friends in Vancouver, British Columbia that changed the direction of cosmetic surgery forever, quite unexpectedly. Jean Carruthers is an ophthalmologist who treated many strabismus patients. One day (in the early 1980's) a recently treated patient returned to the office and said that their vision and eye position was great, but they also noticed their wrinkles on that side of the face were gone! They asked my friend Jean if she could do that to the wrinkles on the other side. Jean is married to a dermatologist by the name of Alastair Carruthers and over dinner, she recounted the wrinkle story. This caught Alastair's attention and he thought about it for several days and tried a little experiment. He injected his secretary in the frown lines between her eyes. He really did not know where exactly to put it, or how much to use so he was conservative and waited several days to witness the effect. Three days later when the secretary frowned, lo and behold, her deep furrow was gone, smooth as a peach (1). Not as impactful as Thomas Edison or the Wright Brothers, but none the less, just as revolutionary for the field of cosmetic facial surgery.

Botulinum Toxin A History & Physiology

Botulinum Toxin A is one of the exotoxins produced by the bacterium *Clostridium botulinum*. Botulism is not an infectious disease, but rather a type of food poisoning caused by eating food in which *C. botulinum* has grown and produced toxin.

Botulinum toxin has been called “the most poisonous of all poisons” (2) and is molecule for molecule the most lethal substance known to man. The lethal concentration of this toxin is underlined by the fact that the United States supply of BT that lasted for two decades was synthesized in a 150 mg batch by Schantz in 1979 (3). This batch of crystalline BT A was dubbed batch 11-79.

BTA is one of the eight known toxic serotypes that have been purified (A, B, C1, C2, D, E, F, and G) produced by the bacterium *Clostridium botulinum*. Seven of the eight serologically distinct toxins can produce neuromuscular blockade although type A is the most potent.

This purified serotype of BT A is available in the USA as Botox (Allergan, Inc., Irvine, CA) and in the UK as Dysport (Porton Products Ltd., UK) and is supplied in a hemagglutinin complex in the form of a freeze dried powder ready for dilution with unpreserved normal saline.

Due to the extreme potency of this exotoxin, the 100 mg vial content is barely visible as a light coat of precipitate adherent to the floor of the glass vial. The FDA requires specifications of 100 plus minus 30U per vial. Allergan indicates specifications closer to 100 plus or minus 10 units per vial (4). These variations may affect the clinical action, onset, and duration of the treated areas and must be kept in mind.

20-25 units of Botox are equipotent to 80 units of Dysport and these differences must be kept in mind when interpreting the international literature (5). The LD50 for BTA in mice is 1 unit and is expressed as the amount of toxin injected intra peritoneally that kills 50% of a group of Swiss-Webster female mice weighing 18-20 grams (6). The LD50 for humans has been calculated at 2500-3000 units for a 70 kg person for a lethal dose of 40 U/kg (12). Since the usual therapeutic dose for the treatment of hyper functional muscle lines is 25-50 units, a 100X margin of safety exists. The author cautions that significant labeling and product segregation be employed to identify new and prepared Botox so that inadvertent ingestion or administration is averted. The Botox vial, although labeled, resembles other multidose vials and in addition, once drawn up in tuberculin syringes may be mistaken for allergy medication, insulin, etc.

The packaged exotoxin is stored at -4 degrees C (25 degrees F) in conventional kitchen freezer and once reconstituted is stored in a conventional refrigerator.

BTA is ordinarily incapable of crossing the blood brain barrier and generally exhibits no systemic effects (7).

BTA is a neurotoxin and exhibits its effects on the neuromuscular junction by inhibiting the release of Acetylcholine, which causes weakness or flaccid paralysis (figure 1).

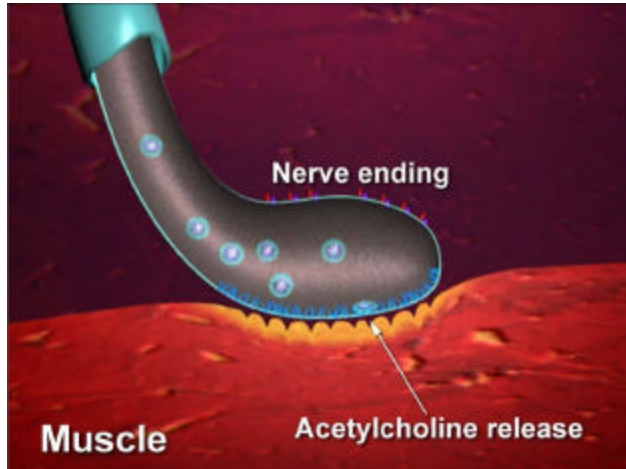


Figure 1. Acetylcholine mediates the nerve transmission at the neuromuscular junction. Botox prevents this release, thus chemically denervates the muscle.

The storage or synthesis of ACH is not affected by BTA, its action effects the vesicle bound ACH (8). BTA paralyzes all striated muscle exposed to this neurotoxin. BTA binds specifically to cholinergic motor end plate and blocks the release of ACH from the presynaptic vesicles, causing neuromuscular blockade.

The binding of the molecule to the motor end plate is permanent and takes 24-48 hours for the therapeutic condition of weakness or paralysis to ensue due to this chemical denervation. The reason for this delay is the time required for the storage vesicles of ACH within the presynaptic motor endplate to be depleted. Although the binding of the ACH is permanent, the paralytic effect only persists for 2-6 months. The reason for this temporary action is the formation of new axonal sprouts, thus reestablishing the

neurotransmitter pathway. This process of neurogenesis allows complete recovery of the transmission pathway and resultant muscle function (9).

Resistance to BTA is rare and has been reported with repeated large doses of the exotoxin (10). Resistance from prolonged usage with strabismus treatments appears to increase with the use of more than 300 U within a 30-day period (11). Botulinum toxin serotypes B and F are similarly potent to type A and are being studied for use on patients whom have developed immunity to toxin type A (4).

No cases of immunity have been described in esthetic treatment (4).

Contraindications for BTA include known hypersensitivity to any component of the preparation (including human albumin), systemic neuromuscular diseases or the use of aminoglycoside or spectinomycin antibiotics which are known to effect neuromuscular transmission and potentate the effects of BTA (12).

Scott (13) reported a study containing 9 pregnant females of which one had a premature delivery thought to be unrelated to the treatment. I never use or recommend use of Botox on pregnant patients.

The Dynamics of Hyperfunctional Lines and Folds

Heredity, smoking, and UV radiation contribute to the aging process. As patients age, the histological and environmental changes in the skin as well as static muscle tone of the muscles of facial expression cause well recognized wrinkles, lines and furrows of

the forehead, glabellar, and lateral canthal areas. Since many of the muscles of facial expression do not have osseous insertions, they terminate adjacent to the skin and thereby cause hyperfunctional lines from their pull on the skin and subcutaneous structures. Contraction of the frontalis muscle pulls on the skin of the forehead and causes creasing of the skin of the forehead contributing to horizontal folds. The procerus, corrugator supercilli, and orbicularis oculi muscles in turn cause vertical banding in the glabellar area (figure 2) while the orbicularis oculi and associated musculature in the lateral canthal area cause crow's feet wrinkles.

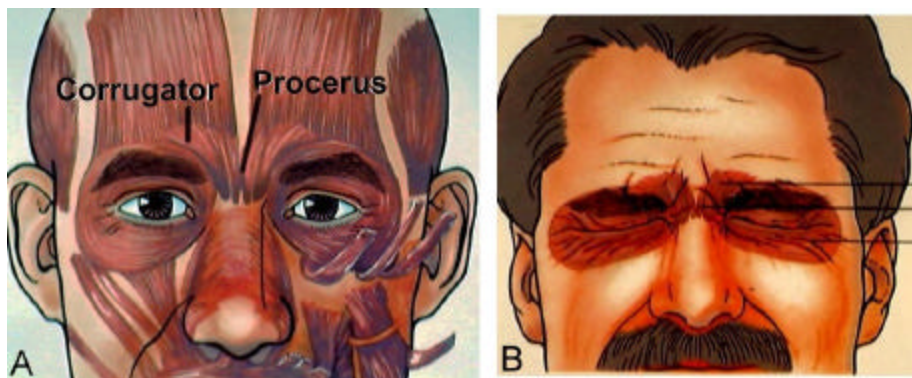


Figure 2. The main muscles of upper facial animation, the frontalis, procerus, corrugator supercili, and the orbicularis oculi. (Medical illustrations by Kathleen Makielski, M.D.)

Several significant observations have been made as a result of Botox therapy. Although the cause for glabellar wrinkling has been well known by anatomists for centuries, Botox paralysis has shown us that some of the muscles of facial expression exert activity even when nonanimated. For those who perform brow lifting they realize how hard it is for some female patients to relax their eyebrows due to continual subconscious frontalis activation. I have also experienced this phenomenon multiple times in the following

scenario. A patient has significant glabellar folds and when scowling activates the involved muscles, but many patients also show these wrinkles or folds to a lesser degree in repose. When subjecting these selected muscles to a weakening or paralytic dose of Botox, the wrinkles are not only eliminated in function, but also in repose. This suggests that these muscles maintain a hyperfunctional state or resting tension in repose. An additional beneficial observation made by clinicians is the presence of a slight incidental brow lift that accompanies the paralysis or weakening of the orbicularis, procerus and corrugator muscles. When these muscles lose their innervation, their downward pull on the frontalis is lost. This in turn causes the inferior fibers of the frontalis musculature to be unopposed, thus causing an elevation of the brow.

Scowling is the expression produced by activation of the procerus, corrugator supercilli musculature and part of the orbicularis oculi muscle (figure 2B). For some people, this muscle activity is interpreted as sadness, displeasure, or unhappiness. The interpretation of this muscle activity by friends, family, and co-workers has proven to be a disability to some individuals. I have had schoolteachers, salespeople and mothers complain that the interpretation of a scowl has a negative effect upon their students, customers and families. This type of patient is an ideal candidate for treatment with Botox. In addition, many patients have no social stigma with their lines and wrinkles merely desire to obtain a more youthful appearance.

Unreconstituted Storage

Botox (BTA) is shipped from Allergan in a specialized Styrofoam container packed with dry ice. The unreconstituted Botox can be stored indefinitely in a conventional household freezer.

Reconstitution

The toxin is contained as a thin precipitate in the bottom or sides of the bottle and requires reconstitution (figure 3).



Figure 3- The toxin is packaged as a thin coating of precipitate in the bottom of the bottle.

Originally, it was recommended to use non-preserved saline, but I have found no difference when using preserved saline.

Original reports cautioned users to very gently allow the diluent to mix with the Botox in the vial and to refrain from frothing when mixing (14). Additionally it was recommend to gently roll the vial in the palms of the hands to prevent frothing as it was thought this would break down the labile toxin. Although initially observed, I now pay little attention to these factors and mix the unpreserved saline as we would dilute any medication in a vial. More recent study has shown that foaming has no effect on the stability of the toxin. (15)

Most clinicians draw up the reconstituted Botox with an 18 gauge needle by puncturing the stopper. It is impossible to extract all of the Botox with this method, especially with low volume dilutions. I have found it advantageous to use a simple bottle opener to pry off the cap of the Botox vial and then draw up the solution by inserting the 18 gauge needle into the open vial. It is never recommend to use the actual injection needle to draw from the rubber stopper as it will severely dull the needle and cause more injection pain.

Most practitioners utilize 1cc tuberculin syringes with a ½ inch 30 gauge needle. The reconstituted Botox is then stored in a common office refrigerator until used. Recently, a 32 gauge needle has become available and is my needle of choice (Air-Tight Products, Virginia Beach, VA 800-231-7762). My patients can appreciate a difference in this

smaller needle. I have, however, observed that the smaller the needle, the quicker it dulls with injection.

Dilution

Carruthers original studies consisted of a 1cc dilution of unpreserved saline (4) and they still utilize this dilution (5). I have experimented with several dilutions and found no discernable difference in longevity based upon observation or patient reporting.

Regardless of the dilution, approximately 4 units of Botox is injected in the glabellar areas while 2-3 units is injected in thinner muscular areas such as the frontalis and lateral canthal regions. With experience, more attention was paid to the size of the injected bleb than the actual syringe graduations.

I feel that there are drawbacks to using the small 1.0 cc dilution. This small volume, by capillary action, leaves a coating on the bottle that prevents all of the reconstituted Botox from being drawn up in syringes. Even though 1 cc of unpreserved saline is added, less than 1cc can be drawn up in syringes. Considering that Botox costs \$500 dollars per cc at this dilution, any waste is not cost effective. The other disadvantage is that smaller quantities are injected at this dilution. An injection of 5 units requires 0.05cc, which is sometimes difficult to read on the syringe while injecting. I have found that by using B-D Ultrafine 2 .3ml syringe with 1/4inch 30gauge needle (Becton Dickinson & Co, Franklin, NJ.) the increments injected are much easier to read and handle at this small dilution (figure 4).

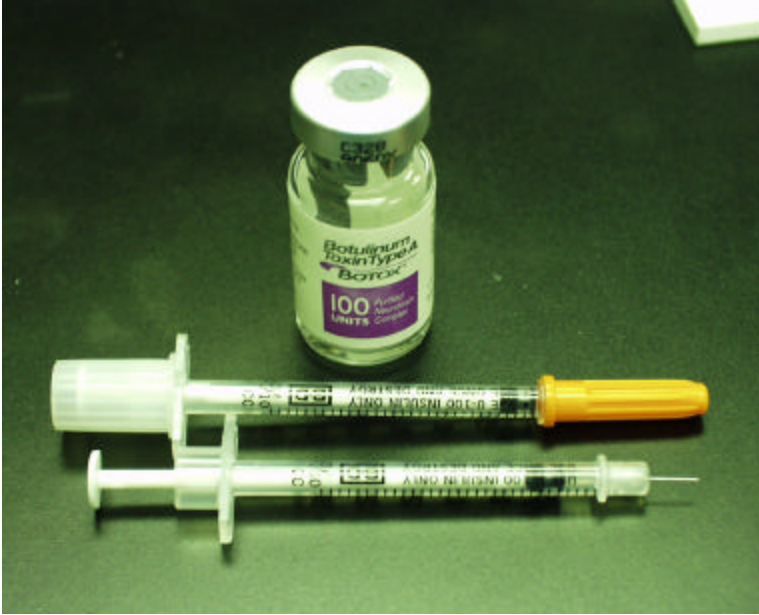

Figure 4. The B-D Ultrafine II syringe is effective for small dilution of Botox. This syringe only holds 0.3 cc's so accurate incremental injection is facilitated.

A positive finding when using a small dilution is that since such a small volume is injected, less pain is perceived by the patient. In addition, it is imperative to purge the air in the needles, especially in the low dilution as there is approximately 0.05 cc of air in the hub and needle of the 30 gauge 1/2 inch needle.

I have experimented with higher dilutional regimens on several hundred patient treatments. 12 cc's of unpreserved saline was utilized on 174 patient treatments. There was no significant observational differences in the length or effect of paralysis. These patients developed paralysis at about 72 hours had a lasting effect of about 3 months. One disadvantage of such a high dilution was that we observed slightly more injection pain as well as a larger post injection bleb at each site (figure 5).

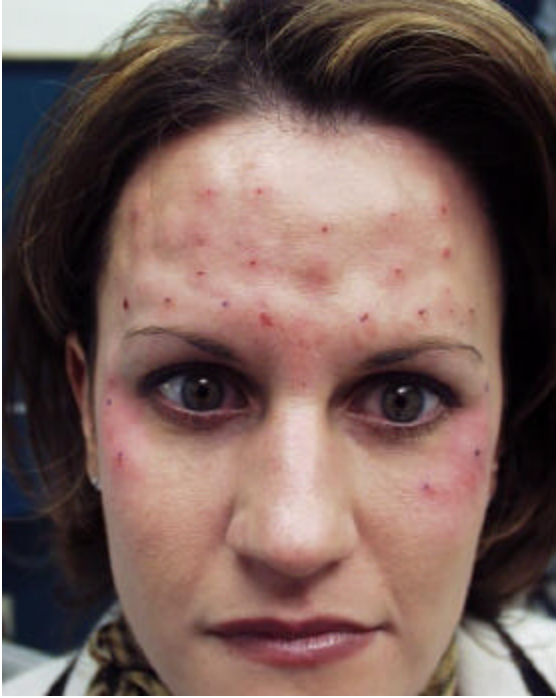

Figure 5. A full upper face Botox patient immediately post injection illustrating injection blebs of 2-4 units of Botox when using higher dilution.

Due to the increased pain and the fact that the larger blebs prevented patients from doing Botox treatments over their lunch break from work, I switched to a 6 cc dilution per vial of Botox. About 1,000 patient treatments have so far performed at this dilution with the same time of onset and longevity as the previous dilutions. The Botox vial will hold 6cc of unpreserved saline and we have found this to be a convenient method for injection. Six 1 cc syringes are then drawn up from the bottle. Each syringe contains 17 units or 1.7 units per 0.01cc. I inject a 4-5 mm in diameter bleb in the glabellar area which equals approximately 4 units of Botox per injection. Approximately 2 units are injected in smaller blebs in the frontalis and lateral canthal regions. Larger muscles require more Botox, regardless of the anatomical area. I currently utilize this regimen and have found rate of onset, longevity and patient acceptance to be predictable.

In the discussion of dilution, it is important to point out that ultimately, it is the actual number of Botox units that produce the effect. Regardless of the dilution I have found 3-4 units required to treat larger muscles and 2-3 units for smaller or thinner muscles. The increased or decreased dilution only means that more or less diluent is injected per site to achieve the therapeutic effect. Dilution does not save money or make the Botox last longer. There are 100 units per vial regardless of how it is diluted. I simply find it more convenient to use a 6 cc dilution. Muscle paralysis is an all or none phenomenon and a given number of units will affect paralysis, and using more than that is a waste of toxin.

Across the board it is my experience that less Botox is required than the 5 units originally described by Carruthers (4,5). My experience indicates that 3-4 units will produce paralysis of approximately 1 cm in diameter. Again, large, hypertrophied, or active muscles may take more than 4 units to paralyze (16)

Storage

Allergan still recommends using Botox within 4 hours of reconstitution (17). Due to the volume of Botox patients that I treat daily, I rarely store reconstituted Botox. When I first began using Botox and did not have many patients, I stored reconstituted Botox for up to 14 days and never noticed a difference than that freshly mixed. Fulton showed no loss of viability with 30 day storage (18). It has also been recently shown that the paralytic effects of Botox are not compromised by storage up to 43 days (19).

In an unpublished experiment (20), I stored reconstituted Botox at room temperature for 60 days and injected 2 patients. One side of the face was injected with fresh Botox and the other side was injected with the stored Botox. Both sides responded to the injections, but both patients developed minor infections on the side treated with the stored Botox. This was manifested by swelling, pain and erythema. These patients were treated with Cephalexin 500mg Q6H and warm compresses. All infections responded to this treatment in several days. As expected, the side of the patient's face treated with the stored Botox recovered from paralysis earlier than the fresh Botox. Both patients had full return of muscle function on the aged side within one month. The study was aborted due to the infection rate. Unpreserved saline was used for this very limited study and it would be interesting to perform a similar study with preserved saline to see if the infection rate was lower.

Injection Technique

Anesthesia

In my experience, the average patient tolerates the minor discomfort of the BTA injections. Although most patients are apprehensive at the first treatment, they subsequently tolerate injections quite well. Topical anesthetics are frequently used by some practitioners. I have used acid mantle cream mixed with lidocaine (21) ELA-Max cream (lidocaine 4%) (Ferndale Laboratories, Ferndale, MI) cream and Lidoderm

patches (lidocaine 5%) (Endo Labs, Chadds Ford, PA) on patients who inquire about this option. Although these patients report less pain, it is my feeling that it is more of a psychological issue. Interestingly, most of these patients have abandoned topical anesthetics for repeat treatments and merely tolerate the injections. I commonly offer nitrous oxide/oxygen at a 40% concentration for apprehensive patients. This concentration is reported to have the analgesic potency of 15 mg of morphine sulfate with the peak effects seen at 3-5 minutes (22). My experience has been that patients accustomed to nitrous oxide for dental procedures appreciate the analgesia while those patients whom have never experienced nitrous oxide analgesia become more apprehensive from the disoriented feeling of the gas. Finally in those patients who are needle phobic I will administer frontal and supratrochlear nerve blocks with 1cc of 2% xylocaine 1:100K epinephrine. This still requires several injections, but mitigates the remaining injection pain in the frontalis and glabellar areas. It is infrequent we use local anesthetic nerve block for Botox.

Multiple injection techniques have been described. Carruthers originally described a method based upon brow position (4). I have described a method based upon needle angulation and measurement (23, 24). After thousands of injections, I feel that there are only 2 main situations that guide treatment outcomes. Number one and most important is to stay 10 mm away from the bony orbit. The apparent diffusion of Botox is 1-1.5 cm. In the estimated 25,000 injections I have only seen a single case of upper eyelid ptosis and this was in a patient where the injection was close to the upper eyelid.

Injection Technique

After injecting thousands of sites in the upper face I have abandoned precision marking and measuring techniques and disregard needle angulation, making all injections perpendicular to the skin surface. I simply ask the patient to animate and inject 2-4 units into the area of muscle bulge. The only measurement heeded is to stay 10 mm away from the bony orbit. The generalized injection technique is illustrated in the accompanying pictures. It is important to mention that there is no cookbook area to inject for all patients. Due to anatomical variance each patient will present a unique combination of dynamic rhytids upon animation thus the injections are tailored to that specific anatomy. For the glabellar wrinkles I ask the patient to scowl and then I inject 4 units of Botox in 5 areas that correspond to the areas of muscle activity. The first injection is in the area of the procerus which is basically right between the eye brows above the nasal bridge. Paired injections are then done to correspond to the corrugator muscles which basically are 10 mm above the orbital rim on an imaginary vertical line running through the medial canthus. Finally, a paired injection is done to affect the superior medial orbicularis. This injection is performed 10 mm above the orbital rim approximately in the midpupillary line. These injections are shown by the black dots shown in figure 6.

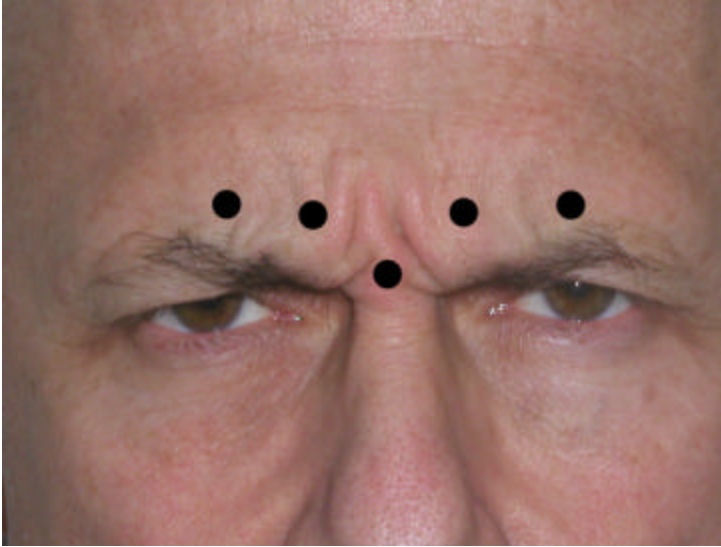


Figure 6. The patient is asked to scowl and 4 units of Botox are injected in areas of maximum muscular contraction. This image illustrates a typical scenario of injection placement for glabellar dynamic lines.

Figure 7 shows a typical result before and 72 hours after glabellar treatment with 20 units of Botox.

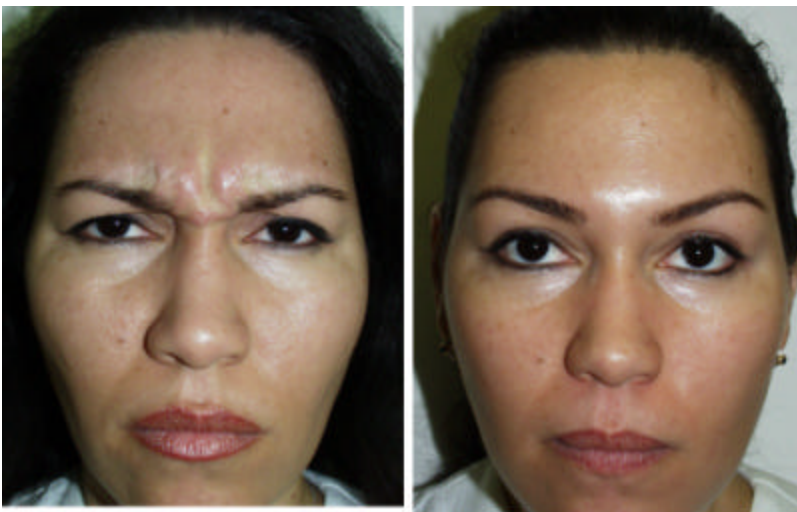

Figure 7. A patient scowling before and after Botox treatment to the glabella.

Treating the frontalis is performed with a series of injections that corresponds to the size of the forehead to the hairline and the amount of wrinkling (figure 8). Basically an injection of 4 units of Botox will affect paralysis in a circumference of 10-15 mm. This means that injection an area will fan out in a bull's eye pattern for about a centimeter.

The key is to use as few injections possible to affect the largest area. There is no harm in over injecting an area, it is merely a waste of Botox. The only danger in over injecting is unwanted paralysis of the brow that may affect the ability to raise the brow. A thin female may respond to 2 units in each frontalis site while a large male with a thick forehead may require 5 or more units.

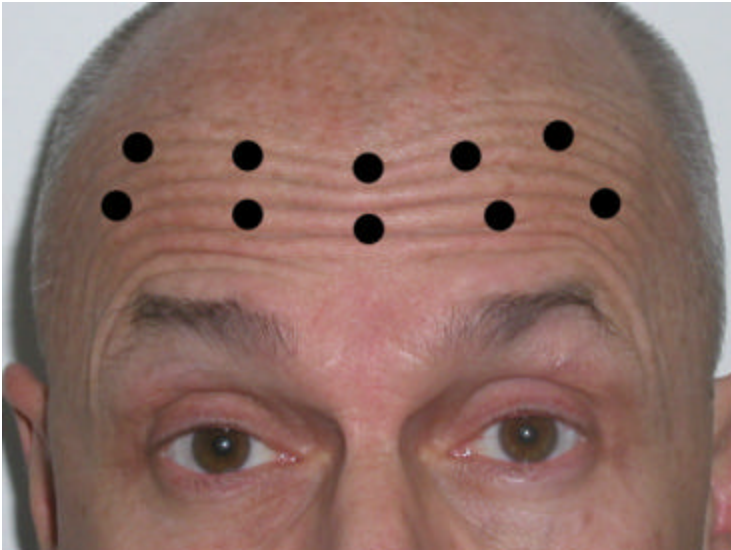


Figure 8. Typical placement of Botox injections for frontalis wrinkles.

It is extremely important to point out a treatment caveat when treating the brow of females. Many females literally walk around all day with unintentional brow elevation and if this is altered without informing them, they can become very unhappy. This is

especially true in the female that has ptotic brows and excessive upper eyelid skin. Frequently, these females intentionally or unintentionally elevate their brows, in part, to mitigate the redundant upper eyelid skin. If the brow is paralyzed, this may make it more difficult to lift the brow and hence stretch the upper eyelid skin. I have seen several females become extremely disgruntled and in one case, clinically depressed, because they perceived a ptotic eyelid. It is important to distinguish that this is not the complication of true eyelid ptosis that can happen from paralysis of the levator palpebrae superioris, but rather a relative ptosis from the inability of the patient to raise the brow which in turn unfurls the redundant upper eyelid skin. In any event, it can make a very unhappy patient that will be mad at you for up to 4 months! These patients will frequently notice the difference when they attempt to apply eye shadow makeup. Previous to Botox injection the person would lift their brow to elevate the eyelid skin in order to apply makeup. If the brow elevators are totally inactivated they can no longer lift the eyelid skin by elevating the brow. Now they have to manually elevate the brow in order to apply eye shadow. This phenomenon can be perceived as lid ptosis by the patient or they can perceive that the treating doctor is inept. Again, these patients will be unhappy for months until the toxin wears off. To prevent this problem I recommend two major precautions. Number one, for patients that have never had Botox injected (or for the first time in your office) do not treat the frontalis and the glabella at the same time. This is especially true in older females that have ptotic brows and dermatochalasis (redundant upper eyelid skin). By only injecting a single area you can ease the patient into a treatment without the problem of perceived droopy eyelid. The other alternative is to inject Botox in what I call a "brow sparing" pattern. This technique involves denervation

of the central frontalis, but leaving active muscle function in the lateral brow. By not injecting the superior lateral frontalis region, it will allow active muscle function, thus enabling brow elevation (figure 9). Remember, you can always go back and inject more Botox to paralyze an area, but once it is treated, you cannot reverse it. In addition, I always explain this phenomenon to patients so they will understand that this is a sequella and not a complication. Figure 10 shows improvement of frontalis wrinkling after treatment with 20 units of Botox.

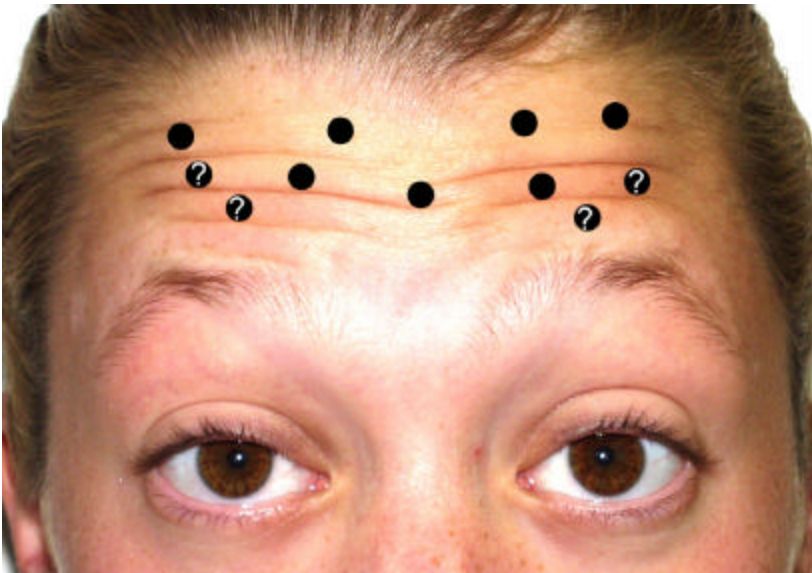


Figure 9 shows the “brow sparing” pattern used to enable eyebrow elevation while treating the frontalis. The question marks indicate areas to be avoided to ensure the ability to elevate the brow.

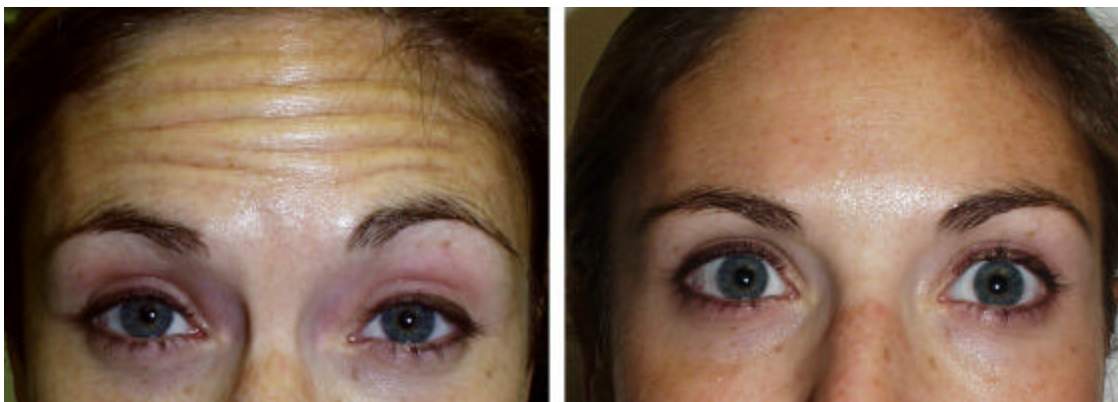


Figure 10. A patient raising her eyebrows before and one week after injection of the frontalis with 25 units of Botox.

Injecting the lateral canthal region also requires caution not to inject closer than 10 mm from the orbital rim. In actuality, some doctors inject closer, but I have done thousands of Botox injections in this area and have never had unwanted paralysis by following this 10 mm rule and highly recommend it.

In most patients the lateral orbicularis is a very thin muscle and can be treated with 2-4 units. Traditionally, I use 3 equally spaced injections along the crow's feet wrinkles while staying 10 mm from the lateral orbital rim (figure 11). Some patients recruit wrinkles from the function of the zygomaticus musculature and an injection in the inferior most area of the crow's feet wrinkles (indicated by question mark in figure 12) can improve this area. Caution is made not to inject too inferior in the cheek as it can cause dysfunction of the lip elevators. Figure 14 shows a positive treatment result of 9 units of Botox to the lateral canthal region.

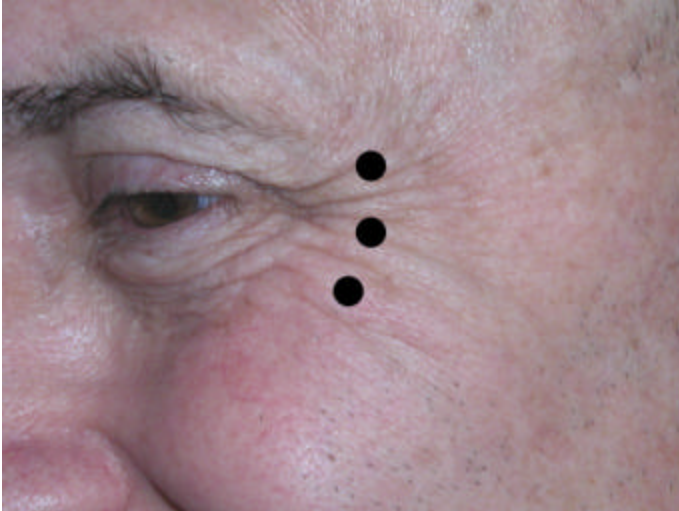

Figure 11. A typical triple injection pattern of lateral canthal wrinkles.

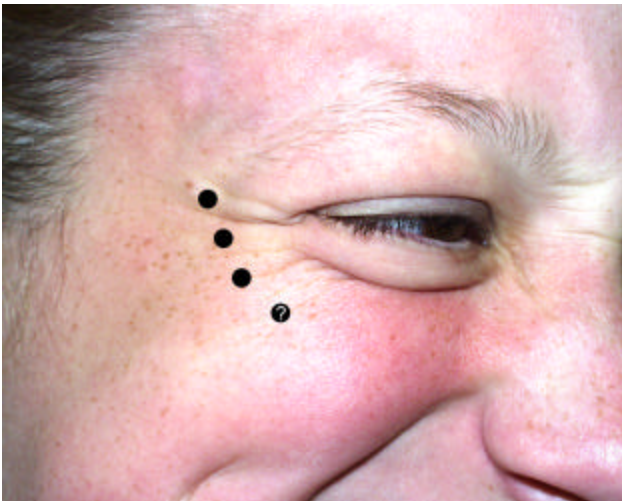

Figure 12. The black dots indicate a typical pattern of lateral canthal injection with Botox. The question mark in the malar region indicates optional injection if the patient recruits the zygomaticus musculature as part of their dynamic lines.

Some patients exhibit lateral canthal wrinkles that extend almost to the temporal tuft area. In these patients, a second series of injections may be performed more lateral than the usual crow's feet injections (figure 13).

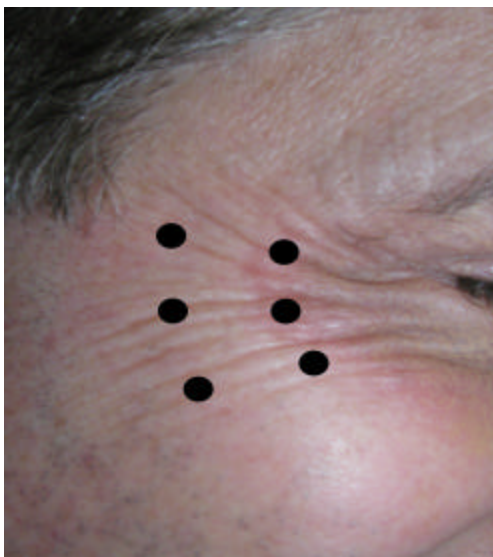


Figure 13. A second series of injections can be performed lateral to the traditional lateral canthal injection sites if the rhytids extend laterally.

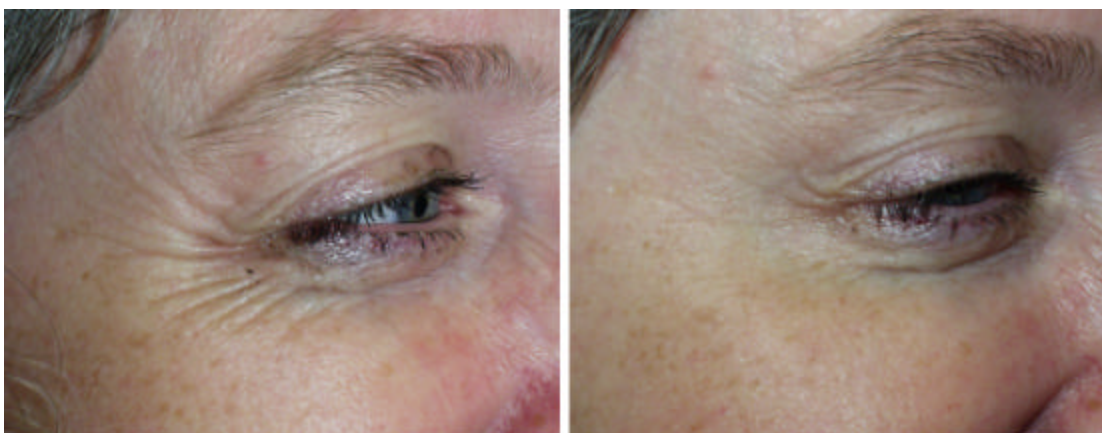

Figure 14. The crow's feet wrinkles are improved in this patient after Botox injection. The patient is squinting in both images.

A caveat for patients is that although frontalis and glabellar wrinkles have dramatic effects, not all patients have dramatic effect in the crow's feet area. It is important that the patient realizes that Botox does not treat skin wrinkles, only the muscles moving the skin. If a given patient has large or active orbicularis muscles, then they may respond

with significant improvement when squinting or smiling. If, on the other hand, the patient has very thin orbicularis muscles with very wrinkled skin, they may see very little improvement in this area.

This brings up another important point that is more practical than scientific. Botox treatment is designed to soften the muscles that cause skin wrinkles. A given dose will soften muscles on some patients while the same dose will absolutely paralyze the muscle in another patient. Like whiskey, some patients are more susceptible or resistant to Botox. I have some patients that complain if they can't animate while other patients complain because they have residual movement. Some patients will return to the office unhappy and want a refund because the Botox "didn't work". To prevent this, your office should have a form with your consent explaining what to expect. I did this and it comes in handy when I have a confused patient. Also the subject comes up on Botox touch ups. If a patient returns to the office a week after having Botox and still has residual movement they may request more Botox and the question arises who should pay for it. If you have informed them of this previously then the patient should expect to pay. If it is a patient that frequently is a long time Botox user at my office I may do it at my cost, but other wise I charge the normal price. A better way to solve this is to charge by the unit for Botox. Some patients take more and some take less and some patients need repeat touch ups. Charging by the unit levels the playing field when it comes to fees.

Alternative Treatment Areas for Botox

In my practice, I use Botox primarily for the areas shown previously in this article. There are many other head and neck applications including, lower eyelids, lips, platysmal bands, masseter hypertrophy, mentalis dimpling, treatment of excessive gingival exposure, corner of mouth, neck lines, TMD/facial pain, surgical incisions, treatment of Frey's syndrome and relative equilibration of Bell's palsy. Detailing all of these indications and treatments are beyond the scope of this article, but several will be discussed here within.

Mentalis Dimpling

The mentalis is a paired muscle that attaches from the chin periosteum to the dermal fibers of the chin skin. When the mentalis is activated, it causes dimpling as it pulls on the dermis and this is cosmetically bothersome for some patients. Treatment of this area is simple. I traditionally inject 2-4 units superficially in several areas around the dimpling. It is important to be conservative in this area and I tell patients I will treat them over several sessions until the desired effect is achieved. Over treatment of this area can cause lip incompetence but I have never seen this. Figure 15 shows mentalis dimpling and injection of the area. Figure 16 shows a before and after treatment result of mentalis dimpling.

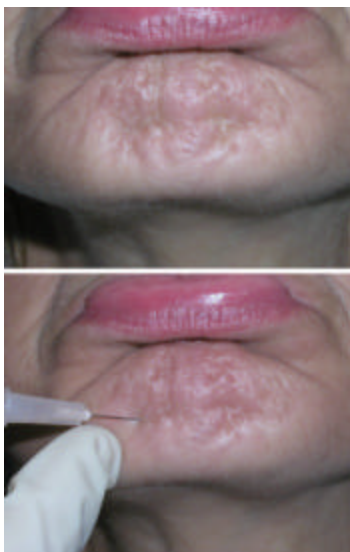

Figure 15. 2-4 units are injected superficially in several areas of mentalis dimpling.

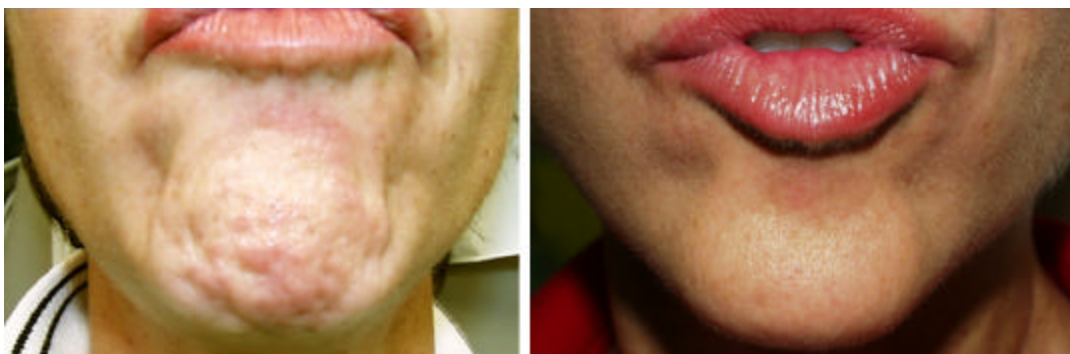

Figure 16. The same patient flexing her mentalis before and after Botox injection.

Headache and TMD Treatment and Masseter Injection

While administering over 1,500 patient treatments with Botox since 1997 I have had multiple reports of chronic headache improvement. This has been observed internationally by doctors that use BTA regularly in the facial areas. Blitzler has reported

a 79% of migraine patients experienced complete or partial improvement at six weeks follow up (16,25,26). I have, to date, treated over 20 patients specifically for headache pain. These were not separated for type of headache, but all 20 patients reported some improvement in severity and frequency of their headaches. This area needs more study and quantification.

Patients with Temporomandibular disorders (TMD) frequently report areas of muscular sensitivity in the temporalis and masseteric regions. I frequently inject these patients in the tender areas with 2-5 units of Botox, but cannot comment on its effectiveness as improvement is multifactorial and may represent a placebo effect. The use of Botox for TMD (27-31) and masseteric hypertrophy (16, 24, 32, 33, 34) have been described I have also injected multiple patients for masseteric hypertrophy with cosmetic concerns. The treatment consists of injecting 5 units of Botox in the area of maximum prominence while having the patient clench (figure 17). The patient is instructed to return in a week and the treatment is repeated until the desired cosmetic is achieved. All of these patients had positive cosmetic results without reported complication of bite loss (figure 18).

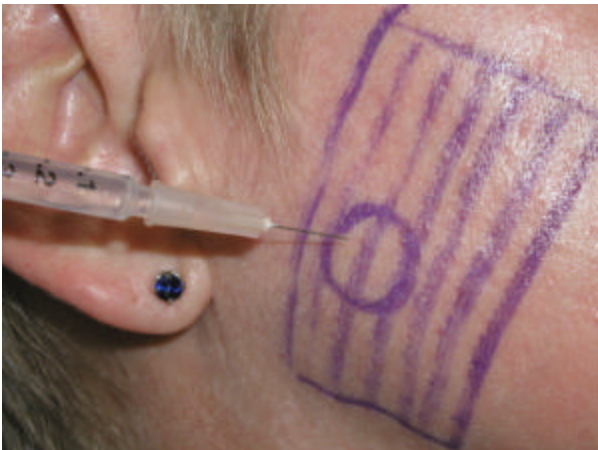


Figure 17 shows the maximum area of masseteric prominence while the patient is clenching. This area is injected with 5 units of Botox and repeated weekly until the desired cosmetic result is achieved.



Figure 18. Pre and 2 week post injection with 10 units of Botox in both masseter muscles. The patient is clenching in both pictures.

Treating Lip Rhytids

Lip wrinkles (lipstick lines) are most frequently seen in females. Males, apparently due to hair follicles, usually do not experience these vertical lip rhytids. Treatment of vertical lip rhytids includes fillers, fat injection, laser resurfacing and Botox. Although I have not found Botox to eliminate these bothersome wrinkles, it can in selected patients improve them, especially in conjunction with lip fillers such as collagen or Restylane. Extreme

caution must be used when injecting perioral botox. If the orbicularis oris is over treated, lip incompetence can occur and last for months. This area should never be treated in patients that depend upon lip function for a living, such as scuba divers, singers or musicians that play flute, trumpet, etc. I have seen a patient treated in another office that drooled and could not drink or eat soup for 8 weeks due to over treatment of the lips.

The technique for lip injection involves microinjections of 1-2 units of Botox and I recommend that the doctor draw up only enough botox for one or two injections at a time. It is difficult to inject 1-2 units when using a syringe filled with a full cc of Botox. It is difficult to perform a microinjection and has the potential problem of over injection by too hard of a push of the syringe or a patients that abruptly moves. It is a good area to use the B-D Ultrafine II syringe previously described. The clinician can dilute the Botox vial with only one cc of saline. By doing this, one can fill 3 Ultrafine syringes which hold 0.3 cc each. These syringes are demarcated for insulin units, but when using a single cc of saline each increment on the syringe equals 1 unit of Botox (35). This is a very accurate method form microinjection. This is one area that I tell the patient it will require multiple appointments to treat. I inject 2 units of Botox in 2 to 4 areas across the upper or lower lip (figure 19). For the beginner, I would start with 2 areas in each lip and have the patient return in a week to repeat the treatment in the same or similar site. By observing this level of caution I have never seen a problem with lip function. Figure 20 shows what I feel is a good result from Botox injection to the lips.

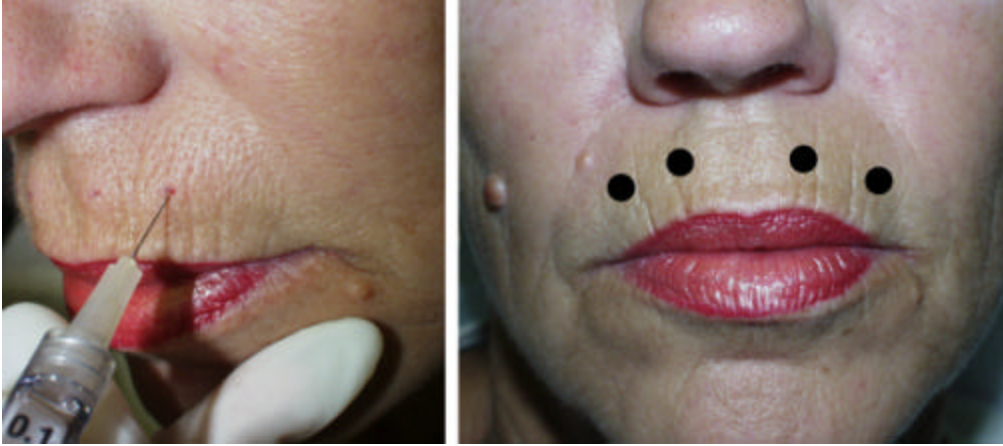

Figure 19. Treatment sequence for vertical lip lines.

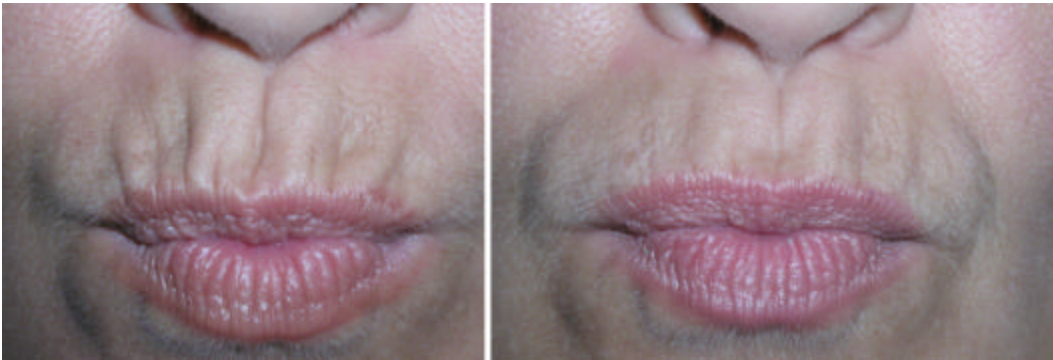

Figure 20. Vertical lip rhytids while puckering before and after treatment with Botox.

Treating Platysmal Banding

Platysmal banding is traditionally treated with rhytidectomy and or platysmaplasty. Nonsurgical treatment with Botox has been well described (36, 37, 38, 39). I occasionally inject this area, but since it is a transient result and expensive, surgical options are more popular. Since the muscles of deglutition are in proximity to the platysma borders caution must be used. Carruthers (39) described a patient that was left unable to swallow for six weeks and required a nasogastric tube after treatment with 60 units of Botox in the platysma bands.

When treating these areas I have the patient flex their platysma bands and I palpate the band between the thumb and index finger and inject 2-4 units of Botox along the bands at a distance of every 10-20 mm (figure 21). It is very important to stay very superficial just under the dermis. This is not recommended for the novice surgeon and one should begin with 2 units per site.

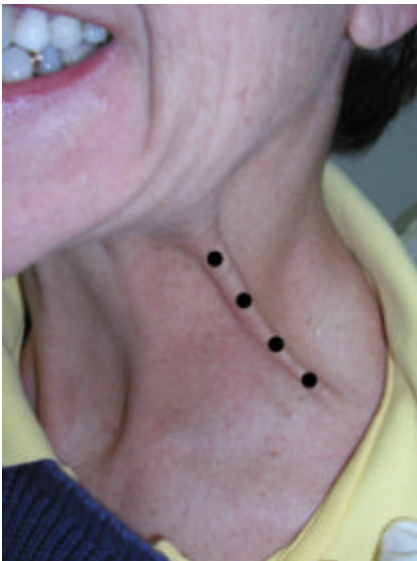

Figure 21. A typical injection pattern of 2-4 units of Botox along a platysma band.

Complications

There have been no long-term adverse effects on health hazards related to the use of BTA for any cosmetic indication (40). In the administration of Botox treatments in approximately 1,500 patient treatments and an estimated 25,000 injections I have seen very few complications. The only major complication was an upper eyelid ptosis that

persisted for about 3 weeks (Figure 22). This was seen in one of my first patients and resulted from injection too close to the upper lid in a patient with very ptotic eyebrows that were at a level below the orbital rim. This patient was treated with Apraclonidine (Iopidine) (Alcon Labs Inc., Ft. Worth, Texas) 0.5% drops used one half hour prior to social situations. This alpha adrenergic agonist stimulates Muller's Muscle causing several hours of transient lid opening. One cannot count on this type of treatment as in severe ptosis it may be ineffective. By staying 10 mm away from the orbital rim, true eyelid ptosis should not occur.

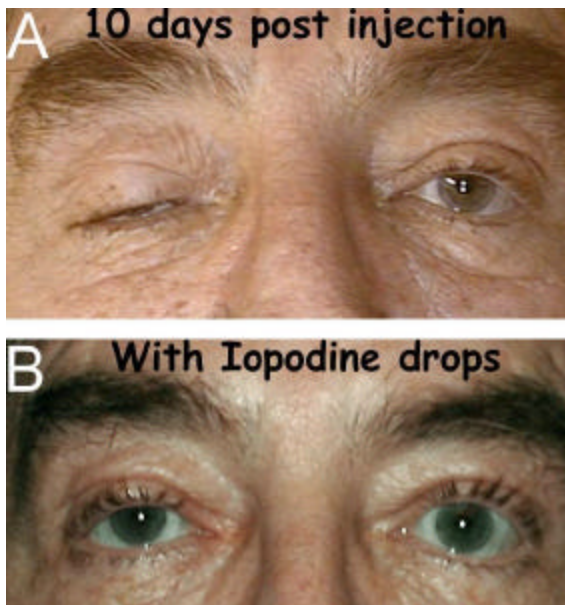


Figure 22. This patient sustained a ptosis of the levator muscle from Botox and is shown in the lower picture after using Iopidine eye drops to stimulate Mueller's muscle.

Bruising is perhaps the most common complication and while it is not serious, it is disconcerting to the patient. It is important to avoid visible vessels and to inject very

superficially in the lateral canthal region. Headache has also been reported in a small percentage of post injection patients but has been rarely seen in my practice.

Women who have been inadvertently been treated with BTA during pregnancy have had uneventful deliveries and thus far, no teratogenicity has been attributed to BTA.

Nevertheless, BTA is classified as a pregnancy category C drug in that it is not firmly established whether it can cause fetal harm when administered to pregnant women.

Furthermore, it is not known whether BTA is excreted in human breast milk, as are many drugs (40). For this reason, the use of Botox should be avoided until pregnancy and lactation are completed.

Clinical Observations

In 1,500 patients treatments, I observed several generalized factors.

- Males seemed to take more units to paralyze a given area, presumably to having larger muscle masses.
- Botox does not last as long in males or in patients over 65 years old.
- Patients with thick or acneic skin require more units per area to achieve paralysis.
- Older patients may require more units per area to achieve desired results.

- Patients (of either gender) with large muscle masses require more units to paralyze.
- Anatomic variations (high hairlines, large foreheads) require more units.
- Periorbital bruising may be minimized by extremely superficial injection and avoiding superficial blood vessels

There are anecdotal reports that if a patient uses Botox for an extended period that the muscles will atrophy and not need continual treatment. Muscle biopsies performed in patients whom were subjected to high dose, repetitive injections of Botox failed to show any long term evidence of permanent degeneration or related to the repeated injections (41).

Many practitioners give their patients specific instructions after administering Botox. Some tell patients not to recline for 4 hours after Botox injection, not to work out or exercise for 4 hours or not to fly immediately after injection. Although I used to adhere to these caveats in the past I honestly do not think it makes any difference with the techniques I have described and I merely tell them to go about their normal day one hour after injection.

Conclusion

Botox (BTA) has been used successfully since 1988 for the cosmetic improvement of facial dynamic lines and rhytids. The author has found the same positive experiences as

detailed by other users of BTA for cosmetic usage. No significant complications were seen in over 1,500 patient treatment sessions. This experience has provided several treatment pearls and considerations to assist those surgeons who use Botox in their practices to treat cosmetic patients. Doctor and patient acceptance has been superlative in our treatment group and we consider the cosmetic use of Botox to be a safe and predictable treatment for the temporary reduction of dynamic facial lines and rhytids.

Photographic Legends

Figure 1. Acetylcholine mediates the nerve transmission at the neuromuscular junction.

Figure 2. The main muscles of upper facial animation, the frontalis, procerus, corrugator supercili, and the orbicularis oculi. (Medical illustrations by Kathleen Makielski, M.D.)

Figure 3- The toxin is packaged as a thin coating of precipitate in the bottom of the bottle.

Figure 4. The B-D Ultrafine II syringe is effective for small dilution of Botox. This syringe only holds 0.3 cc's so accurate incremental injection is facilitated.

Figure 5. A full upper face Botox patient immediately post injection illustrating injection blebs of 2-4 units of Botox when using higher dilution.

Figure 6. The patient is asked to scowl and 4 units of Botox are injected in areas of maximum muscular contraction. This image illustrates a typical scenario of injection placement for glabellar dynamic lines.

Figure 7. A patient scowling before and after Botox treatment to the glabella.

Figure 8. Typical placement of Botox injections for frontalis wrinkles.

Figure 9 shows the "brow sparing" pattern used to enable eyebrow elevation while treating the frontalis.

Figure 10. A patient raising her eyebrows before and one week after injection of the frontalis with 25 units of Botox.

Figure 11. A typical triple injection pattern of lateral canthal wrinkles.

Figure 12. The black dots indicate a typical pattern of lateral canthal injection with Botox. The question mark in the malar region indicates optional injection if the patient recruits the zygomaticus musculature as part of their dynamic lines.

Figure 13. A second series of injections can be performed lateral to the traditional lateral canthal injection sites if the rhytids extend laterally.

Figure 14. The crow's feet wrinkles are improved in this patient after Botox injection. The patient is squinting in both images.

Figure 15. 2-4 units are injected superficially in several areas of mentalis dimpling.

Figure 16. The same patient flexing her mentalis before and after Botox injection.

Figure 17 shows the maximum area of masseteric prominence while the patient is clenching. This area is injected with 5 units of Botox and repeated weekly until the desired cosmetic result is achieved.

Figure 18. Pre and 2 week post injection with 10 units of Botox in both masseter muscles. The patient is clenching in both pictures.

Figure 19. Treatment sequence for vertical lip lines.

Figure 20. Vertical lip rhytids before and after treatment with Botox.

Figure 21. A typical injection pattern of 2-4 units of Botox along a platysma band.

Figure 22. This patient sustained a ptosis of the levator muscle from Botox and is show in the lower picture after using Iopidine eye drops to stimulate Mueller's muscle.

Bruising is perhaps the most common complication and while it is not serious, it is disconcerting to the patient. It is important to avoid visible vessels and to inject very superficially in the lateral canthal region. Headache has also been reported in a small percentage of post injection patients but has been rarely seen in my practice.

Bibliography

1. Personal communication A. Carruthers, J. Carruthers.
2. Lamanna C. The most poisonous poison. *Science* 1959; 130:763-72
3. Klein AW. Cosmetic therapy with botulinum toxin- anecdotal memoirs. *Dermatol Surg* 1996; 22:757-59
4. Carruthers J, Carruthers A. Treatment of glabellar frown lines with C. botulinum-A exotoxin. *J Dermatol Surg Oncol* 1992; 18:17-21
5. Carruthers A. Letter to the editor. *J Dermatol Surg* 1997; 23:303
6. Schantz EJ, Kautter DA. Standardized assay for clostridium botulinum toxins. *J Assoc Anal Chem* 1978; 61:96-9
7. Coffield JA, Considine RV, Simpson LL. The site and mechanism of action of botulinum neurotoxin. In: Jankovic J, Hallett M, eds. *Therapy with botulinum toxin*. New York: Marcel Dekker, 1994:3-13
8. Blitzer A, et al. Botulinum toxin for the treatment of hyperfunctional lines of the face. *Arch Otolaryngol Head Neck Surg* 1993; 119:1018-22

9. Duchen LW. An electron microscope study of the changes induced by botulinum toxin in the motor end plates of slow and fast skeletal muscle fibers of the mouse. *J Neurol Sci* 1971; 14:47-60
10. Schwartz KS, Jankovic J. Predicting the response to botulinum toxin injection for the treatment of cervical dystonia. *Neuro* 1990; 40: Suppl 1: 382. Abstract
11. National Institutes of Health Consensus Development Conference. Clinical use of botulinum toxin. Bethesda, MD: National Institutes of Health, 1990; 8:1-20
12. Pribitkin EA, et al. Patient selection in the treatment of glabellar wrinkles with botulinum toxin type A injection. *Arch Otolaryngol Head Neck Surg* 1997; 123:321-26
13. Scott AB. Clostridial toxins as therapeutic agents. In Simpson LL, ed. *Botulinum neurotoxin and tetanus toxin*. New York: Academic Press, 1989:399-412
14. Carruthers J, Carruthers A: Treatment of glabellar frown lines with C. botulinum-A exotoxin. *The Journal of Dermatologic Surgery and Oncology* 18:17-21, 1992

15. Almeida ART, Kadunc BV, Di Chiacchio N, Neto, R. Foam during reconstitution doe not affect the potency of boulinum toxin type A. *Dermatol SURg* 2003;29:530-32
16. Niamtu J, Botulinum toxin A: A review of 1,085 oral and maxillofacial patient treatments. *J Oral Maxillofac Surg* 61;317-24, 2003
17. Botox package insert, Allergan, Inc.
18. Garcia A, Fulton J Cosmetic deinervation of the muscles of facial expression with botulinum toxin. A dose response study *Dermatol. Surg.* 22:39-43, 1996
19. Hexel, DM, De Almeida AT, Rutowitsch M, De Castro IA, Silveira VLB, Gobatto DO, Zechmeister M, Mazzuco R, Zechmeisteer D. Multicenter double-blind study of the efficacy of injections with botulinum toxin type A reconstituted up to six consecutive weeks before application. *Dermatol Surg* 2003;23:523-29
20. Niamtu, J unpublished data
21. Niamtu, J., Campbell, R.L., "The Anesthetic Skin Patch for Topical Cutaneous Anesthesia," *Journal of Oral and Maxillofacial Surgery*, 1984 Dec; 42(12):839-840
1984

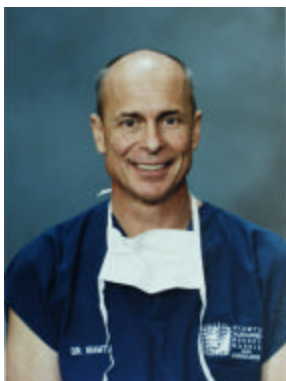22. Bennett CR. Monheim's local anesthesia and pain control in dental practice, ed.7. St. Louis, CV Mosby, 1984
23. Bennett CR. Monheim's local anesthesia and pain control in dental practice, ed.7. St. Louis, CV Mosby, 1984
24. Niamtu, J Cosmetic Facial Surgery
Oral and Maxillofacial Surgery Clinics of North America
Volume 12, number 4, November, 2000 Pg 595-612
W.B. Saunders, Philadelphia
25. Binder W; Brin MF; Blitzer A; Schenrock L; Diamond B . Botulinum toxin type A (BTX-A) for migraine: An open label assessment
Mov Disord 1998;13(Suppl 2):24
26. Binder WJ; Brin MF; Blitzer A; Schoenrock LD; Pogoda JM Botulinum toxin type A (Botox) for treatment of migraine headaches: An open-label study
Otolaryngol Head Neck Surg 2000 Dec;123(6):669-676
27. Daelen, D, Thorworth V, Koch A: Treatment of recurrent dislocation of the temporomandibular joint with type A botulinum toxin. Int J Oral Maxillofac Surg, 26:458-60, 1997

28. Freund B, Schwartz M, Svinington JM. The use of botulinum toxin for the treatment of temporomandibular disorder. *Oral Health*. 1998 Feb;88(2):32-7.
29. Freund B, Schwartz M, Svinington JM . Botulinum toxin: new treatment for temporomandibular disorders. *Br J Oral Maxillofac Surg*. 2000 Oct;38(5):466-71.
30. Ivanhoe CB, Lai JM, Francisco GE. Bruxism after brain injury: successful treatment with botulinum toxin-A. *Arch Phys Med Rehabil*. 1997 Nov;78(11):1272-3.
31. Freund B, Schwartz M, Svinington JM The use of botulinum toxin for the treatment of temporomandibular disorders: preliminary findings. *J Oral Maxillofac Surg*. 1999 Aug;57(8):916-20; discussion 920-1.
32. Park MY, Ahn KY, Duck SJ. Botulinum toxin type A treatment for contouring of the lower face. *Dermatol Surg* 2003;29:477-83
33. Moore AP, Wood G.D. The medical management of masseteric hypertrophy with botulinum toxin type A. *British Journal of Oral and Maxillofacial Surgery* 1994; 32:26-28

34. Smyth, AG. Botulinum toxin treatment of bilateral masseteric hypertrophy. *British Journal of Oral and Maxillofacial Surgery* 1994; 32:29-33
35. Flynn TC, Carruthers JA, Carruthers JDA. The use of the UltraFine II short needle 0.3 cc insulin syringe for botulinum toxin injections. *Dermatol Surg*. In Press, 2001
36. Matarasso A, Matarasso SL, Brandt FS, et al: Botulinum A exotoxin for the management of platysma bands. *Plast Reconst Surg*. 103:645, 1999
37. Kane MA. Platysmal band treatment with botulinum toxin A. *Plast Reconst Surg*. 103:656-665, 1999
- 38 Carruthers J, Carruthers A. Clinical indications and injection technique for the cosmetic use of botulinum A exotoxin. *Dermatol Surg* 1998;24:1189—94
39. Carruthers J, Carruthers A. Practical cosmetic botox techniques. *J Cutan Med Surg* 1999;3(suppl 4);S4-9
40. Klein AW. Complications, adverse reactions, and insights with the use of botulinum toxin. *Dermatol Surg* 2003;29:549-56

41. Borodic, GE. Orbicularis muscle histology after repetitive injections of botulinum A toxin. Atlanta, GA: presented in annual meeting of American Academy of Ophthalmology, 1990.

Author Biography



Dr. Niamtu is board certified by the American Board of Oral and Maxillofacial Surgery and is a fellow of the American Academy of Cosmetic Surgery. He performed his internship at Carolinas Medical Center and his oral and maxillofacial surgery residency at the Medical College of Virginia in Richmond.

Dr. Niamtu founded an 8 doctor, six location private in Richmond in 1983. He lectures internationally on cosmetic facial surgery and has written over 85 publications on various cosmetic facial topics. Dr. Niamtu served as editor of a textbook on cosmetic facial surgery and has written multiple chapters in other text books.

Dr. Niamtu is the developer of The Niamtu Imaging System which is a digital imaging system for cosmetic surgeons that is sold around the world. In May of this year, Dr. Niamtu was elected to the board of directors for The Cosmetic Foundation. Dr Niamtu is also a member of the Botox Cosmetic Physicians Training Network and has the distinction of being a National Training Center for Botox Cosmetic. He also serves as a preceptor for Coherent/Lumenis Laser.