

# Aesthetic Dermatology News™

World News Source For Treatment, Trends &amp; Technology

JANUARY/FEBRUARY 2009 | VOL. 4, ISSUE 1

## Aesthetic Practices Treating More Dark-Skinned Patients

Medical and technological advances have addressed some important concerns

BY JOHN SCHIESZER

Clinicians historically have been wary of performing various aesthetic procedures such as chemical peeling and laser resurfacing in darker-skinned individuals out of concern for the potential side effects, such as post-inflammatory hyperpigmentation. Advances in aesthetic technique and a greater comfort level among clinicians in treating darker skin, however, have given people of color greater opportunity to have appearance-enhancing treatments.



Susan Taylor, M.D.

"We have entered a new era of dermatology in several respects," said Susan Taylor, M.D., assistant clinical professor of dermatology at Columbia University College of Physicians and Surgeons in New York.

"First, clinical trials are including people of color and a diverse subject population has become an FDA requirement for medications as well as devices. Also, the pharmaceutical companies are interested in serving people of color. They are the fastest growing segment of the population and will be in the majority in the year 2040. So, there is a genuine interest in looking at how medications



iStockphoto

and devices may work differently in people of color."

Dr. Taylor helped found the Skin of Color Center at St. Luke's Roosevelt Hospital Center in New York almost a decade ago. Now, similar centers are popping up in cities around the country, including Detroit, Miami, Boston, and Washington D.C., to name a few. Scientific advances have

AESTHETIC, see page 16 &gt;&gt;

## Hydradermabrasion Shows Promise for Facial Rejuvenation

The modality, which involves pneumatic application of an antioxidant serum, decreased fine lines, pore size, and hyperpigmentation

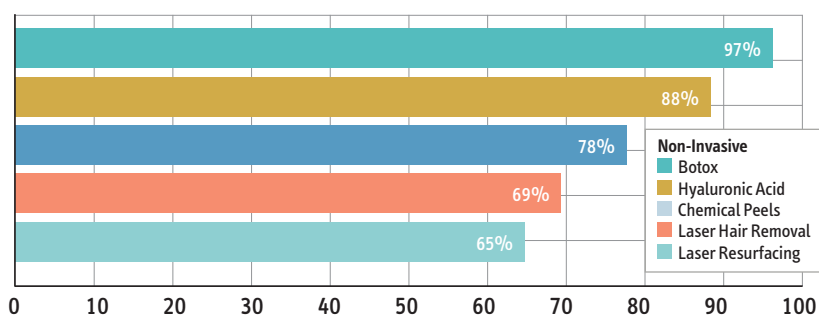
Pneumatic application of a polyphenolic antioxidant serum using hydradermabrasion—a novel modality for nonablative facial rejuvenation—is associated with positive improvements in skin, whereas manual intermittent application of the serum does not, a study suggests.

"Hydradermabrasion, the term coined to describe the procedure that combines crystal-free microdermabrasion using an abrading tip with the pneumatic application of an antioxidant-rich serum, represents another step in the evolution of microdermabrasion therapy," said study investigator Bruce M. Freedman, M.D., Medical Director of Plastic Surgery Associates of Northern Virginia in McLean, Va.

HYDRADERMABRASION, see page 6 &gt;&gt;

### BY THE NUMBERS: Non-Invasive Procedures Offered

Botox treatment was the non-invasive procedure offered by the largest proportion of cosmetic surgery practices surveyed by the American Academy of Cosmetic Surgery in 2007. Shown here are the five top non-invasive procedures according to the proportion of practices offering them.



Source: 2007 American Academy of Cosmetic Surgery Procedural Statistics. Access online at www.cosmeticsurgery.org

## Cellular Grafting Found Effective for Vitiligo in Difficult-To-Treat Sites

Autologous noncultured cellular grafting may be a feasible therapeutic option for vitiligo in anatomic sites considered difficult to treat, a study suggests.

Sanjeev V. Mulekar, M.D., and colleagues at the National Center for Vitiligo and Psoriasis in Riyadh, Saudi Arabia, used noncultured melanocyte-keratinocyte transplantation (MKT) to treat 40 patients (13 male, 27 female) with bilateral vitiligo and nine (four male, five female) with unilateral viti-

ligo. They graded repigmentation as excellent if there was 95 percent to 100 percent repigmentation of the treated area, good if repigmentation was 65 percent to 94 percent, fair if repigmentation with 25 percent to 64 percent, and poor if repigmentation was 0 percent to 24 percent. The following anatomic sites were considered difficult to treat: fingers, toes, palms, elbows,

GRAFTING, see page 15 &gt;&gt;

### INSIDE THIS ISSUE >>

**4** PDL found superior to IPL for port-wine stain

**4** A topical 2% tea lotion is an effective option for treating acne

**6** Capryloyl salicylic acid peel works as well as glycolic acid

**6** Once-weekly application of imiquimod cream improves actinic keratoses

**10** Medical Spas Get Creative With Downturn

**18** The art and science of lip implants

#### COMMENTARY

**8** The Benefits of Lycopene  
BY GARY I. WEINBERGER, M.D., FA.C.S.

**9** Are Botanical Extracts Safe and Effective?  
BY ZOE DIANA DRAELOS, M.D.

#### DEPARTMENTS

**12** Around the World

**14** Global Literature Review

**24** Meetings

## PROCEDURES

# The Art and Science of Lip Implants

Implants are likely to gain popularity as new materials and options expand

BY JOSEPH NIAMTU III, D. M. D.

Women have accentuated their lips since the beginning of recorded history, and voluptuous lips will never go out of style.

Over the past 20 years, the options for lip augmentation have grown exponentially. For doctors who entered their practice more than 20 years ago, there was basically one popular option for lip augmentation, which was bovine collagen. The problems with this treatment were that it required allergy testing and prohibited impulsive treatment, and the effects only lasted weeks to months.

No one can dispute that the introduction of hyaluronic acid and other contemporary fillers have driven the lip augmentation market like we have never seen and it is likely to continue.

Although injectable fillers are a great option, there is a certain segment of the population that is resistant to the repetitive treatment required to maintain lip volume and are either needle-phobic or disdain the injection process enough that they also seek a permanent option and this is where lip implants enter the equation.

Over the years, many materials have been placed into and taken out

of lips for various reasons. Numerous materials are biocompatible in the lips, but the main challenges today have been a natural-appearing, natural-functioning and natural-feeling material.

To date it has been difficult to find all of these qualities in any one given implant. Perhaps the material that has received the most fanfare has been ePTFE.

Although ePTFE has been proven to be extremely biocompatible in many studies, the problem with the early Gore-Tex implants, regardless of the configuration, were that they often contracted and became indurated.

This led to an unnatural feeling and sometimes compromised function. For this reason, many of these implants that were placed were subsequently removed. Further attempts have been made to place ePTFE implants with physical attributes and configurations that encourage tissue ingrowth and stabilize the implant. This made their removal even more difficult, however, and we have seen these implants come and go as well.

All of the lip implant materials that are available today do not have FDA approval specifically for lip implantation but rather for implantation in the face. They are used off label in the lips. Of the existing commonly available implant options, I use one of these four solutions:

- Silicone oil (Alcon, Inc.)
- Advanta dual-porosity ePTFE implants (SurgiForm Technologies)

Figure 1. Silikon 1000 comes in a bulk bottle with a long shelf life. It is drawn up with a 1 cc syringe with an 18-gauge needle and injected with a 26-gauge needle.

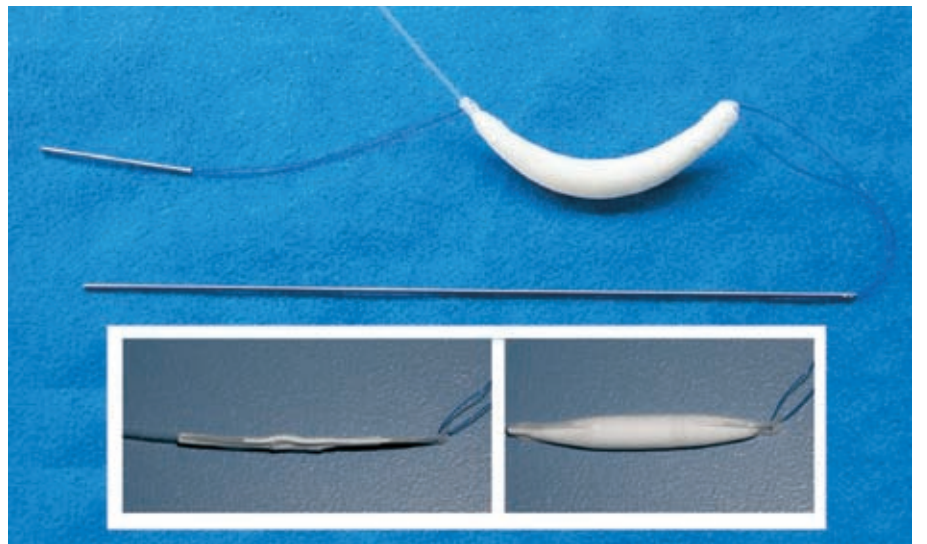
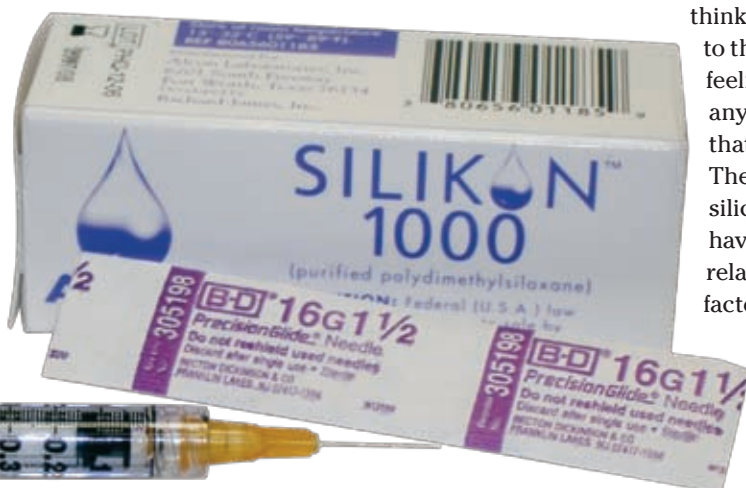

Figure 2. (left) The Advanta implant remains soft due to its unique dual porosity structure. Figure 3. (top) The Verafil implant is a thin silicone membrane powder coated with ePTFE. The filler tube and passing sutures are shown. The inserts show the implant deflated and after saline inflation.



- VeraFil inflatable silicone/ePTFE-coated lip implant (Evera Medical)
- Permalip solid tapered silicone implant (SurgiSil, Inc.)

## INJECTABLE SILICONE

Injectable silicone has been used in the face and lips for many years, and the literature is replete with both accolades and defamation about this product.<sup>1</sup> When used in the microdroplet technique, liquid silicone oil, in my opinion, is the absolute most natural-feeling augmentation material. I

think it comes closer to the natural-feeling lip than any other material that I have used. The problems with silicone injections have been largely related to two factors: the use of industrial-type silicone instead of medical-grade preparations;

and the injection of large volumes of this material, which is well known to migrate when placed in this capacity.

I routinely treat lips and other areas of the face with the microdroplet injection technique.

A 1 cc leur-lok syringe is used with an 18-gauge needle to draw the viscous silicone from the vial. The same syringe is then fitted with a 26-gauge needle and 0.01 cc aliquots of the silicone are injected. It is rare that I use more than 0.2 cc at a single injection in a single lip or nasolabial fold at a single session.

The premise of this technique is that the microdroplets will be encapsulated with collagen, which prevents them from migrating, further augmenting the result. Since this encapsulation process takes three to four weeks, the injections are repeated on a monthly basis until the anticipated endpoint and then the last treatment is stopped to allow for the final augmentation as not to overcorrect.

Although this is a "permanent" filler, in reality these patients may need touch-up every several years. Again, the big caveat with injecting silicone oil is to use microdroplet at repeated sessions and to avoid placing puddles of silicone in any anatomic unit. The common

literature describes the “microdroplet” technique, but I feel that the actual procedure is a “microribbon” technique, since the needle is withdrawn as the microaliquots are injected. In reality, the configuration is probably more similar to a tiny grain of rice as opposed to a spherical drop. In any event, the operative word with this technique is micro. Figure 1 shows Silikon 1000 and related injection material.

#### ADVANTA ePTFE LIP IMPLANTS

I have previously published my experience with the Advanta implants and I still have many of these implants in satisfied patients.<sup>2</sup>

Although the implant does not impede function and does serve well to augment the lip, the biggest drawback is that it is still quite palpable. Most patients are not bothered by this, but there are some patients who will not tolerate a hard or palpable augmentation material in their lips.

The dual-porosity configuration of this implant has surpassed original Gore-Tex implants and the material still remains smoother than the older material. These implants are also technique sensitive in that they must

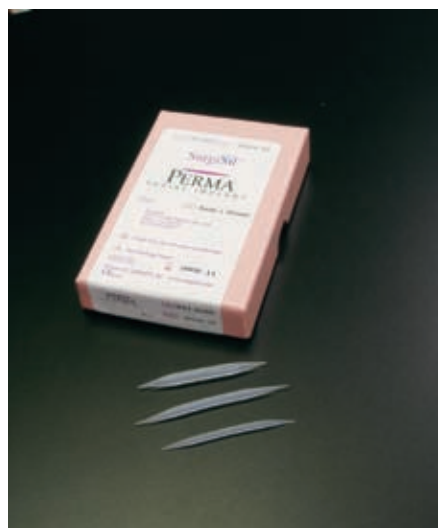

Figure 4. The SurgiSil implant is available in various lengths and thicknesses and has a dual tapered configuration.

be tapered and placed in a means that confines the implant within the vermilion portion of the lip. The tapered ends of the implant must remain in the same plane as not to protrude visibly. Figure 2 shows the dual porosity structure of the Advanta implants.

#### VERAFIL LIP IMPLANTS

The VeraFil implant is an ingenious configuration that is similar with the configuration of breast implants.

This implant consists of a silicone membrane that has a very thin, powdered coating of ePTFE.<sup>3</sup> The implant has a filler tube with a very ingeniously designed self-sealing valve. The implant also has tabs on which are attached sutures to thread the implant through the lip. Once the implant is positioned within the lip and centered with the passing sutures, the

**“Lip implants are not for every patient and I do not offer these as a first-line choice for lip augmentation. I reserve this procedure for those who simply will not tolerate filler injections or who are seeking a permanent option.”**

filler tube is used to inflate the implant with normal saline to a specific volume. The volume ranges for the implants are basically between 0.2 and 0.4 cc of saline.

It is important to understand that this is not a tumescent fill but rather more of a flaccid fill. The goal is not to provide a firm, large, palpable expansion but more of a softer confined expansion similar to an under filled

water balloon. Once the implant is positioned with specific attention to the midline and then inflated, the filler tube is gently pulled out of the implant and the valve seals itself to confine the saline. These implants also feel very natural, as they are fluid filled and not solid. For the past two years, I have had good experience with placing this

ART, see page 20

>>

## AESTHETIC VIDEOSOURCE

### YOUR SOURCE FOR COMPREHENSIVE EDUCATIONAL DVDS



#### The Complete Guide to BOTOX® Injections

Cosmetic surgeon, Dolores Kent, M.D., demonstrates step-by-step injections for:

- forehead lines
- glabellar frown lines
- temporal brow lines
- lateral canthal lines
- lower lids
- nasalis
- depressor anguli oris
- mentalis
- horizontal neck lines
- vertical platysmal bands

(DVD – 1 Hr. 55 Mins.) \$175.00



#### The Complete Guide to Dermal Filler Injections

Cosmetic surgeon, Dolores Kent, M.D., demonstrates how to inject dermal fillers for:

- horizontal forehead lines
- glabellar frown lines
- crow's feet
- tear trough
- nasolabial folds
- vertical lip lines
- marionette lines
- lip definition
- lip augmentation
- chin lines
- mentalis
- scars
- asymmetry

(DVD – 2 Hrs. 29 Mins.) \$175.00



#### The Complete Guide to Laser Hair Removal

Christine Whitelaw, M.D., and Mark B. Taylor, M.D., demonstrate step-by-step procedures and parameter considerations on an IPL and a combined Alexandrite/YAG laser machine for laser hair removal on the:

- face
- underarms
- bikini area
- back
- legs

(DVD – 1 Hr. 44 Mins.) \$175.00



**Dolores Kent, M.D., F.A.C.O.G.**, is a board-certified Harvard Medical School graduate, gynecologist and cosmetic surgeon, with over 20 years of experience. She runs a private practice – GyneSpa – in Los Angeles, offering a unique combination of gynecological and cosmetic services, including cosmetic fillers and liposuction alongside routine gynecological check-ups.



**Christine Whitelaw, M.D.**, is the owner and medical director of SpaQuena Day Spa in the Louisville, Kentucky area. She oversees all medical treatments, including laser hair removal, mesotherapy, sclerotherapy, laser collagen treatments, and photorejuvenation treatments.



**Mark B. Taylor, M.D.**, is a world-renowned dermatologist and cosmetic laser surgeon who has been in practice for over thirty years. Since the origination of laser treatments for skin, Dr. Taylor has been a leader in the field of cosmetic laser surgery, pioneering and teaching many new laser techniques to over 4,000 doctors world-wide.

Get all three complete guides and **SAVE \$105!** Over 6 hours of professional step-by-step training.

AESTHETIC VIDEOSOURCE  
Call 800-414-2434 or 801-282-2490  
Order online at [www.VideoShelf.com](http://www.VideoShelf.com)

CHECK NO. 17 ON READER SERVICE CARD

# The Art and Science of Lip Implants

>> ART continued from 19

implant. Figure 3 illustrates the VeraFil inflatable implant.

## PERMALIP IMPLANT

Finally, the newest arrival on the lip implant market is the SurgiSil solid tapered silicone implant. This implant is used off label in the lips and the configuration is a bilateral taper. The silicone material of this particular implant is extremely soft and pliable, and although it is palpable, the soft consistency is acceptable and does not affect function. Figure 4 shows the tapered soft silicone SurgiSil implant in common sizes.

When dealing with the placement of any of the aforementioned implant devices, the surgical technique is similar regardless of the implant.

These implants can be placed under local anesthesia. The lips are coated with an appropriate topical anesthetic. After several minutes, the mini-block technique<sup>4</sup> is used to anesthetize the lips and finally the deep portion of the lip is infiltrated with local anesthesia, as well. I prefer to make the incision several millimeters medial to each commissure, and I generally place two incisions on the upper lip and two incisions on the lower lip. Some surgeons advocate doing both implants through a single incision in the commissure area. However, in my experience, this could sometimes be more traumatic because of having to bend and stretch the tissues more than simply making two stab incisions on each lip.

Once the stab incisions are made, dissection is then carried through the middle of the lips with a trocar, tendon passer, or alligator forceps (Figure 5). I prefer to use a trocar or tendon passer through the lip with a blunt end, as a feel that I can control the direction and tissue level.

One thing that is extremely important is to make sure that the implant remains in the middle of the vermilion lip. If by chance the implant should be placed in a serpentine fashion that goes in and out of the tissue plane (a sinusoidal-type pattern) the final outcome will be compromised, as the lip will not animate naturally. It is imperative to place the implant through the middle of the lip. The labial artery lies in the posterior third of the lip and the danger of violating the labial artery is low if the middle of the lip is used for placement.

Once the tunnel is made, the implant is passed through. It is important

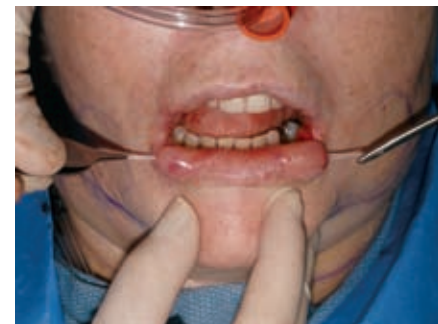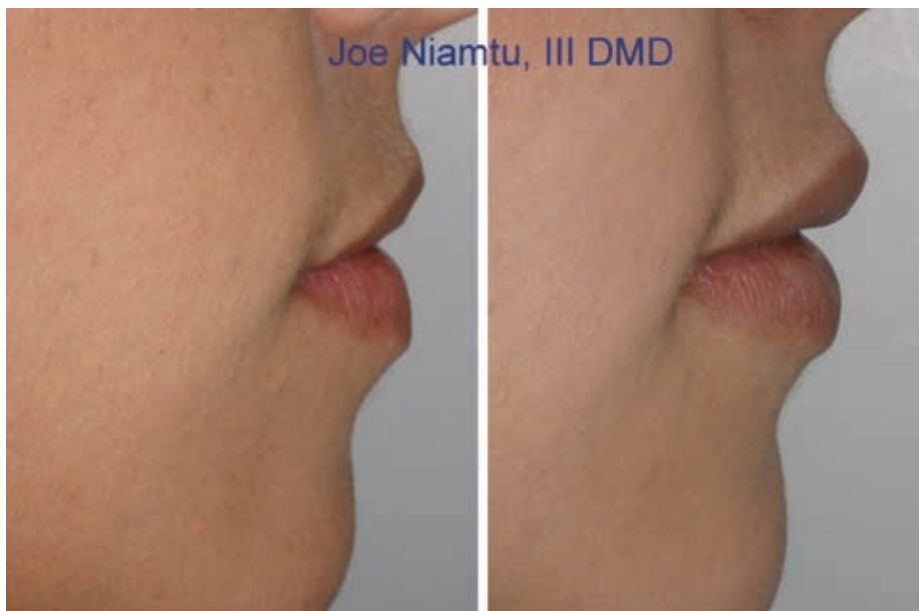
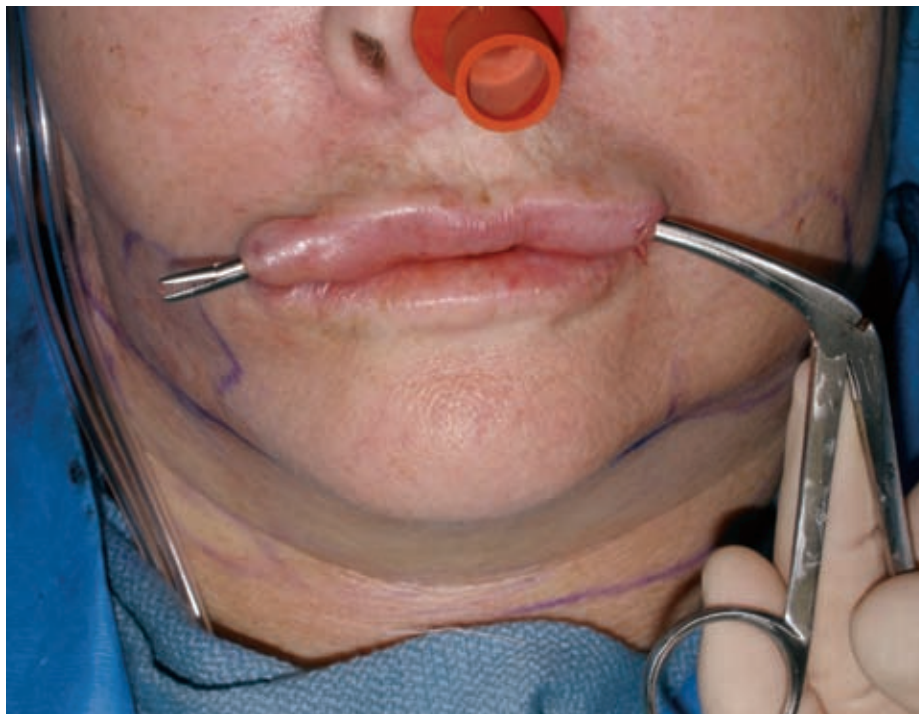

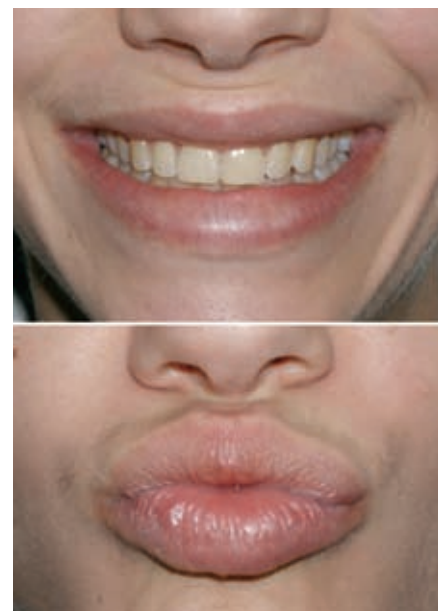
Figure 5. (left) A curved tendon passer creating a dissection tunnel in the mid lip.

Figure 6. (above) An implant being passed through the tunnel.

Figure 7. (lower left) A patient before and after bilateral lip implant placement.

Figure 8. (below) Before and three months after upper and lower implant placement. Soft, well placed implants provide natural function.



that the ends of the implant are not lying over the incision (Figure 6). If this should occur the implant ends can extrude through the incision or become infected. I have had the best results when the implant lies several millimeters medial to the incision.

Once the implant is placed, the incision is closed with 5-0 gut suture. The patient is placed on antibiotics and possibly tapering steroids and asked to refrain from excessive animation and to maintain a liquid diet for 48 hours.

## COMPLICATIONS

Like any implant procedure, complications remain a possibility.

My main challenge over the past decade of placing lip implants has been the positioning of the implant. The most common problem occurs when the distal ends of the implant lie on a more superficial plane than the body of the implant and thus are visible during

**My main challenge over the past decade of placing lip implants has been the positioning of the implant.**

animation or function.

The second most common problem is the plane of placement whereby the implant is placed too superior in the upper lip or too inferior in the lower lip, producing augmentation above the vermilion border and thus an unnatural look.

Finally, implant infection is always a possibility, although it has been extremely rare in my series. When these implants do become infected, I feel that it is prudent to remove them and replace them later. It is not a good idea to place them in smokers

or patients who play instruments requiring significant lip function.

Lip implants are not for every patient and I do not offer these as a first-line choice for lip augmentation. I reserve this procedure for those who simply will not tolerate filler injections or who are seeking a permanent option.

I further explain to these patients that there are many advantages with fillers in that they are temporary, can be reversed, and can be used to sculpt various areas, whereas implants simply augment the entire lip and preclude sculpting individual areas. In addition, implants only provide bulk and do not provide border definition.

I always make an effort to persuade prospective lip implant patients to try temporary filler first to see how they like bigger lips before jumping directly to implants.

>> ART continued from previous

With the solid silicone or ePTFE implants, it is possible to go back and add filler for increased augmentation or for outline. It is difficult to do this with inflatable implants, however, because the needle may compromise their integrity, although it can be done with care. My basic feeling about implants is when they work, they work really well and the patient is extremely happy.

Unfortunately, like any implantable

## Psoriasis Patients Benefit from Online Support Sites

Online support sites for psoriasis sufferers offer users a valuable educational resource and a source of psychological and social support, a study found.

Shereen Z. Idriss, of the Center for Connected Health at Massachusetts General Hospital in Boston, and colleagues recruited 260 subjects (60 percent female; 76 percent white) from five online psoriasis support groups. They had a mean age of 40 years (range 18-75 years). Eighty-four percent were college educated.

Almost half of respondents said they perceived improvements in their quality of life and psoriasis severity since joining a site, the researchers reported in *Archives of Dermatology* (2009;145:46-51). In addition, 66 percent said they believed online support enabled them to gain a sense of control over their psoriasis. Intensity of participation in online support activities was associated with improved quality of life, but not with improvement in psoriasis severity, according to the investigators.

Key factors associated with use of online support sites included availability of resources (95 percent), convenience (94 percent), access to good advice (91 percent), and the lack of embarrassment when dealing with personal issues (91 percent). The most common activities were posting and replying messages (65 percent each) and searching for information (63 percent).

"Although online psoriasis support groups are still in their nascent stage, they have captured a loyal and growing audience," the authors concluded.

They also observed: "At present, these sites are operating independently of health care service providers. The dermatology community should consider leveraging the infrastructure of online support groups to build on delivering personalized and integrated medical care to individuals affected by psoriasis."

device, it is often difficult to duplicate nature, cosmetic patients are very picky and discerning, and there seems to be little middle ground with lip implants. Patients either love them or hate them.

Lip implants may gain popularity as new implant materials become available and the selection of implants grows. The placement procedure is straightforward and is easily learned.

Lip implants do occupy a place in the armamentarium of the contemporary cosmetic surgeon.

### REFERENCES

1. Anastassov GE, Schulof H, Lumerman H. Complications after facial contour augmentation with injectable silicone. Diagnosis and treatment. Report of a severe case. *Int J Oral Maxillofac Surg.* 2008;37:955-960.

2. Niamtu J. Advanta ePTFE facial implants in cosmetic facial surgery. *J Oral Maxillofac Surg.* 2006; 64:543-549.

3. Niamtu J. Experience and evaluation of a new, saline-filled implant for cosmetic lip augmentation. *Am J Cosmet Surg.* 2008;24:183-191.

4. Niamtu J. Simple technique for lip and nasolabial fold anesthesia for injectable fillers. *Dermatol Surg.* 2005;31:1330-1332.

**SOLAR PROTECTION FORMULA**

the most complete protection under the sun™

**Solar Protection Formula is available exclusively through professionals.**

For further information and samples please contact Fallene, Ltd. 800.332.5536 phone • 610.630.6202 fax  
www.fallenesolarprotection.com