

Facial Aging and Regional Enhancement With Injectable Fillers

Joe Niamtu III, DMD

Minimally invasive cosmetic facial surgery has entered into the forefront of contemporary rejuvenation. Cosmetic surgery providers are faced with growing legions of patients eager to embrace the facts (or myths) they are exposed to in the media. Astute clinicians have a firm understanding of the facial aging process and how to reverse it. Although the lips and nasolabial folds remain the most common areas for treatment with fillers, many other areas of the face can benefit from expanded scope of filler injection. Having the ability to recognize and treat these auxiliary opportunities can extend the use and functionality of injectable fillers. Also paramount with minimally invasive procedures is minimal pain. Having control over the discomfort a patient feels with these procedures translates into a better performance by the surgeon, a better experience for the patient, and the most effective form of marketing: positive word of mouth.

A new form of cosmetic surgery has taken the developed world by storm. This trend concerns minimally invasive procedures, which improve appearance without traditional surgery. There is no better illustration of the popularity of these procedures than the aging baby boomers, the first wave of whom are entering their sixth decade. This population has controlled emerging trends for more than half a century and takes the lead on antiaging efforts. Many baby boomers have reached

Dr. Niamtu is in Private Practice, Richmond, Virginia.
Dr. Niamtu has received lecture honoraria from Allergan, Inc.

their peak earning years, have disposable income, and disdain aging. This combination of money, desire for youth, and access to well-trained, multispecialty cosmetic providers has placed the contemporary cosmetic surgeon in an exciting position. Merely having an eager patient base is not enough for cosmetic surgeons to prosper at the art and science of rejuvenation. One must also be able to competently and repeatedly obtain cosmetic improvement and avoid complications. Cosmetic surgery patients are finicky and will not tolerate substandard rejuvenation; thus, the cosmetic provider who cannot deliver positive results cannot prosper. Although this mantra applies to all forms of cosmetic surgery, it is especially notable for injectable fillers, as they are so easily obtained and administered. With filler injections, patients can be in and out of the physician's office in 15 minutes.

MAKING PATIENTS LOOK YOUNGER, NOT JUST TIGHTER

The previous generation of cosmetic procedures was aimed more at tightening skin over the atrophied face. To add insult to injury, much of the remaining facial fat was removed. This was akin to removing the stuffing from an arm chair before reupholstering it. The result was an unnatural, overstretched look. Contemporary cosmetic surgery has brought about the realization of the importance of volume restoration. Advances in fillers, fat grafting, and facial implants have resulted in new interest of volume restoration for youthful facial harmony. Tightening skin is not a sin if it is performed over replenished volume.¹

FACIAL AGING AND HOW TO REVERSE IT

The study of the aging face is fascinating and is something that most people observe firsthand but at the same time cannot specifically characterize. If you ask 55-year-olds if they look older than they did 15 years ago, they will say that they do. However, if you ask them to quantify the changes that have occurred that make them look older, they may not be able to accurately describe these changes. By the same token, some practitioners have not given adequate thought to

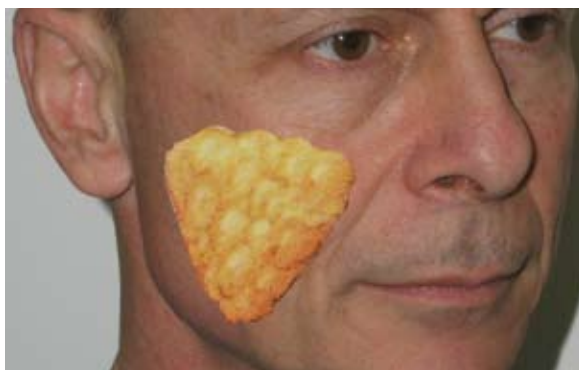

Figure 1. The approximate position of the malar fat pad in the fifth decade. The descending pad base accentuates the nasolabial fold.

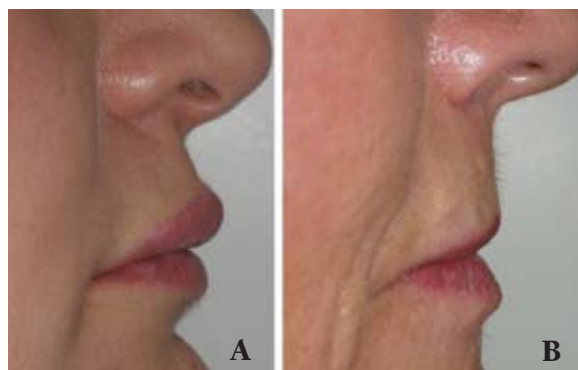

Figure 2. The youthful lip has volume and pout and is curvaceous (A), whereas the senescent lip is atrophic and becomes lengthened (B).

the specifics of the aging process. Categorizing these changes on a macroscopic level in the head and neck begins with the integumentary changes. Degenerative and actinic dermal elastosis, combined with epidermal and dermal dyschromia, produces sagging and spotted skin.^{2,3} The gravitational and histologic changes of deeper structures such as fat and muscle result in supportive ptosis of the aging skin. This, in turn, results in a loss of youthful volume and contour.

REGIONAL CONSIDERATIONS IN FACIAL AGING

Upper Face

As people age, their hair becomes gray and thin. The skull shrinks, thereby increasing the soft tissue drape of the overlying skin. In the upper face, this increase, combined with skin aging and gravitational effects, causes drooping of the brows and dermatochalasis of the upper eyelids. Orbital septal weakening causes protrusion of periorbital fat, which, in turn, contributes to loss of definition of the youthful upper eyelid. In the lower eyelid, the same periorbital fat protrusion causes bags, and the thin eyelid skin is subject to dermal and actinic aging, causing crepe and wrinkled skin. The chronic contraction of the mimetic muscles produces dynamic lines in the upper face that are perpendicular to the underlying muscles. These well-known lines manifest as horizontal forehead wrinkles, glabellar frown lines, and lateral canthal rhytides.

Mid Face

Midfacial aging changes are too often overlooked by cosmetic surgeons. The most striking changes in the mid face result from volume loss. This change in midfacial volume is manifested when the cheek and periorbital fat (suborbicularis oculi fat and malar fat) become atrophic and descend into the lower face, creating jowls and contour irregularities.⁴ This produces the hollow look of the aging mid face. In addition, the sagging

malar fat pad increases the depth of the nasolabial folds and the mandibulolabial folds. The youthful malar fat pad is triangular in shape, with the base paralleling the nasolabial fold and its apex in the malar region.⁵ With the descent of the malar fat pad base, the nasolabial fold becomes thickened (Figure 1).

Lips

Aging affects the lips in many ways.^{6,7} The lip tissues atrophy with age, which contributes to volume loss. The loss of dental structure causes overclosure of the mandible, which, in turn, affects the natural tissue drape of the lips on the incisor teeth. The reduction of this support contributes to the flatter appearance of the aging lip. In addition, the upper lip becomes elongated with aging and contributes to the loss of volume and youthful structure (Figure 2).⁸ This may be even more accentuated by aging changes in the nasomaxillary complex, where the nasal cartilage separates from the bone interface and produces an effect that causes the nasal tip to droop.

Lower Face

The complex changes that occur in the lower face include the loss of mandibular vertical dimension. In youth, the teeth occupy a given space in the lower face. As we age, natural attrition occurs, and we lose tooth structure and alveolar bone (the cancellous bone supporting the teeth) support. This causes a relative overclosure of the mandible in that the jaw closes more in the older patient. The result is loss of support for the mid face and lower face, which is grossly obvious in the patient without teeth (edentulous). These changes go less noticed in the patient with teeth (dentate).

The more the jaw overcloses, the more the excess soft tissue is accentuated in the midface, perioral, and jowl areas. Degenerative changes in the mandibular condyles of the temporomandibular joint can produce a retrognathic profile, diminishing chin

FACIAL AGING

projection. The loss of this scaffolding causes increased soft tissue drape, which also contributes to the loss of chin projection. These changes, combined with jowl formation, merge with other changes in the submental and upper cervical areas. The hyoid bone descends with aging, thus weakening the associated cervical muscular attachments. Senescent submental and cervical fat deposition, combined with platysma dehiscence and skin elastosis, further exacerbate amorphogenesis of the chin, submental, and cervical regions. These changes produce the dreaded “turkey neck,” among the most notable and feared changes of aging.

SPECIALIZED INJECTABLE TREATMENT OPTIONS: REGIONAL ENHANCEMENT OF THE AGING FACE

There are some specialized and unique antiaging conditions and treatment options that may be outside the mainstream diagnosis and treatment of many clinicians. The combined use of surgical brow-lifting and forehead-lifting, cosmetic blepharoplasty, and botulinum toxin injection may make significant differences in upper facial rejuvenation. Several nonsurgical options are also available.

Brow-lifting

The author questions those practitioners who claim to achieve significant, lasting, and repeatable brow-lifting in patients through the use of botulinum toxin. It is a fact that some patients exhibit elevated brows after selective treatment of the depressors, but the author feels that it is a fact that it is easier for patients to elevate their brows with the depressors deactivated. In most before and after photos that attempt to show brow elevation following botulinum toxin treatment, patients are actually raising their brows. This may be subconscious or subliminal, or the lifting may be easier once the depressors do not act as antagonists. So let us say that by deactivating the brow depressors and selectively treating the frontalis, some effect of brow elevation may be noted, whether repeatable or not. To believe that the untreated frontalis will pull up the brows (after depressor suppression) like a garage-door spring goes against the grain of scientific thinking. The author feels that these changes are more of an illusion similar to how a woman wearing rouge appears to have higher cheek bones. To say that rouge elevates the cheeks is obviously incorrect. Regardless of what one believes about nonsurgical brow-lifting, most agree that some nonsurgical treatments improve or provide the illusion of improving brow position. Injecting the depressors (procerus and corrugators) while leaving the lateral frontalis untreated provides, in theory, a balance of brow and forehead activity that gives the appearance of an elevated brow.

This treatment may be facilitated by understanding and treating the lateral orbicularis oculi fibers. This is a bit different from the garage-door-spring theory of brow elevation, as it relies not on the frontalis pulling the lateral brow up but more on stopping the lateral orbicularis from pulling it down. Figure 3 illustrates that the frontalis muscles end at the temporal crest and the lateral eyebrow extends past this point. So, effectively, there is no frontalis muscle over the most lateral portion of the brow to elevate it. There is, however, strong orbicularis oculi musculature that overlies this area and can pull the brow downward. By injecting these lateral orbicularis fibers with targeted botulinum toxin, the brow is less likely to be pulled downward and may assist with lifting.

Another means of facilitating the actual elevation of the lateral brow (or, again, providing the illusion of elevation) is to inject filler over the lateral brow. This may cause some minor physical lifting but more correctly provides bulk (volume restoration) in a sagging area. The 3-dimensional effect of fillers must be appreciated in that injection causes projection. This fullness and projection cause the illusion of brow elevation.

Nasojugal Groove (Tear Trough) Deformity

It is notable that mainstream nonsurgical treatment of the nasojugal groove is a relatively new phenomenon. The nasojugal groove is a result of the aging changes

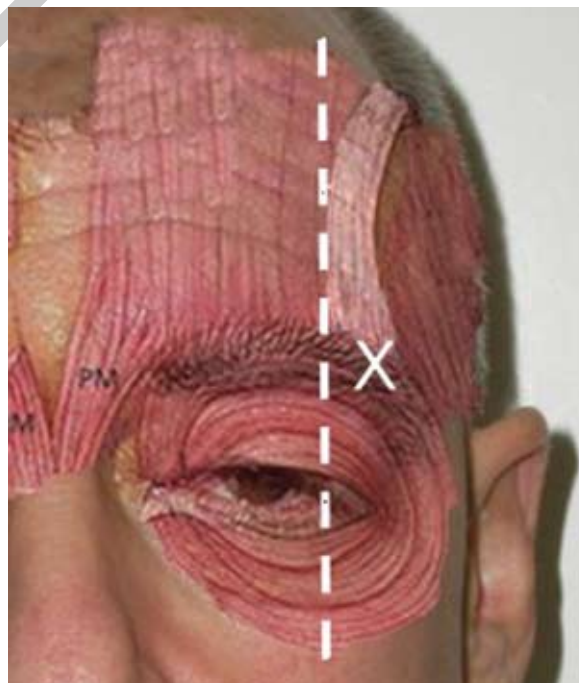


Figure 3. The frontalis terminates at the temporal crest, and the lateral brow extends beyond the temporal crest. Because of this relationship, there are no frontalis fibers to elevate the lateral brow, and by injecting the lateral orbicularis fibers with botulinum toxin, the downward pull of the lateral orbicularis is mitigated.

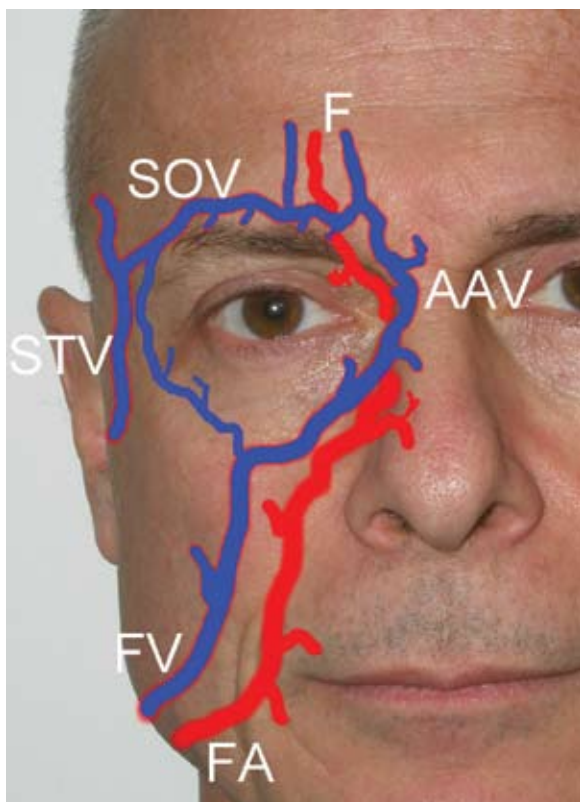


Figure 4. The approximate position of the main blood vessels of the face. AAV indicates angular artery and vein; F, frontal; FA, facial artery; FV, facial vein; SOV, supraorbital vein; and STV, superficial temporal vein.

of the lower eyelid and resultant volume loss, with the inferior orbital rim becoming visible and accentuated by the protruding lower eyelid fat and the descent of the suborbicularis oculi fat. Treatment of this area has recently received much attention. Eyelid surgeons are removing less lower-lid fat and incorporating volume replacement as part of their treatment.⁹ Some trepidation may exist for the novice injector when treating this area. Potential catastrophic complications, such as inadvertent globe penetration or intravascular injection, must be considered in this area.¹⁰ Another caveat, as mentioned previously, is that the eyelid skin is extremely thin and may be translucent; thus, the filler may be visible. Most injectors consider deep injection over the periosteum preferable for safety and result. With experience, the injection plane may include the suborbicularis oculi plane, and the filler may be somewhat layered in this area. When injecting this area, a finger is placed on the inferior orbital rim to continually protect the globe. As this is an extremely vascular area as well, bruising and potential intravascular injection must be considered. The major vascularity of the periorbital area is shown in Figure 4 and should be considered when treating this area. Finally, this area is prone to postinjection ecchymosis, and injecting

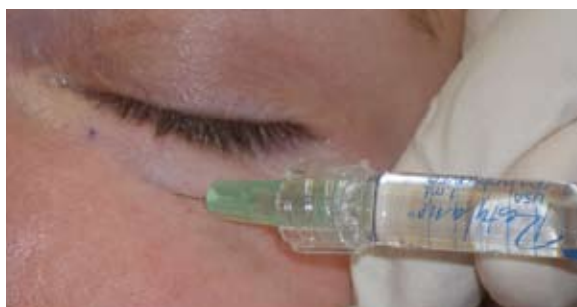

Figure 5. The tear trough region is augmented by injecting filler at the periosteum and avoiding placement of significant filler superior to the orbicularis oculi musculature.

along the rim with fewer punctures is beneficial. In the author's experience, inserting the needle somewhat horizontal to the rim and performing a linear threading technique provides less bruising than multiple serial puncture needle sticks (Figure 5).

The author performs a transcutaneous infraorbital local anesthetic block before filler injection.¹¹ This is achieved by using a 1.2-in, 32-gauge needle inserted in the papillary midline 5 to 8 mm below the inferior orbital rim (Figure 6). Figure 7 shows a patient before and after tear trough injection.

An infraorbital local anesthetic block is effective for nasojugal groove treatment. It is important to use a small amount of anesthesia to not distort the soft tissue and hence affect filler injection accuracy.

Nasal Deformities

Addressing nasal deformities with injectable fillers has gained popularity with the evolution of this wonderful branch of nonsurgical treatment. The topic of illusion once again comes into play. A prominent nose or one with outstanding features may detract from cosmesis or accentuate aging. Experienced chin and rhinoplasty surgeons have long realized that augmenting a deficient chin may make the nose look smaller. The author has noticed this effect many times when placing chin implants in patients with mandibular hypoplasia or microgenia. Patients often desire rhinoplasty and chin augmentation, but after seeing the successful outcome of chin augmentation in the vertical and horizontal plane, they may feel that the nose looks proportionate. An enlarged dorsal hump is a common cause for cosmetic rhinoplasty and in minor cases may be disguised or camouflaged by adding volume in the depression above the hump with injectable fillers. The filler is placed in the deep dermal or subcutaneous plane until the predorsal hump depression (in the area of the radix) is filled to the desired result (Figure 8). This small correction produces frontal and profile changes that render the illusion of a smaller dorsal hump.

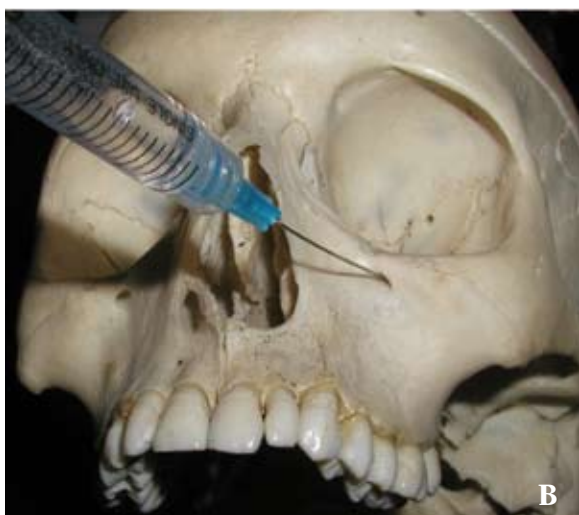
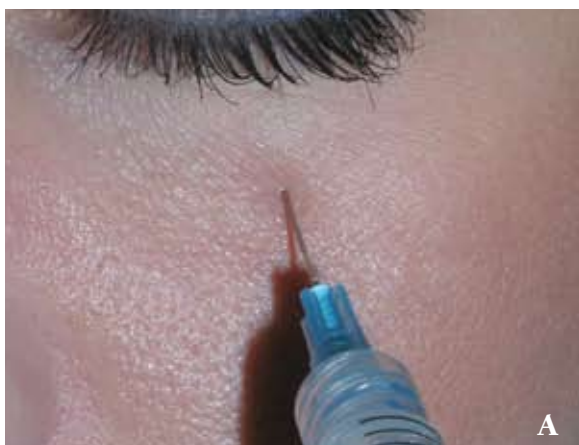
Figure 6. An infraorbital block may anesthetize the lower lid, upper lip, and lateral nose and is performed by anesthetizing the nerve 5 to 8 mm below the inferior orbital rim in the papillary midline. The cutaneous approach (A) and osseous rendition (B) are shown. Reprinted from Niamtu J. *Cosmet Dermatol.* 2004;17:583-587. ©2004, Quadrant HealthCom, Inc.

Zygomatocomalar Complex

The zygomatocomalar complex provides cheek definition in the youthful face. This bony support, combined with adequate submalar and suborbicularis oculi fat volume, is a defining hallmark of youth. Many injectors fail to realize the importance of this area in facial rejuvenation. Augmentation of this area has been successfully performed with lifting procedures, implants, and fillers.⁴ Each modality has its pros and cons, and the discussion here is limited to filler injection. Despite the popularity of the hyalurons, other fillers have evolved for deeper tissue injection that may provide more robust, longer-lasting results. These fillers are intended for deeper injection, usually in the subcutaneous tissue or sometimes in the deep dermis. Calcium hydroxylapatite, injectable poly-L-lactic acid, purified polydimethylsiloxane (silicone), polymethyl methacrylate, and autologous fat are fillers that may be used for

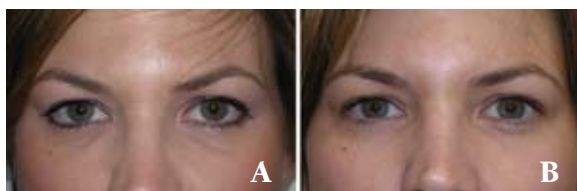

Figure 7. Patient before (A) and after (B) treatment with approximately 1.5 cc of hyaluronic acid filler in the tear trough areas.

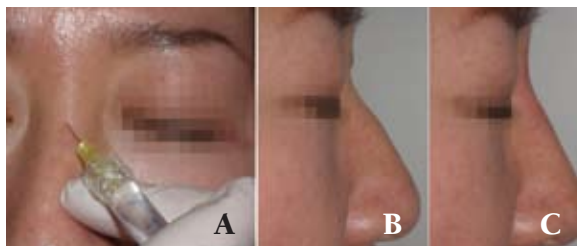


Figure 8. Improvement of a dorsal hump may be performed by placing filler in the nasal radix (A). The difference before (B) and after (C) treatment is shown.

deep injection in this area. Larger-particle hyalurons can also be used for midfacial augmentation in this area. These fillers may be layered over, or used in place of, the aforementioned deep fillers.⁷ A main concern for the novice injector is knowing exactly where to inject the midfacial filler to best enhance the zygomatocomalar complex region. Although the desired area of augmentation may be subject to the preferences of the patient and the practitioner, classic areas of volume are recognized in the youthful mid face. To approximate this desired region of augmentation, the author uses anatomic silicone midface implants as tracing templates to define the desired region of augmentation. Figure 9 shows a silicone cheek implant used as a template to guide the injector in where to deposit the filler. It is best to define this treatment as a sculpting process, where the surgeon and patient agree on multiple injection-sculpting sessions until a mutually satisfying result is reached. This allows better control than planning for a single treatment session.

Although injecting over the malar prominence and a portion of the zygomatic arch is usually desirable, filling the submalar space provides specific and usually much-needed volume replacement. This is an important area to consider in facial rejuvenation, and many patients (and surgeons) are unaware of this senescent volume deficit. Extensive filler injection in the zygomatocomalar complex and submalar regions can be expensive, and cheek implants may serve as a more cost-effective means of providing volume replacement in this important area.

Nasolabial and Mandibulolabial Folds

When discussing the nasolabial fold, it is important to mention that it is an anatomically complex structure

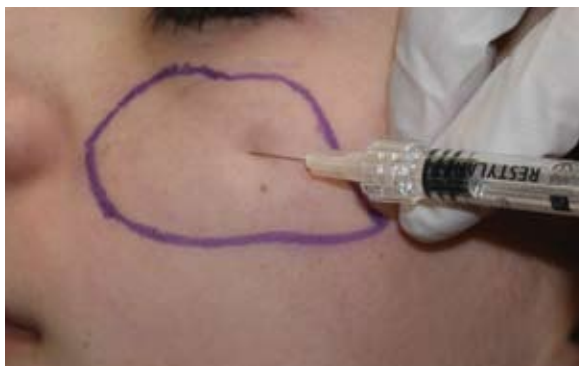

Figure 9. A silicone implant is positioned over the cheek and traced with a marking pen. The drawing is then used as a template to guide the filler injection.

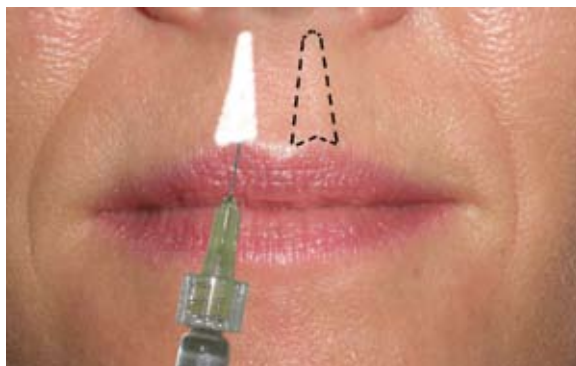


Figure 11. Enhancing the philtral columns, which can provide the appearance of a more youthful lip, is often overlooked by injectors. Shown here is the approximate filler placement.

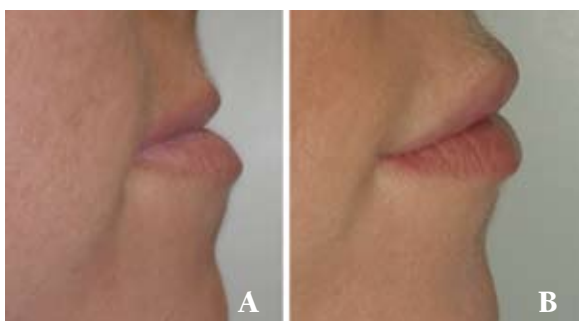


Figure 10. Patient with maxillary hypoplasia and poor lip support (A). Augmenting the upper lip with Restylane® helped to normalize the prognathic profile (B).

(more accurately called a *crease* by some) that is influenced by the merging of multiple tissue planes as well as the underlying bone. When injecting most facial rhytides, the injector may frequently inject in the central valley of the rhytide to achieve fill. In the nasolabial fold, it is common for the filler to flow laterally when injected in the center of the fold valley. If the filler does flow laterally, it may thicken the lateral portion of the fold and actually make the fold bigger (or provide the illusion of increased size). This is frustrating to the patient and usually to the novice injector. To prevent this lateral migration, it is important for the injector to carefully observe the actual direction of flow when injecting into the nasolabial folds. If the filler appears to be migrating laterally, the injector may correct this by repositioning the injection needle site more medially to the fold.

Perioral Considerations

The lips are perhaps the area most commonly injected with fillers. It is notable to mention specialized considerations pertaining to the lips and perioral area. Maxillary hypoplasia is a condition in which the anterior growth of the maxilla is affected. This results in a flat mid face and may cause a flat lip profile. In addition, dental problems such as malocclusion may

affect normal lip support rendered by anterior dentition. These patients may exhibit a prognathic profile from loss of lip support, cheek support, or both. By augmenting the upper lip vermilion and the cutaneous portion of the upper lip, profile enhancement may be achieved. Figure 10 shows a patient with maxillary hypoplasia who exhibits a prognathic profile. This is corrected by increasing the volume of the cutaneous and vermilion areas of the upper lip.

The youthful aesthetic lip possesses a well-defined philtrum and philtral columns. This distinct anatomy is lost with aging, and some individuals never possess adequate definition in this area. Failure to diagnose and address deficiencies in the philtral area is common, even with experienced injectors. The actual philtrum is a depression bounded by well-defined columns on each side. The philtral columns are pyramidal, with the base being larger at the vermilion cutaneous junction. Older patients may need the entire column re-created, whereas younger patients may require only filler injection at the vermilion cutaneous junction instead of the entire length of the upper lip. Figure 11 shows approximate filler placement in this area.

The senescent lip presents one of the greatest challenges for cosmetic surgeons. With all of the aforementioned aging changes, the lips become amorphous and void of shape and definition. By recognizing the changes of aging and how to reverse them, a cosmetic practitioner may rejuvenate a patient by proper lip injection techniques (Figure 12).

Prejowl Sulcus

In patients with early jowling, a depression is formed at the inferior border of the mandible just posterior to the jowl (Figure 13). Filler material may be injected in the deep dermis or the subcutaneous level to make the prejowl sulcus less noticeable. This may also be performed with specialized chin implants that have increased bulk, corresponding to the prejowl sulcus.

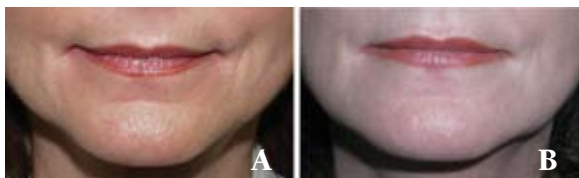

Figure 12. Patient before (A) and after (B) treatment with injectable fillers to augment the prejowl sulcus, located lateral to the chin and medial to the jowl.

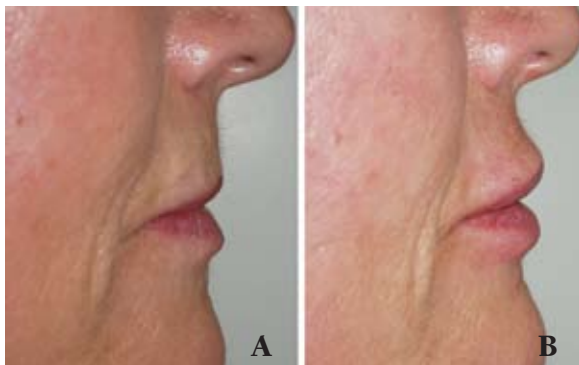

Figure 13. The senescent lip becomes void of form and presents challenges to the injector (A). Comprehensive understanding of volume restoration may lead to rejuvenated lips (B).

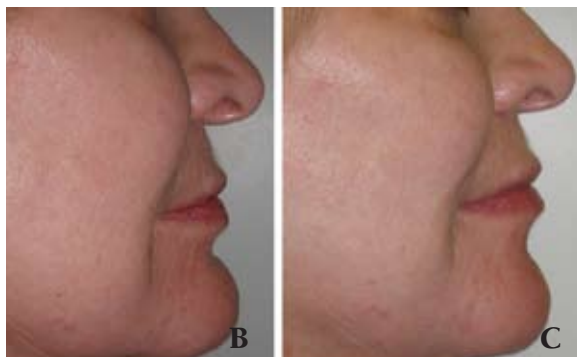
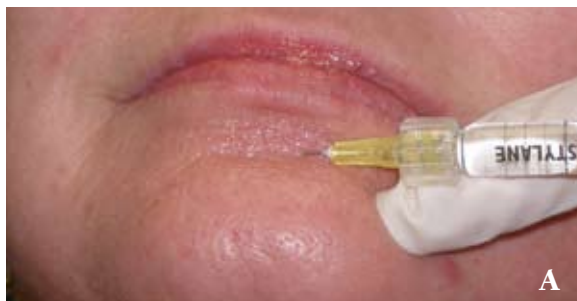
Figure 14. Injecting filler into the mentolabial fold to enhance the lower facial profile (A). The difference before (B) and after (C) treatment is shown.

Mentolabial Fold Enhancement

An often-overlooked area of filler injection is the mentolabial fold. This area may be injected to improve the natural crease that forms with aging. Fillers may also be used to treat patients who have chin or lip deformities. A relatively common facial deformity is vertical mandibular deficiency, sometimes referred to as short face syndrome. This condition occurs when the normal vertical chin height is deficient, producing a short chin with a floppy lip that overhangs on the soft tissue chin (Figure 14).

CONCLUSION

The science of injectable facial fillers has undergone exponential changes over the past decade, and the future promises to be even more exciting. Understanding the effects facial aging has on various anatomic units, as well as the possibilities of correcting these conditions, is the crux of minimally invasive cosmetic facial surgery. The contemporary facial cosmetic practitioner should always be observant to aging changes in all areas of the head and neck and be familiar with common modes of treatment. Understanding the possible danger zones and potential complications associated with injectable facial fillers is also requisite for safe, effective, long-lasting treatment.

REFERENCES

1. LaTrenta GS. The aging face. In: *Atlas of Aesthetic Face and Neck Surgery*. Philadelphia, Pa: Saunders; 2004:46-66.
2. Rubin MG. Photoaged and photodamaged skin. In: *Manual of Chemical Peels: Superficial and Medium Depth*. Philadelphia, Pa: JB Lippincott Co; 1995:1-16.
3. Obagi S. Lifetime skin care. In: *Cosmetic Facial Surgery, an Issue of Oral and Maxillofacial Surgery Clinics of North America*. Philadelphia, Pa: WB Saunders; 2000:531-541.
4. Niamtu J III. The adjustable vector deep plane midface lift. *Atlas Oral Maxillofac Surg Clin North Am*. 2004;12:199-214.
5. Niamtu J III, Chisholm B. The adjustable vector deep plane midface lift. *J Oral Maxillofac Surg*. 2004;62:630-637.
6. Werschler WP. Advanced injection techniques of poly-L-lactic acid: a case-based presentation. *Dermatol Ther*. 2007;20 (suppl 1):S16-S19.
7. Niamtu J. New lip and wrinkle fillers. In: *Minimally Invasive Cosmetic Surgery, an Issue of Oral and Maxillofacial Surgery Clinics*. Philadelphia, Pa: Saunders; 2005:17-27.
8. Perenak J. Treatment options to optimize display of anterior dental esthetics in the patient with the aged lip. *J Oral Maxillofac Surg*. 2005;63:1634-1641.
9. Nassif PS. Lower blepharoplasty: transconjunctival fat repositioning. *Facial Plast Surg Clin North Am*. 2005;13: 553-559.
10. Engelman DE, Bloom B, Goldberg DJ. Dermal fillers: complications and informed consent. *J Cosmet Laser Ther*. 2005;7:29-32.
11. Niamtu J, Carruthers J. Pain control in cosmetic facial surgery. In: Carruthers J, Carruthers A, eds. *Soft Tissue Augmentation*. Philadelphia, Pa: Elsevier Saunders; 2005:147-159. *Procedures in Cosmetic Dermatology*. ■