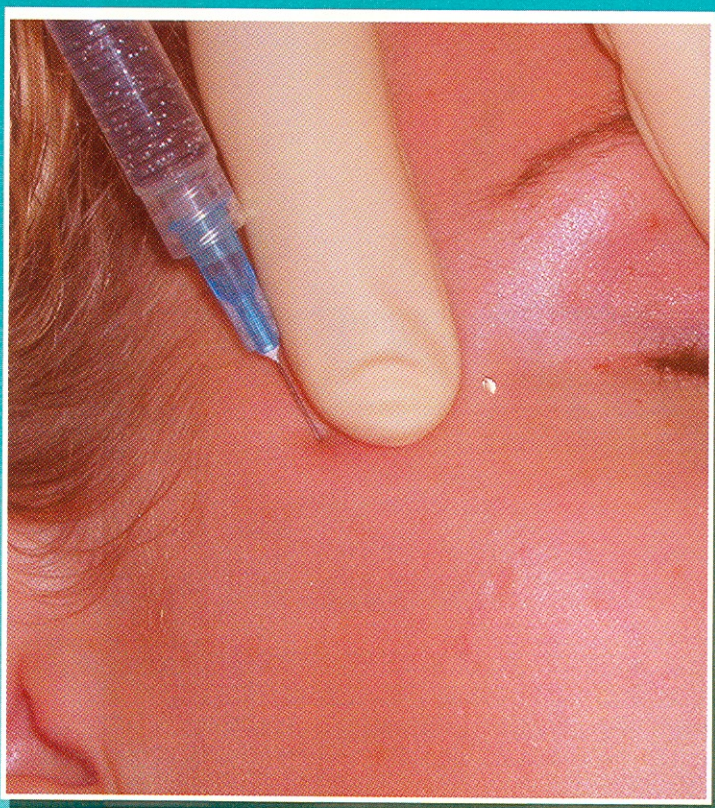

cosmetic DERMATOLOGY®

A P E E R - R E V I E W E D J O U R N A L October 2004 Volume 17 No. 10



Atypical Mycobacterial
Outbreaks Associated
With Cosmetic Surgery

Local Anesthetic Blocks:
Techniques for the
Maxillary Nerve

Biologic Agents for
Psoriasis: A Primer

Cosmeceutical Reduces
UV-Induced Erythema

The Official Publication of the
AMERICAN SOCIETY OF
COSMETIC DERMATOLOGY
AND AESTHETIC SURGERY

Local Anesthetic Blocks of the Head and Neck for Cosmetic Facial Surgery, III: Techniques for the Maxillary Nerve

Joseph Niamtu III, DMD

Part I of this series reviewed the basic sensory neuroanatomy of the head and neck, and Part II detailed local anesthetic techniques for the upper and mid face. This article focuses on the maxillary nerve, also referred to as the second division of the trigeminal nerve. It describes specific techniques for local anesthetic blocks of the branches of the maxillary nerve, and a simple technique for a total block of the maxillary nerve.

ZYGOMATICOTEMPORAL AND ZYGOMATICOFACIAL NERVE BLOCKS

Two often overlooked nerves in local anesthetic blocks for the face are the zygomaticotemporal and zygomaticofacial nerves. These nerves represent terminal branches of the zygomatic nerve, which is the primary branch of the maxillary nerve. The zygomaticotemporal nerve emerges through a foramen located on the anterior wall of the temporal fossa. This foramen is actually behind the lateral orbital rim posterior to the zygoma at the approximate level of the lateral canthus (Figure 1).

The injection technique for blocking the zygomaticotemporal nerve involves sliding a 1.5-inch needle behind the concave portion of the lateral orbital rim. Closely examining this area on a model skull before attempting this injection will make the technique simpler. Locate the precise point of injection by palpating the lateral orbital rim at the level of the frontozygomatic suture (which is frequently palpable). With the index finger in the depression of the posterior lateral aspect of the lateral orbital rim (inferior and posterior to the frontozygomatic suture), place the needle just behind the palpating finger (which will place it about 1 cm posterior to the frontozygomatic suture) (Figure 1A). Next, "walk" the needle down the concave posterior

wall of the lateral orbital rim to the approximate level of the lateral canthus (Figures 1B and 1C). After aspirating, inject 1 to 2 cc of 2% lidocaine with 1:100,000 epinephrine in this area with a slight pumping action to ensure deposition of the local anesthetic solution at or about the foramen. Again, it is important to hug the back concave wall of the lateral orbital rim with the needle when injecting.

Blocking the zygomaticotemporal nerve produces anesthesia in the area superior to the nerve including the lateral orbital rim and the skin of the temple from above the zygomatic arch to the temporal fusion line (Figure 2).

The zygomaticofacial nerve exits the bone through a foramen (or foramina in some patients) in the inferior lateral portion of the orbital rim at the zygoma. It emerges several millimeters lateral to the junction of the inferior lateral portion (or, the most southwest portion of the right orbit, if you will) of the lateral orbital rim. By palpating this junction and injecting just lateral to the finger, this nerve can be successfully blocked with 1 to 2 cc of local anesthetic solution (Figure 3). Blocking this nerve produces anesthesia of a triangular area from the lateral canthus and the malar region along the zygomatic arch and some skin inferior to this area (Figure 2).¹

TOTAL MAXILLARY NERVE BLOCK

The maxillary nerve arises from the gasserian ganglion in the medial cranial fossa and exits the skull via the foramen rotundum, coursing its way through the greater palatine foramen (Figure 4C). The nerve then traverses

Dr. Niamtu is in private practice, specializing in oral/maxillofacial and cosmetic facial surgery in Richmond, Virginia.

The author reports no actual or potential conflict of interest in relation to this article.

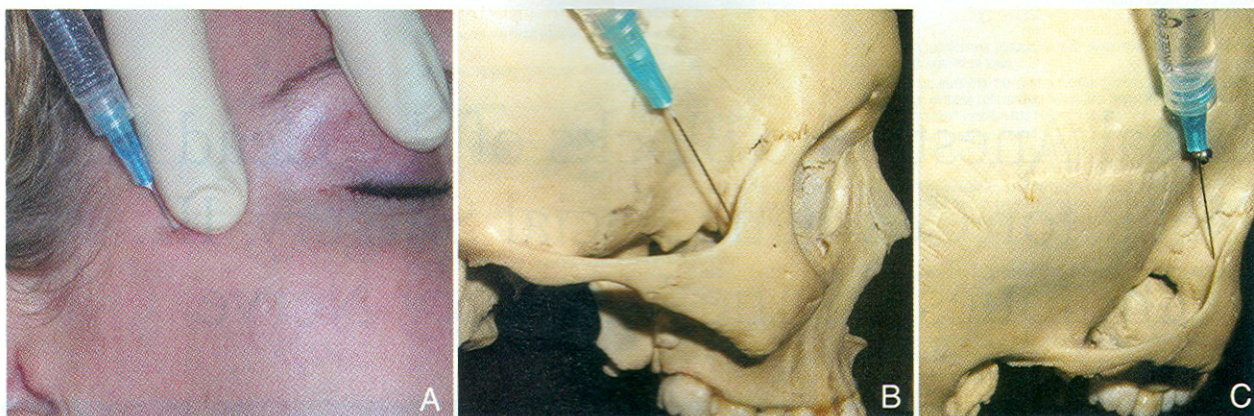


Figure 1. The zygomaticotemporal nerve is blocked by placing the needle on the concave surface of the posterior lateral orbital rim (A, B, and C).

the superior aspect of the pterygopalatine fossa, where it divides into 3 major branches: the pterygopalatine nerve, the infraorbital nerve, and the zygomatic nerve.² Blocking these 3 major nerves and their terminal branches will anesthetize the entire hemi maxilla and the unilateral maxillary sinus, providing hemi-mid facial local

anesthesia. This efficient, easily learned technique involves an intraoral approach at the posterior lateral palate (Figure 4).

The maxillary nerve block via the greater palatine canal was first described in 1917 by Mendel et al.³ The greater palatine foramen is located anterior to the junction of the hard and soft palate, medial to the second molar tooth (Figure 4B). This foramen is usually found about 7 mm anterior to the hard and soft palate junction. This junction is seen as a color change, where the tissue overlying the soft palate is a darker pink than the tissue overlying the hard palate (Figure 4A). The key to this block is to place a 1.5-in needle through the greater palatine foramen. Because multiple needle sticks may be necessary to localize the foramen, the palatal mucosa in this area first should be infiltrated with 0.5 cc of lidocaine to facilitate painless location of the greater palatine foramen. A 1.5-in 25-gauge or 27-gauge needle bent to a 45° angle will usually negotiate the pterygopalatine canal easily, thereby placing the local anesthetic solution into the pterygopalatine fossa.

When the foramen is located, the needle should be gently advanced. If significant resistance is encountered, the needle should be withdrawn and redirected. Approximately 5% of the population has been shown to have tortuous canals that impede the needle tip and in some patients this technique is not possible.⁴ It is also important to aspirate before injecting to prevent intravascular injection. When the needle is properly positioned (usually at a depth of 25–30 mm), the injection (2–4 mL) should proceed for 30 to 45 seconds.

Transient diplopia of the ipsilateral eye may occur.⁵ This results from the local anesthetic diffusing superiorly and medially to anesthetize the orbital nerves. The patient should be assured that if this phenomenon occurs, it is transient.

This technique will anesthetize all the terminal branches of the maxillary nerve with a single injection.

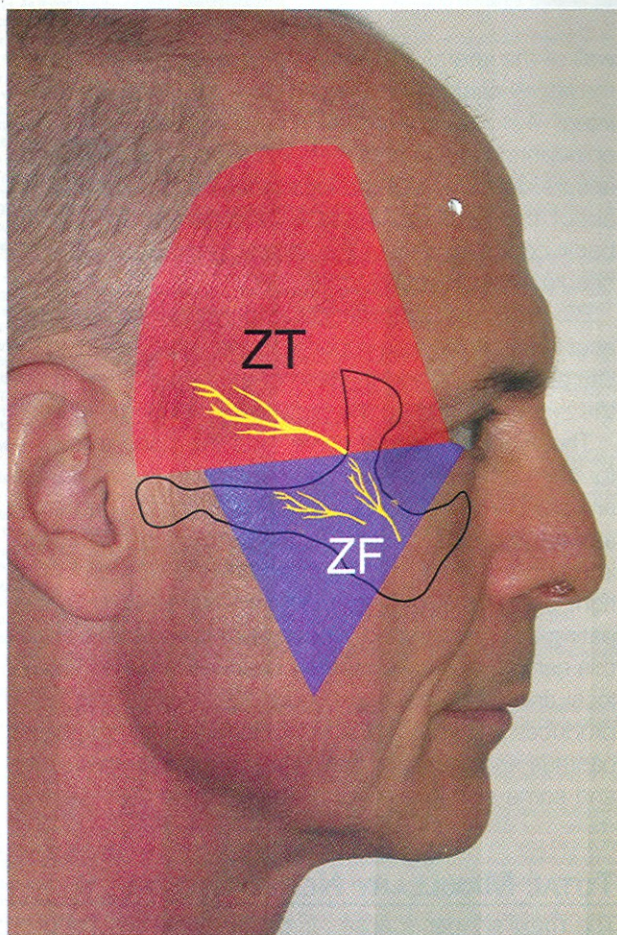


Figure 2. The anesthetized areas of the zygomaticotemporal (ZT) nerve and the zygomaticofacial (ZF) nerve.

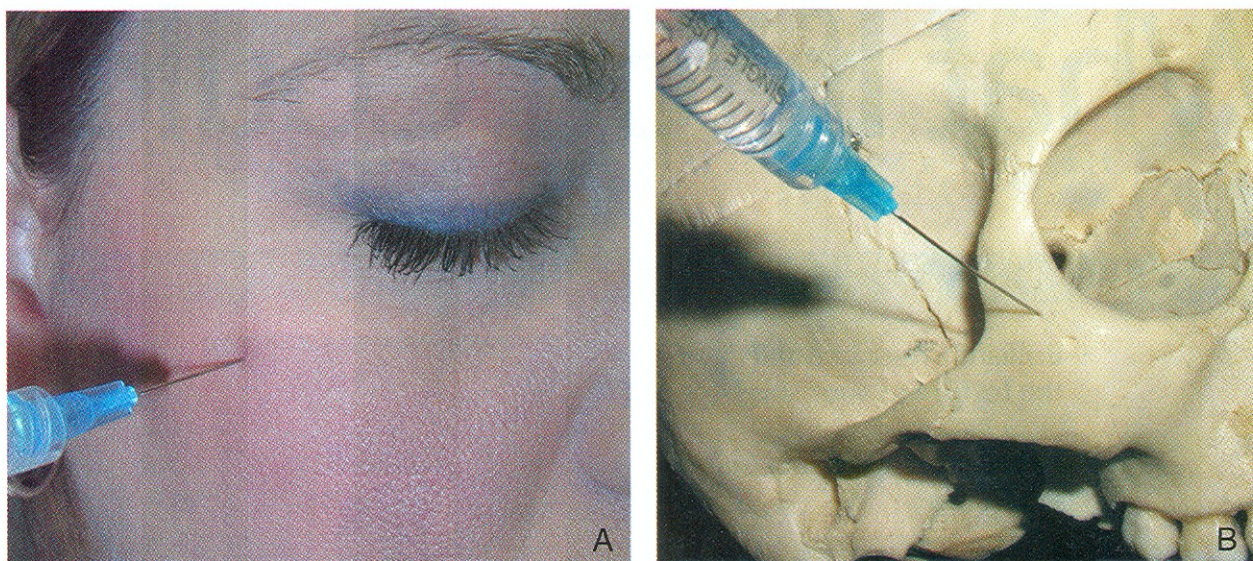


Figure 3. The zygomaticofacial nerve is blocked by injecting the inferior lateral portion of the orbital rim (A and B).

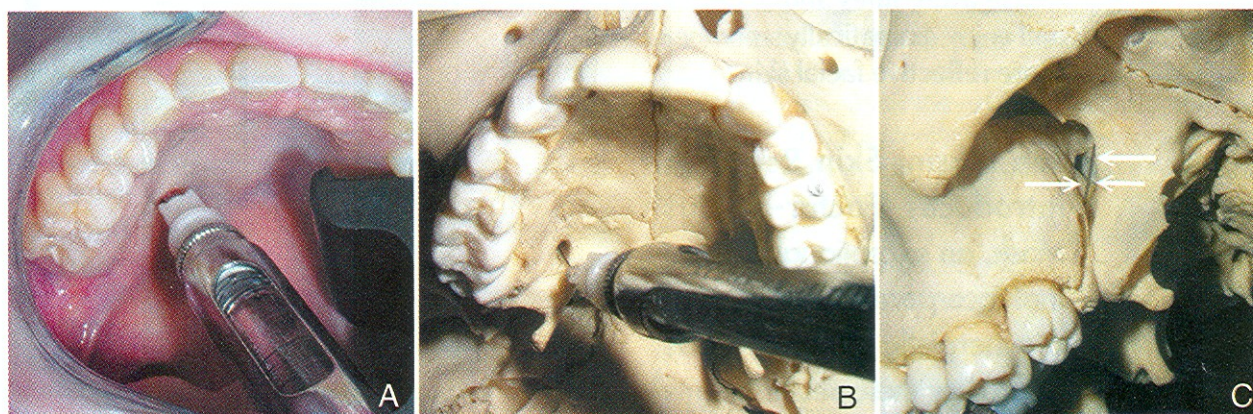

Figure 4. The maxillary nerve block is performed by locating the greater palatine foramen (A) and inserting a bent needle up the pterygopalatine canal (B) to inject local anesthetic into the pterygopalatine fossa (C). The needle tip is in the pterygopalatine fossa (C). As the maxillary nerve traverses this area, it is blocked at the main trunk.

COMMENT

Local anesthetic nerve blocks of the maxillary nerve have many uses in cosmetics, pathology, and trauma. By observing the anatomy of a demonstration skull and correlating landmarks with described techniques, these nerves can be successfully blocked and enhance pain control in the mid face for a multitude of procedures.

Part IV of this series will detail blocking the third division of the trigeminal nerve, the mandibular nerve.

REFERENCES

1. Zide BM, Swift R. How to block and tackle the face [published correction appears in *Plast Reconstr Surg*. 1998;101:2018]. *Plast Reconstr Surg*. 1998;101:840-851.
2. Mercuri LG. Intraoral second division nerve block. *Oral Surg Oral Med Oral Pathol*. 1979;47:109-113.
3. Mendel N, Puterbaugh PG. *Conduction, Infiltration and General Anesthesia in Dentistry*, 4th ed. Brooklyn, NY: Dental Items of Interest Publishing Co; 1938:140.
4. Westmoreland EE, Blanton PL. An analysis of the variations in position of the greater palatine foramen in the adult human skull. *Anat Rec*. 1982;204:383-388.
5. Malamed SF, Trieger N. Intraoral maxillary nerve block: an anatomical and clinical study. *Anesth Prog*. 1983;30:44-48.