

# PSP

PLASTIC  
SURGERY  
PRODUCTS

SOLUTIONS FOR YOUR PR

PlasticSurgeryProductsOnline.com

SEPTEMBER 2006

## Trail Blazer

*Jeffrey N. Thaxton, MD, the lone plastic surgeon in Vail, Colo, treats everyone—from cancer victim to injured skier*

**Rhinoplasty and  
Sinus Surgery**

**Lower-Face Implants**

**Physician Extenders**



# Implants for the Lower Face

by Joseph Niamtu III, DMD

This often-overlooked option can help rejuvenate the face without producing a “tight” appearance

**N**o one can argue that aesthetic facial surgery has made leaps and bounds in treatment philosophies, biomaterials, and technologies in recent years. One significant goal that has emerged is the desire to make patients look younger, not just tighter. A skeletonized appearance resulting from the lack of volume restoration was common several decades ago, but the highly educated public is on to this look and wants to avoid it at all costs.

Today's patients are sophisticated—largely because information is so readily available on the Internet—and are increasingly demanding. They seek out surgeons who will provide natural-looking rejuvenation. The goal is no longer just to look “younger”; rather, it is more focused on looking as young as one can, considering his or her age. Nothing complements this desired natural result more than adding volume to the face; and nothing is easier, more predictable, and longer lasting than facial implants.

It is surprising how many renowned surgeons perform meticulous upper and lower facial rejuvenation but pay little attention to the midface and mandibular regions. Many techniques for increasing facial volume are available to the aesthetic surgeon, including alloplastic implants, fat injections, facial fillers, osteotomy procedures, and lifting techniques (see the bibliography at the end of this article). In this article, I will deal specifically with alloplastic lower facial implants.

When I first began using facial implants 25 years ago, my choices were limited. Although some prefabricated implants were available, many surgeons made their own by carving blocks of silicone rubber, rolling up polyester fiber mesh, or using other available alloplastic materials.

## The Right Shape

The appearance of prefabricated implants significantly increased the treatment options, provided a more natural look, and simplified their placement. Some newer materials—such as expanded polytetrafluoroethylene (ePTFE)—were significant improvements, but others proved problematic. The introduction of “anatomical” implants added the benefit of 3D volume and more harmonious positioning. Finally, CAD/CAM computer technology added the benefit of precise customization for aesthetic and reconstructive indications.

Now more than ever, the array of implant shapes, sizes, and materials provides the surgeon with a host of treatment options. I place midface or chin implants—or both—in the vast majority of my facelift patients, and I believe that this is one of the most overlooked options available to surgeons and patients. Using submalar, malar-shell, and combination implants in the midface can address 99% of volumetric concerns in this area.

The appreciation of profile enhancement and volume enhancement in the

lower face is similarly often overlooked. Mandibular hypoplasia, microgenia, and mandibular retrognathia are present in a large segment of the population. True mandibular horizontal deficiency (sometimes coupled with vertical deficiency) can “rob” the patient of a normalized lower face.

Small changes in the chin can lead to significant aesthetic results. This is especially true in patients with low-setting hyoid anatomy in which the hyoid position is inferior and anterior, creating an oblique—and unaesthetic—cervicomental angle. In these patients, even with anterior cervical laxity, pulling the skin back with a facelift does not produce optimum results.

By simply adding a chin implant, the horizontal mandibular length is changed to increase the distance from the chin tip (menton) to the hyoid and the appearance of the cervicomental angle is normalized. Performing a rhytidectomy without the chin implant on the same patient would lead to an aesthetically compromised result.

Many surgeons advocate significant mandibular body and angle implants along with chin implants, and in essence they are increasing the mandibular outline for the entire lower face. I believe that this is excessive; many of these patients look “blocky” or square-faced. Some surgeons have gone so far as to say that this is the new contemporary face of aesthetic surgery.

## Implants for the Lower Face

### Before & After

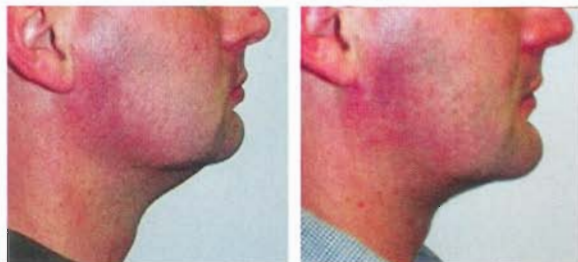

Figure 1: This patient should have undergone vertical lengthening of the chin to avoid this poor postoperative result.

In my experience, less is sometimes more, and patients still appreciate gentle curves. Obviously, beauty is in the eye of the beholder, so whatever makes patients happy and helps the business grow is appropriate. The use of mandibular-angle implants can be a viable option for patients who lack curvature and volume in the masseteric, ramus, and mandibular angle regions. Some patients have mandibular borders that disappear posteriorly, and enhancing this region can provide significant benefit.

### Implant Choice

Many alloplastic implant choices exist; their pros and cons are beyond the scope of this article. One precaution is that no implant should be placed that is difficult to remove. One of the powerful selling points for facial implants is that the procedure to place them is reversible, and they can be removed or adjusted should the patient desire to do so.

Any surgeon who has removed implants that encourage maximum tissue ingrowth can attest to the difficulty and sometimes destruction that accompanies their removal. I prefer silicone or ePTFE implants for the face, but certainly many other options are available and have been successful.

### Diagnostic Pitfalls

One of the most common diagnostic problems encountered with chin implants is the correction of a horizontal deficiency in patients who need vertical lengthening as well. Not all of these patients are candidates for implant placement alone. Figure 1 shows a poor aesthetic result that can occur from increasing horizontal length without addressing vertical lengthening. A very unnatural mentolabial fold is produced that trades one deformity for another.

Although some anatomical implants are designed to increase height, they fall short in many cases, in my experience. When significant vertical lengthening is

required, the patient is best served by a sliding genioplasty. The inferior mandibular border is advanced, but it is also distracted and held in place with bone plates

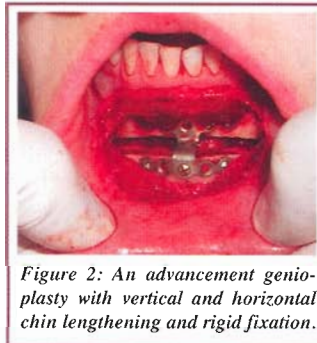


Figure 2: An advancement genioplasty with vertical and horizontal chin lengthening and rigid fixation.

and sometimes filler grafts; this is illustrated in Figure 2. Figure 3 shows a postoperative result of vertical and horizontal lengthening.

### Before & After

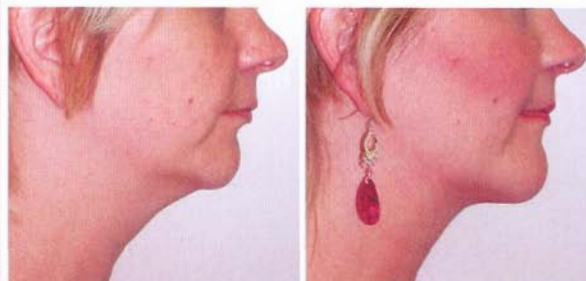

Figure 3: This patient had an improved aesthetic result from a combination of vertical and horizontal lengthening. An unnatural aesthetic result would have resulted with an implant alone.

### Chin-Implant Techniques

Chin implantation can be performed from a submental or intraoral approach. Either is acceptable, and I have not noticed increased infection from techniques using the intraoral approach. It is somewhat amusing that some surgeons rebuke intraoral placement of a chin implant but have no problem placing mid-face implants intraorally.

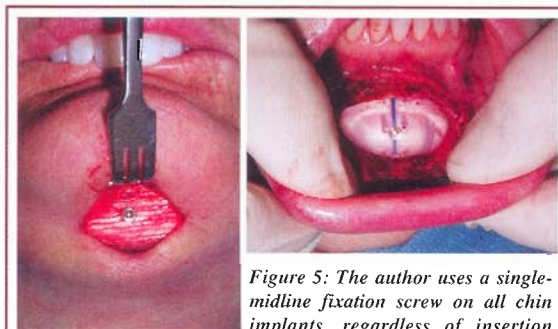


Figure 4: An illustration of the general safety of the mental nerve during subperiosteal dissection at the mandibular border when using a 6-mm periosteal elevator.

Figure 5: The author uses a single-midline fixation screw on all chin implants, regardless of insertion approach.

Using an intraoral approach eliminates submental scars, but it is more disruptive to the mentalis musculature. It is imperative to pay close attention to approximating the mentalis muscles with sutures to avoid lip incompetence with this approach.

The submental approach involves a small incision just inferior to the submental crease adjacent to the periosteum. Both approaches require subperiosteal dissection to the first or second molar areas of the mandible. Regardless of the specific approach, the mental nerves are vulnerable and must be protected. Using a 5- to 7-mm periosteal elevator and keeping the edge of the instrument at the inferior border of the mandible will almost always be inferior to the mental foramen. This technique is shown in Figure 4.

I almost always perform submental liposuction with chin implants. Most patients can benefit from liporecontouring of this area, and I believe it helps the tissue drape over the implant as well.

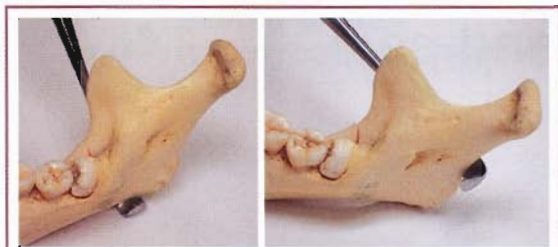
Once the appropriate implant is placed, it is imperative to ensure that the implant tails are lying passively and not folded over or lying below the inferior border

of the mandible. Some patients benefit from long, tapered implant-tail extensions, whereas others do not benefit from the extended augmentation. Even anatomical implants often need further trimming to provide customized results. If the tails are trimmed, it is important to provide a significant bevel for a smooth implant-to-bone interface. Otherwise, the patient will notice a bothersome, palpable defect.

### Fixation

Chin implants can cause bony resorption of the anterior mandible. I have removed implants placed by other surgeons with significant osteolysis that is generally associated with a mobile implant. This is especially true if the implant lies over the thin alveolar bone and can erode into the tooth roots. All implants should be placed over the dense cortical bone of the menton.

## Implants for the Lower Face



**Figure 6:** The use of a "J-stripper" periosteal elevator to free the inferior, angle, and posterior ramus areas for the insertion of mandibular-angle implants.

Many surgeons fix chin implants by suturing to the periosteum or deep tissues. I always use a single rigid-fixation screw in the mandibular midline—regardless of submental or intraoral placement—as shown in Figure 5 (page 32). The orthopedic literature is replete with osteolytic processes secondary to mobile hardware. My clinical experience has shown that this fixation leads to faster healing, less pain, and more predictable implant placement.

### Mandibular-Angle Implants

As stated earlier, mandibular-angle implants are very useful for adding volume and contour to the posterior lower face. Various configurations are avail-

able, and I prefer the implants with a ledge that "catches" the mandible's inferior border and posterior ramus.

When placing these implants, a 1.5-cm incision is made over the ascending ramus to the periosteum, and subperiosteal dissection is performed over the entire ramus, up to the coronoid notch. A critical step when using the stepped implants is medial release of the periosteum on the inferior mandibular border and posterior ramus. This is most easily accomplished with a "J-stripper" periosteal elevator (Figure 6).

For mandibular-angle implants that have significant lateral dimension, it is imperative to position the bulge in the correct position, usually approximating the masseteric muscle mass and actual reconstructed mandibular angle. Placing a transcutaneous needle through the desired skin position can help position the implant properly.

Finally, the implants are fixed with a single screw. The screw can be placed obliquely through the mouth or transcutaneously through a tissue trocar or cannula.

Tissue is closed in multiple layers, when possible, in all implant placements. I also use clindamycin antibiotic irrigation in the implant pocket prior to placement and again prior to closing.

### Complications

Mental-nerve paresthesia is a common sequela of chin-implant placement, but permanent nerve damage is rare when meticulous surgical technique is performed. Most patients will have some temporary dysfunction of the mimetic muscles, especially with an intraoral approach. The dysfunction returns to normal within several weeks, but the patient must be forewarned.

Asymmetry can be a problem if the implant is not fixed or is mobile.

## Implants — Coming of Age

by William G. Binder, MD

**F**or the past few years, Edward Terino, MD, and I have been teaching a continuing medical education course, "Accredited Advanced Sculpting Techniques Using Alloplastic Facial Implants," across the country. However, the "new" trend of facial fillers, whether temporary or permanent, is not a new trend at all.

All of us, as qualified and trained aesthetic surgeons, are seeking methods to rejuvenate the aging face in a manner that provides greater longevity for the patient in a safe and permanent way. We all know that many temporary fillers are available. Whereas those fillers definitely have a place within our practice, a temporary injectable filler is not the answer for the patient who requires a more defined bone structure. That patient will require a facial implant of some type.

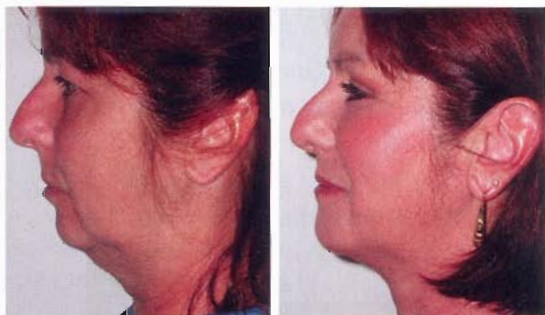During one of our recent courses, James Shire, MD, a board-certified facial plastic surgeon, reported that he places chin implants in approximately 95% of his facelift patients. Joseph Niamtu, DMD, a board-certified oral and maxillofacial surgeon, stated that he provides midface or cheek implants to almost all of his facelift patients. And Geoffrey Tobias, MD, a board-certified facial plastic surgeon who specializes in rhinoplasty, said he often combines chin augmentation to provide symmetry to the patient's face, and in many cases uses nasal implants to build a stronger support for the nose.

Terino is a board-certified plastic surgeon; he and I have been advocates and pioneers in using alloplastic facial implants to sculpt the face and to augment the aging face permanently.

I am excited at how surgeons are finally embracing what has been a 20-year progression for me. The whole concept of bringing youth back to the aging face has gone through many transitions, most of which have been temporary. Now, thanks to better technology in facial implants and the creation of alloplastic facial implants, we finally can provide a procedure that is quicker and faster for the surgeon and provides longevity and safety to the patient.

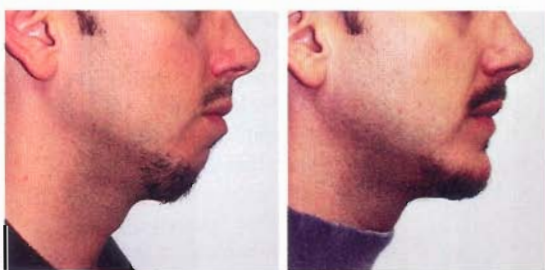*William G. Binder, MD, is a board-certified facial plastic surgeon practicing in Beverly Hills, Calif.*

### Before & After



*This 45-year-old female is shown before and 6 months after submental liposuction and the placement of a large anatomical chin implant. The patient would benefit from rhinoplasty but declined.*

### Before & After



*This 28-year-old male with severe microgenia was treated with a sliding chin osteotomy piggybacked with a large chin implant. He is shown 3 months after surgery. This combination of procedures provided a very aesthetic result probably unattainable by either procedure alone.*

## Implants for the Lower Face

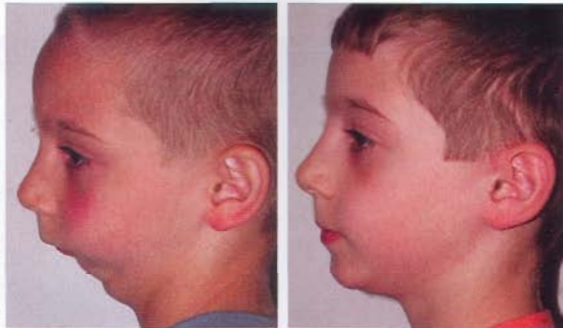One side of the tail (usually the side opposite the surgeon's dominant hand) can be tilted up or down and produce a visible or palpable deformity. Infection can occur regardless of approach.

It is a good idea to obtain a panoramic radiograph of the mandible to rule out dental and related pathology. I have seen several implants become infected because of dental cysts or periodontal disease that could have easily been diagnosed via panoramic x-ray.

If an infection is minor, it may be irrigated and debrided while salvaging the implant. However, significant infections are best treated with implant removal, because bone loss and tissue damage can occur in chronic states.

Lower facial augmentation can be the keystone to lower facial rejuvenation. Many patients have lower-facial-third vertical and horizontal deficiencies, and

### Before & After



*A large chin implant assisted the lower facial aesthetics of this 7-year-old Pierre Robin syndrome patient, shown before and 1 year after surgery. Bilateral costochondral grafts to the temporomandibular joints with the addition of a chin implant served to enhance both function and aesthetics.*

simple implant placement can dramatically improve the aesthetics in this region. Lower facial implants are relatively simple—on one hand, they can be easily removed, and on the other hand, they can provide permanent augmentation. PSP

*Joseph Niamtu III, DMD, is a board-certified oral and maxillofacial surgeon in private practice in Richmond, Va. He can be reached at [niamtu@niamtu.com](mailto:niamtu@niamtu.com).*

## Bibliography

Binder WJ, Bloom DC. The use of custom-designed midfacial and submalar implants in the treatment of facial wasting syndrome. *Arch Facial Plast Surg.* 2004;6:394-397.

Binder WJ, Kamer FM, Parkes ML. Mentoplasty—A clinical analysis of alloplastic implants. *Laryngoscope.* 1981;91:383-391.

Binder WJ, Kaye A. Reconstruction of posttraumatic and congenital facial deformities with three-dimensional computer-assisted custom-designed implants. *Plast Reconstr Surg.* 1994;94:775-785.

Epker BN. Maxillofacial contour esthetic deformities. *Atlas Oral Maxillofac Surg Clin North Am.* 2004;12:75-89.

Godin M, Costa L, Romo T, Truswell W, Wang T, Williams E. Gore-Tex chin implants: A review of 324 cases. *Arch Facial Plast Surg.* 2003;5:224-227.

Niamtu J III. Facial implant applications for cosmetic facial surgery. *Plast Surg Prod.* 1998;8(5):26-29.

Niamtu J III. Advanta facial implants. *Oral Maxillofac Surg Clin North Am.* 2005;17:29-39.

Niamtu J III. Advanta ePTFE facial implants in cosmetic facial surgery. *J Oral Maxillofac Surg.* 2006;64:543-549.

Niamtu J III, Mercuri LM. Silastic implants for temporomandibular disorders. *Plast Reconstr Surg.* 2001;107:290-291.

Taylor CO, Tennier T. Alloplastic augmentation of the mandibular angle. In: *The Art of Alloplastic Facial Contouring*. Terino EO, Flowers RS, eds. St Louis, Mo: Mosby Inc, 2000:183-189.

Zide BM, Boutros S. Chin surgery III: Revelations. *Plast Reconstr Surg.* 2003;111:1542-1550.

PHYSICIANS  
COMPLEX®



- Topical Lip Booster
- Formulated with a vaso dilator and a natural peptide.
- Moisturize, firm, smooth, soften, rejuvenate and protect the lips.
- Available exclusively in a physician's office.
- Retail product for use with or without lip injections.

To place an order,  
please contact:  
**COSMED, Inc.**  
Toll Free 800-826-4480  
e-mail: [sales@physicianscomplex.com](mailto:sales@physicianscomplex.com)

## Increase the Size and Enhance the Color of Your Lips



Before



After 29 days

- Peptides stimulate Collagen and Hyaluronic Acid in the lips after 29 days of continued use.
- Increase blood flow, improve circulation and enhance the color of the lips.

