

Confessions of a Master Blaster

How to use the CO₂ laser in a cosmetic facial surgery practice

By Joseph Niamtu III, DMD, FAACS

The CO₂ laser is a workhorse in the contemporary cosmetic facial surgery practice. New lasers are capable of performing various levels of treatment by using traditional and newer fractional platforms. This gives the surgeon and patient an ever-increasing number of treatment options to suit severity of damage—and balance it with customized recoveries.

Fractional laser-based skin resurfacing has shown promise for a more user-friendly procedure, but to this point it cannot rival the results of traditional, aggressive CO₂ laser skin resurfacing. Progress in this area will surely occur.

Ultimately, the CO₂ laser can also serve as a surgical adjunct for bloodless tissue incision in blepharoplasty and lesion removal, as well as precise endoscopic dissection for brow and forehead lift.

Most of the people reading this article have witnessed several paradigm shifts in their training or practice life. A true paradigm shift occurs when change happens and influences the way things are done from that point forward. Laser technology, Botulinum toxin, and hyaluronic acid fillers are examples that most of us lived without at one time. After the shift happens, it is difficult to think about the way you did something before the technological advances.

Progress can shorten the memory. For example, at one of my recent lectures someone asked me why I kept calling my PowerPoint presentations “slides.” That sort of thing makes you feel old. As today’s children can’t fathom using a printed encyclopedia or even the Yellow Pages, younger surgeons may not realize how much lasers have improved cosmetic facial surgery.

Prior to the advent of CO₂ laser technology, facial resurfacing pretty much meant chemical peel, dermabrasion, and blepharoplasty, and was certainly a more bloody surgery prior to the early 1990s.

Flash-forward to today: Laser technology continues to provide benefits for patients and surgeons and also continues to blossom in terms of progress. Although some cosmetic surgeons do not embrace

laser technology, I can’t imagine my current practice without my CO₂ laser. Along with my ultrapulsed CO₂, I also have a 532- and 940-wavelength as well as an IPL. Although the latter are useful, my CO₂ laser is my workhorse. I refer to it as my “Swiss army knife,” as its applications are broad to contemporary surgery.

FEELING THE BURN

Facial skin resurfacing has undergone

many changes over the past 15 years. Basically, physicians went from aggressive high-fluence, high-density, multipass resurfacing to more gentle fractional treatments. I think this is both good and bad. The new fractional treatments are superb for minor rejuvenation with minor recuperation.

Traditional high-power, high-density, ablative CO₂ treatment produced a burn of the entire skin surface, which is analogous

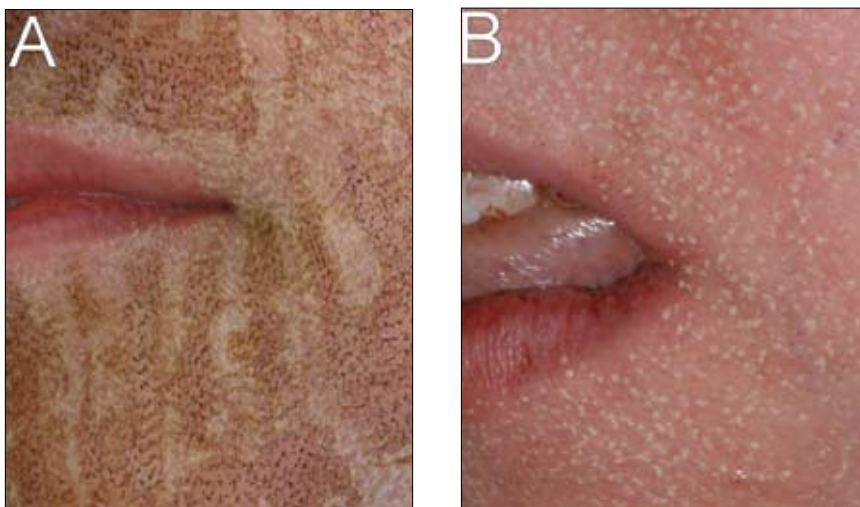


Figure 1A shows traditional high-density full laser skin coverage. Figure 1B shows the subtotal laser coverage of fractional treatment, in which the lasered regions are spaced between nontreated skin.

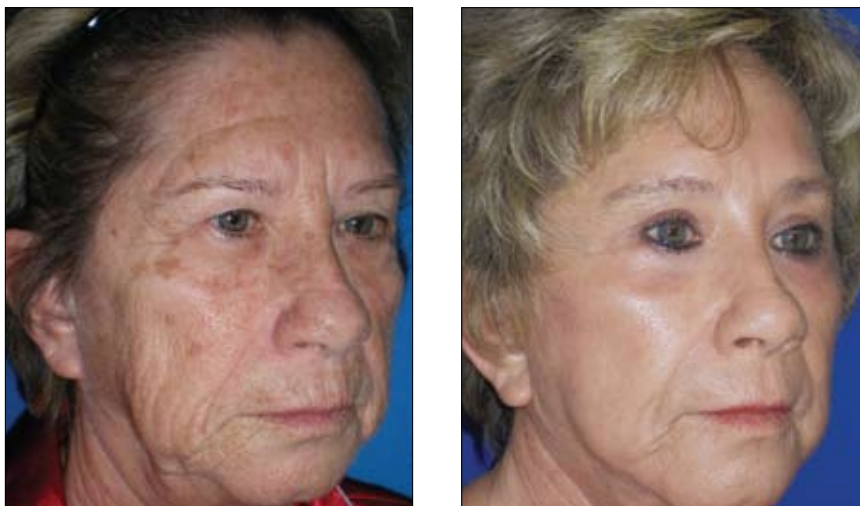

Figure 2. This patient was treated with three high-fluence, high-density nondebrided passes with the CO₂ laser.

to painting a wall with a paint roller—the entire area gets treated. Fractional laser treatment, on the other hand, is a subtotal treatment and leaves untreated regions of normal skin next to micro columns of burned skin. The fractional treatment would be like painting a wall with polka dots instead of the paint roller (Figure 1). Since the entire skin surface is not treated, the entire recovery process is easier and re-epithelialization is faster.

Although the degree of improvement is manifold less than the traditional CO₂ aggressive laser treatment, the recovery is much shorter and tolerable, and the complication rate is lower.

I use Lumenis Inc's ActiveFX (superficial ablative fractional) resurfacing in two main scenarios: younger patients who do not have much aging and damage, and older patients who cannot or will not tolerate extended aggressive CO₂ recovery. Although I think that this level of minimally invasive resurfacing has merit, I also think it has been tremendously overhyped by media and corporate entities. We so badly want to steer patients away from the traditional 2-week aggressive CO₂ laser recovery, we have gotten the cart in front of the horse.

I personally think that the anticipated results of fractional laser are overstated. Granted, a single treatment will provide a mild-to-moderate result with 3 to 5 days of downtime. My problem? I continually hear physicians and media types calling this the new gold standard, which is simply not true. A single minimally invasive fractional laser treatment (regardless of company, wavelength, etc) can't hold a candle to the level of rhytid effacement and dyschromia improvement with an "old school" CO₂ laser device. There is no doubt that the recovery is much easier, but in order to get really noticeable results, the patient may undergo three to five treatments, which in my opinion is a drawback—a single aggressive CO₂ treatment will heal quicker (do the math) and with better results.

In my practice, I use the superficial ablative treatment mostly for those patients who laugh in your face if you suggest a 12-day recovery. The fact that females make up the majority of cosmetic surgery patients—and that many of them are in the workforce and want to look better but have to work—is a good platform for this lighter degree of treatment. My biggest caveat is that you should not overpromise the result, which is a common mistake made by many physicians.

Superficial fractional laser treatments

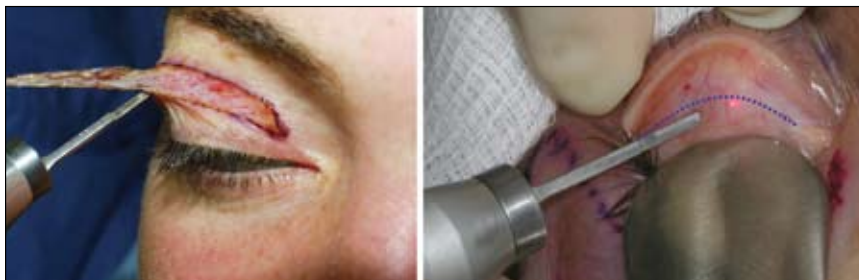

Figure 3. The CO₂ laser provides a bloodless incision modality for upper and lower blepharoplasty.

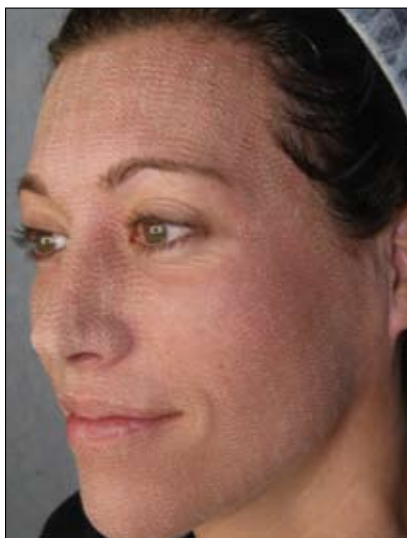

Figure 4. This patient is shown immediately after superficial fractional laser using topical anesthesia only.

can frequently be performed without sedation—a huge advantage for companies and some practitioners. This is useful for practitioners who do not have the training, privileges, or facility to perform IV or general anesthesia with a laser treatment.

I treat 99% of these patients with IV sedation, but will do the occasional patient who insists on topical anesthetic only. The procedure is performed by degreasing the face with acetone and applying a generous coat of BLT topical anesthesia. Most local pharmacies will compound this using 20% lidocaine, 6% benzocaine, and 4% tetracaine. This is left in place for about 45 minutes. A single pass is made over the patient's entire face (and neck, if desired). Typically, I use 100 mJ with a density of 2 for facial treatment and reduce the power to 50 mJ and a density of 2 for the neck region (Figure 4). The entire procedure can be done in 10 minutes on a sedated patient and in about 20 minutes on an awake, topically treated patient.

DEEP RESURFACING

In discussing fractional laser treatment,

the second type of fractional resurfacing I perform is deep fractional ablative CO₂ resurfacing (DeepFX). Although I have not done nearly as many of these treatments as I have traditional aggressive laser, I think it holds promise for situations in which we just cannot use regular ablative CO₂. Examples include scar and wrinkle treatment on darker skin types and the treatment of burn and traumatic scars of the body. Jill Waibel, MD, of Miami has been a leader in using this technology for burn patients, and I believe that this platform will continue to open new doors.

Whereas the superficial fractional treatment is frequently confined to the epidermis, the deep ablative fractional treatment drills the laser beam much deeper into the skin and can penetrate well over a millimeter, although 450 to 600 microns are the most common desired depths.

Treating the entire skin surface with full-surface deep penetration would result in overtreatment, but the fractional nature of the Lumenis DeepFX platform allows normal skin bridges next to deep penetrating laser burns. Again, this subtotal coverage allows for faster healing.

One could say that I have "failed to adapt" in terms of technology, as I am one of those practitioners who still perform a significant amount of "old school," aggressive, high-fluence, high-density, multipass CO₂ laser resurfacing. I remain convinced that this platform remains the true gold standard for wrinkle and scar improvement, as well as dyschromia treatment. Granted, this type of treatment will cost the patient almost 2 weeks of recovery, but to reverse a half a century of aging I still think this is not too much to ask.

When it comes to lasers, you get what you pay for, not in terms of fee but in terms of recovery time. There is no doubt that this traditional type of laser resurfacing is harder on practitioner and patient. The wound care is more intense, and post-laser erythema is inevitable. Complications such as hypopigmentation, burns, scars, and texture changes are definitely a greater

possibility. For this reason, many surgeons have abandoned this level of treatment and settle for lesser clinical results. On the contrary, I am doing more of this level of treatment than ever before and have undertaken numerous steps to make the entire process easier on me, my staff, and, of course, the patient.

These changes have included not debriding the eschar between laser passes and allowing the char to serve as a biologic dressing, which speeds recovery, reduces pain, and lessens postlaser erythema. Additionally, I only use open wound care—all the patient does for the first week of recovery is use petrolatum or Aquaphor. This makes life easier for patient, physician, and staff. Employing technology that is a spin-off of treating Iraq war mustard gas injuries with an amino acid complex oxygen mist also improves postlaser comfort and speeds re-epithelialization.

Figure 5 depicts a case of aggressive, high-fluence, high-density, multipass CO₂ skin resurfacing. When lasering over undermined facelift flaps, I use various options. In general, I treat the central oval (nonundermined regions) with traditional aggressive settings, but greatly respect the undermined flaps. Whereas I may do three passes of 80 mJ and a density of 6 on the central oval, I will use the same fluence but drop to a density of 4 over the flaps. Alternately, I sometimes elect to drop the power to 40 mJ and up the density to 6.

I have performed hundreds of facelifts with simultaneous laser resurfacing. I have not had increased problems with flap viability. The CO₂ laser is also very useful for treating surgical and traumatic—as well as acne—scars, and I use it frequently for that purpose.

BLEPH TREATMENTS

My use of the CO₂ laser is not limited to skin resurfacing. I have performed thousands of laser-assisted blepharoplasty procedures. I have always preferred a bloodless incisional modality, such as Ellman radiowave surgery or CO₂ laser, and I believe that using the CO₂ laser



Figure 5. This patient underwent facelift and aggressive laser over the central oval of the face, with lower-density CO₂ resurfacing over the undermined facelift flaps and neck. The laser enhances the facelift and vice versa.

provides many advantages to the procedure.

We measure Intraoperative bleeding on four eyelids with a Q-tip. There is virtually no hemorrhage when using CO₂ laser incision. Less bleeding means less swelling, less bruising, less postop pain, and faster healing.

I use a 0.2-mm laser handpiece with an 8-watt setting. The skin is excised by following preoperative markings. Generally, I also use the laser to remove an approximately 5-mm strip of orbicularis oculi muscle, and also to incise the orbital septum to access the fat pads in the upper lid. The prolapsed fat can be easily reduced or recontoured using the laser beam without blood loss (Figure 3, page 25).

I use the handpiece at its normal focal length to incise the fat and defocus the laser in order to increase the spot size to contract and shrink fat. Although the laser is excellent for small-vessel hemostasis, it is less valuable for larger-vessel hemorrhage, as the CO₂ chromophore is water and the small beam loses its ability to coagulate in a pool of blood. I always keep a radiowave micro forceps on the tray in case of gross hemorrhage.

For lower-lid surgery, I employ a retroseptal transconjunctival approach and incise the conjunctiva and capsulopalpebral fascia to access the prolapsed lower fat pads. The incision is made about 4 mm inferior to the lower tarsus from the canthus to the lacrimal punctum (Figure 3, page 25).

Additionally, the CO₂ laser can be utilized in endoscopic brow and forehead lift. A long laser waveguide attaches to the straight handpiece and allows extreme precision in incising tissue in the endoscopic optical pocket. I primarily use the laser waveguide to incise the supraorbital periosteum and disrupt the procerus, corrugator muscles, and lateral orbicularis muscles. ■

Joseph Niamtu III, DMD, FAACS, is a board-certified cosmetic surgeon in Richmond, Va. He can be reached at niamtu@niamtu.com.

Postlaser Wound Care—Past and Present

If there is one drawback in employing traditional CO₂ ablative laser resurfacing, it is the area of postlaser wound care. It adds extra layers of work (and sometimes frustration) for the patient, surgeon, and staff. If the process and experience of postlaser wound care could be ultimately simplified, the promoting of traditional CO₂ treatments would be much easier.

I know several experienced laser surgeons who have abandoned the procedure because of the intensity of the wound care and the hand-holding required to get the patient through it successfully.

Inducing an intentional and controlled second-degree facial burn removes the entire epidermis and part of the dermis. This is obviously a giant insult to the normally intact integument. Patients who undergo fully ablative, high-fluence, high-density, multipass CO₂ laser resurfacing have to understand in the preop period that this treatment will be their hobby for 4 to 6 weeks. I am very blunt with my patients who are considering this type of laser treatment, and I do not sugarcoat the recovery.

Incidentally, for new practitioners, understating a recovery from laser treatment—or any procedure, for that matter—can really come back and bite you in the foot. In an era of new “miracle” treatments and surgeries emerging daily, some surgeons feel compelled to downplay the patient-recovery phase of treatment in hopes of “selling” a procedure. There is no better way to infuriate a patient than to tell them that a 2-week recovery is 1 week, etc. Not only does it upset them, it can cost them in other ways, such as missed work and other scheduled events, and disrupt family life in general.

I tell my patients that they won't like me for a week, that they will need about 2 weeks before they can get back in makeup, and that they will be pink for several more weeks. If I tell them the recovery is 14 days and it takes only 10 days, I am a hero. If I tell the inverse, I am a zero.

Understating a recovery is unethical and promotes negative marketing. I have seen too many instances in which a physician says 1 week for a 2-week