

PSP

PLASTIC SURGERY PRODUCTS
SOLUTIONS FOR YOUR PRACTICE

PlasticSurgeryProductsOnline.com

OCTOBER 2006

The Educator

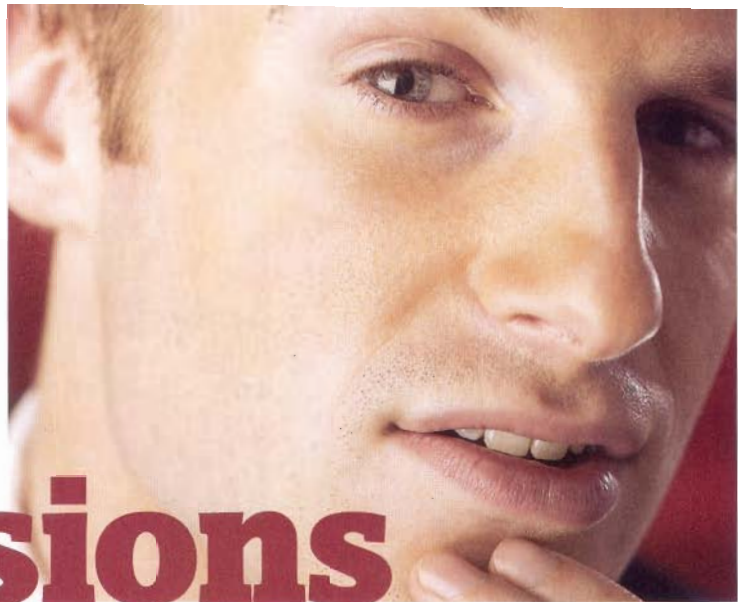
Malcolm D. Paul, MD, FACS,
values learning and teaching

Skull Reconstruction

**Breast-Augmentation
Revision**

**Special Section:
Pro Bono Plastic Surgery**

#BXNDYXS *****AUTO**5-DIGIT 23235
#225601012 1# SP 200 566 PFC1#
JOE NIAMTU 32676
NIAMTU IMAGING SYS PD201
10230 CHEROKEE RD
RICHMOND VA 23235-1108



by Joseph Niamtu III, DMD

Lasers for Lesions

Treat vascular and pigmented lesions of the head and neck effectively with lasers that deliver 532- and 940-nm wavelengths

Today's patients are very sophisticated and, largely due to the Internet, may have as much knowledge as the clinician—or more—about a given procedure or device. These well-informed patients know what they want and often seek practitioners by technology level, especially when they seek treatments with lasers and other light-based devices.

Lunchtime procedures are in great demand; unfortunately, many nonablative or minimally ablative procedures fail to provide significant results.¹⁻⁵ The treatment of red and brown lesions with a combination device using 532-nm and 940-nm wavelengths is truly a lunchtime procedure that produces impressive results on a wide variety of lesions.

Dealing with ectatic vessels, birthmarks (such as port-wine stains), hemangiomas, tortuous veins, and related facial lesions has been a challenge in the past. These lesions have been treated with sclerosing solutions, cryotherapy, radiofrequency needle ablation, surgical excision, and other therapies. It was not until the

advent of lasers and the application of the theories of selective thermolysis and thermal relaxation time that the treatment of vascular lesions advanced.

Selective photothermolysis was introduced by Anderson and Parrish in 1983⁶; they presented the theory that various targets—chromophores—could be selectively destroyed by specific wavelengths and pulse durations, with minimal damage to surrounding tissue.

The target for vascular lesions is oxyhemoglobin. Its primary absorption peaks are at approximately 418, 542, and 577 nm in the visible spectrum, and there is a secondary absorption peak at 940 nm in the near-IR spectrum (Figure 1).

Thermal relaxation time (TRT) is defined as the time required for an injured target to cool to half of its peak temperature immediately following laser irradiation. Having a pulse duration that is shorter than the TRT of the treated vessel prevents the energy from dissipating very far beyond the targeted vessel. This means that the heat generated by each pulse of the laser is confined to the targeted blood vessels and is dissipated before it can spread laterally to normal tissue.

Combining these ideas led to the development of laser technologies that are safe and effective for treating vascular lesions. Some of the earliest laser treatments for facial telangiectasias were performed using continuous-wave carbon dioxide (10,600-nm) and argon (488- and 514-nm) lasers.⁷ Although successful outcomes were reported, these lasers destroyed the ectatic vascular tissue, as well as the overlying epidermis, in a nonselective fashion. These lasers were, in effect, sophisticated forms of electrocautery.

The theory of selective photothermolysis spurred the development of flashlamp-pumped, pulsed-dye, and copper-vapor lasers. These lasers emit light at 577 to 585 nm—wavelengths that are selectively absorbed by oxyhemoglobin—and can destroy the ectatic vessel with minimal damage to the underlying tissue.

The pulsed-dye laser differs from older lasers by emitting light in pulses rather than in a continuous beam. The 585-nm flashlamp-pumped, pulsed-dye laser has become the gold standard by which other vascular lasers are judged. The flashlamp-pumped, pulsed-dye laser has the significant drawback of post-treatment purpura, which is difficult to conceal and can persist for as much as 14 days.

Newer laser technology has led to the use of ultralong-pulse 585-nm lasers that eliminate postlaser purpura. Although the pulsed-dye lasers are effective and versatile, they are heavy (more than 136 kg), not portable, and expensive.

The 532- and 940-nm Wavelengths

Just as transistors made vacuum tubes obsolete, semiconductor diode-pumped lasers are replacing vacuum tubes and flashlamp-pumped lasers. The dual-wavelength (532- and 940-nm) laser system is lightweight and portable—about the size of a videocassette recorder. The laser weighs 8 kg and uses standard 120-V alternating current (Figure 2, page 40).

The 532-nm wavelength light is generated by a high-powered diode laser at 808 nm; this is used to optically pump a neodymium-doped yttrium aluminum garnet (Nd:YAG) crystal to produce 1064-nm light. This light is then focused

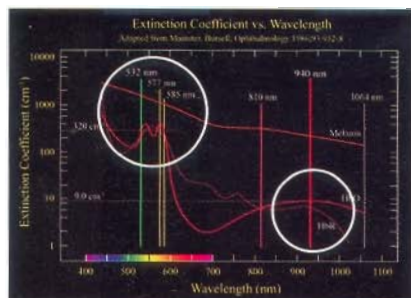


Figure 1: Absorption peaks for oxyhemoglobin and a secondary peak close to 940 nm in the near-IR spectrum. Smaller, superficial veins are better treated at 532 nm; larger or deeper vessels are better treated at 940 nm.

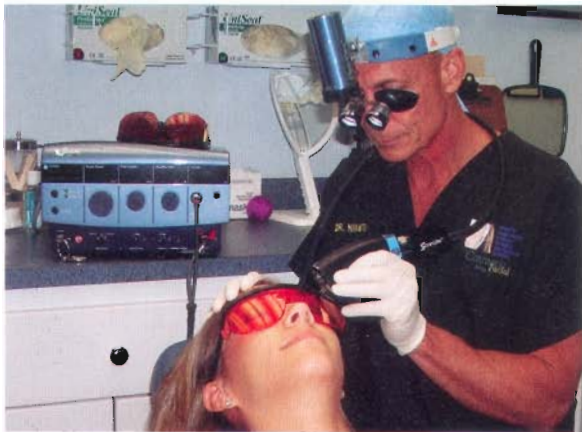

Figure 2: The new dual-wavelength, solid-state lasers are compact, lightweight, and portable.

on a potassium titanyl phosphate crystal to double its frequency. This halves the wavelength, producing the final 532-nm radiation.

Practitioners who are experienced with the 532-nm diode laser are familiar with the immediate disappearance of the ectatic vessel after laser-light exposure. With the longer 532-nm diode laser pulses, the blood is more gently heated and damages the endothelial cells, but it does not burst the vessel, as evidenced by the lack of purpura.

There are theories that the laser energy creates a small steam bubble that expands along the axis of the vessel, clearing the lumen and pushing a column of hot blood along the vessel. As the vessel cools during its TRT, the vapor bubble condenses and collapses the vessel wall. Thermal coagulation of the blood, now ejected well beyond the actual exposure site, creates an intravascular plug, leaving an empty, thermally damaged lumen at and around the site of the laser exposure.⁷

The 940-nm wavelength is a little used, but very useful, tool for treating vascular lesions, especially larger, bluer, and more resistant red lesions. High-absorption 532-nm treatments are preferred for smaller and more superficial vessels. Superficial and small-diameter vessels are

most selectively treated using wavelengths that are strongly absorbed by oxyhemoglobin, because the vessels can be heated to clinical response temperatures with minimal incident energy.

High oxyhemoglobin absorption can, however, limit the depth to which laser light penetrates the skin, making it difficult to treat large or deep vessels with these wavelengths. When treating small, superficial vessels that primarily contain oxygenated hemoglobin, it is beneficial to use a wavelength near one of these primary absorption peaks.

Larger and Deeper

When treating larger or deeper vessels containing both oxygenated and reduced hemoglobin, or when absorption by epidermal melanin is a concern, there are significant benefits from treating at 940 nm, which targets the secondary absorption peak of oxyhemoglobin and reduced hemoglobin (Figure 1).

The 940-nm wavelength is emitted

more uniformly heat through larger-diameter vessels.

Reduced hemoglobin absorption falls rapidly above about 950 nm, and 940 nm is the longest wavelength for which reduced hemoglobin has good absorption (Figure 1). Thus, the desired goal of the 940-nm treatment is to use the longest effective wavelength for both oxyhemoglobin and reduced-hemoglobin absorption, while avoiding absorption by water.

Having a single laser with both of these wavelengths is a clinical benefit. Both wavelengths can be used without changing the handpiece; the operator simply turns a switch to change from 532 nm to 940 nm. Dual-wavelength lasers allow the selection of multiple handpieces that can be used with both 532-nm and 940-nm treatment wavelengths. Spot sizes are available in 0.7, 1, 1.4, 2, and 2.8 mm (Figure 3).

Computer-pattern generators (CPGs) are available that produce up to 50 pulses per second. The generator delivers 700- μ m treatment spots that are placed on 875- μ m, 1-mm, or 1.17-mm centers to center spacing over a 2-cm² treatment area. This precisely controlled spacing leaves small untreated volumes surrounding each treatment spot. These volumes act as thermal-dissipation zones during

treatment, allowing the use of higher energies in the treatment spots for more clinical effect.

After treatment, the untreated zones become healing centers distributed throughout the entire treatment area, allowing

rapid healing and giving maximum rejuvenation similar to that predicted by the fractionated-resurfacing theory.

The CPG patterns give 60%, 45%, or 30% skin coverage per treatment. For clinicians used to the mundane task of tracing individual telangiectasias, the CPG is a welcome implement that allows much faster treatments, simplifies a boring procedure, and seems to be less painful to the patient.

The CPG has resurfacing capabilities and can also be used for full-face treatments to improve skin blemishes (producing a more uniform skin texture and tone) and to treat large-area lesions, including poikiloderma, port wine stains, and matted telangiectasias. The CPG with controllable spot size, configuration, and

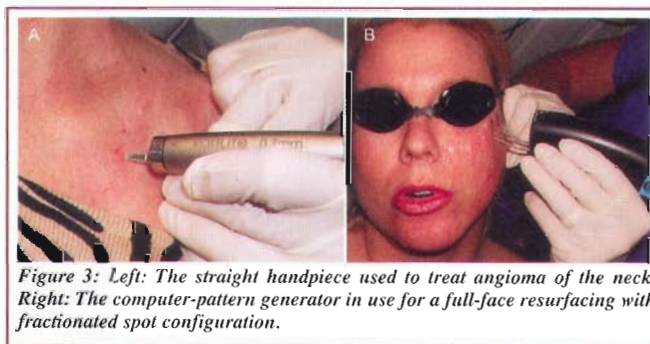
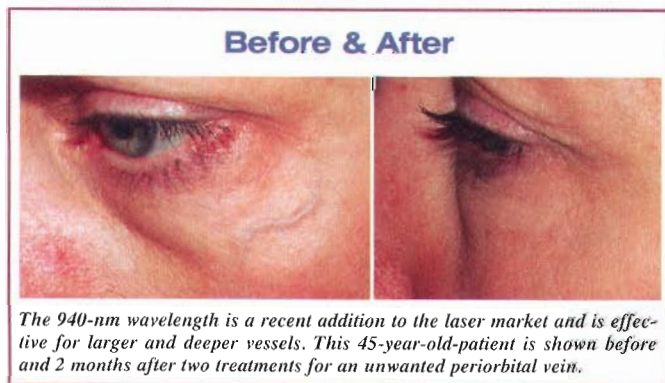

Figure 3: Left: The straight handpiece used to treat angioma of the neck. Right: The computer-pattern generator in use for a full-face resurfacing with fractionated spot configuration.

directly from a customized indium gallium arsenide diode laser and is chosen for larger and deeper vessels primarily because it is exactly at the peak of the secondary absorption band of oxyhemoglobin in the near-IR region of the spectrum. Since the target is venous blood, it is also important to consider the reduced hemoglobin absorption spectrum. Less strongly absorbed wavelengths penetrate more deeply, and can



The 940-nm wavelength is a recent addition to the laser market and is effective for larger and deeper vessels. This 45-year-old-patient is shown before and 2 months after two treatments for an unwanted periorbital vein.

Lasers for Lesions

dermatosis papulosa nigra, lentigines, nevi, and macules, the straight handpiece provides a controlled spot size of various diameters. For larger lesions, such as those of rosacea, poikiloderma, melasma, and generalized facial-pigment resurfacing, the CPG is superior and significantly reduces treatment time by covering more ground.

With the single handpieces in the 532-nm mode, the vessels are merely traced and the operator watches as they disappear (Figure 3). It does not seem to make a difference whether the laser is started proximally or distally to the ectatic vessel.

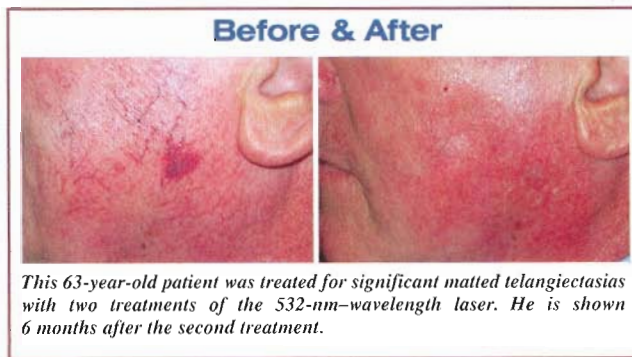If a vessel is resistant to the 532-nm wavelength, a flip of the switch brings in the "big gun": the 940-nm wavelength. This handpiece is used somewhat differently. Instead of tracing along the entire vessel, as is done at 532 nm, the 940-nm laser is used to strike the vessels at varying points along their length.

When a given lesion is hit by a 940-nm pulse, this often occludes the vessel several millimeters distally. This means that the vessel can be treated with fewer pulses at this wavelength. For small red lesions, a single pass is adequate. For larger red or blue vessels, two passes may be required. The author has treated larger, tortuous facial veins with multiple sessions at the 940-nm wavelength.

Pigmented Lesions

The absorption spectrum of melanin includes the UV, visible, and near-IR portions of the electromagnetic spectrum. Because of this, virtually every wavelength along the spectrum can theoretically be used to target melanin. Melanosomes are much smaller than blood vessels, and a much shorter pulse duration is required than for telangiectasias.

Pigmented lesions such as lentigines, keratoses, ephelides, and dermatosis



This 63-year-old patient was treated for significant matted telangiectasias with two treatments of the 532-nm-wavelength laser. He is shown 6 months after the second treatment.

papulosa nigra are successfully treated with the 532-nm wavelength. Early hypertrophic scarring and keloids that possess significant neovascularity are also successfully treated.

For most macular lesions, such as lentigines, the end point is a uniform gray color and a popping sound that occurs when a tissue becomes plasmoid. The pigmented lesions exfoliate over 1 to 2 weeks. Larger or thicker lesions may need retreatment until clinical clearing is achieved.

Anesthesia and Complications

Because the pain sensation is similar to a rubber-band snap or an injection with a 32-gauge needle, the vast majority of patients presenting for red or brown lesions do not require any supplemental anesthesia. Refrigerated aloe gel provides a heat sink, mitigates the discomfort, and is routinely used. Topical anesthetic creams can also be used.

Areas such as the nostrils, alar bases, columellar area, lips, and perioral region can be very sensitive, and supplemental local anesthetic blocks or infiltration can be used to obtund this discomfort.

Any light-based treatment device can cause complications.^{9,10} Overtreatment that results in skin blistering and hypopigmentation is a potential, but infrequent, problem. Because the 532-nm wavelength targets both, hemoglobin and melanin (reds and browns) are affected. This can be problematic when treating darker skin types or individuals with suntans. The 532-nm wavelength has the potential to destroy the melanocytes on the way to the hemoglobin.

For this reason, care must be used

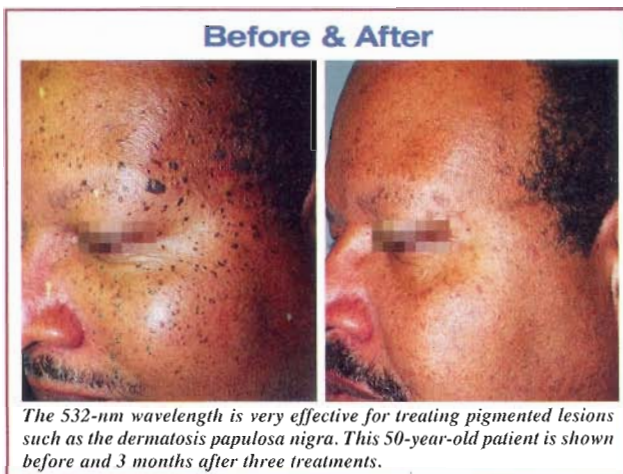when treating larger areas with skin of color or suntan. Crusting occasionally results from treatment and is treated with triple antibiotic ointment. As with any device, it is better to undertreat during multiple sessions than to overtreat in a single session.

Today's knowledgeable patients demand skin treatments with big results and little downtime. The combination of 532-nm and 940-nm wavelengths in solid-state lasers answers both of these calls. These wavelengths make the removal of telangiectasias and pigmented lesions truly a lunchtime procedure. They provide a wide array of treatment options, and they are portable, predictable, and safe. **PSP**

Joseph Niamtu III, DMD, is a board-certified oral and maxillofacial surgeon in private practice in Richmond, Va. He can be reached at niamtu@niamtu.com.

References

1. Niamtu J. Non-ablative technologies. *Lasers Surg Med.* 2004;34:203–204.
2. Niamtu J. Laser treatment of vascular and pigmented lesions. *Oral Maxillofac Surg Clin North Am.* 2004;16:239–245.
3. Niamtu J. Clinical applications of the 532-nm diode laser for the treatment of facial telangiectasias and pigmented lesions: literature review, history and discussion of clinical experience. *Am J Cosmetic Surg.* 2001;18:71–81.
4. Niamtu J. The treatment of facial telangiectasias. *Oral Maxillofac Surg Clin North Am.* 2000;12:771–780.
5. Goldman MP, Bennett RG. Treatment of telangiectasia: A review. *J Am Acad Dermatol.* 1987;17:167–182.
6. Anderson RR, Parrish JA. Selective photothermolysis: precise microsurgery by selective absorption of pulsed radiation. *Science.* 1983;220:524–527.
7. Landthaler M, Hohenleutner U, Abd el Raheem TA. Therapy of vascular lesions in the head and neck area by means of argon, Nd:YAG, CO₂ and flashlamp-pumped pulsed dye lasers. *Adv Otorhinolaryngol.* 1995; 49:81–86.
8. Alderson MR. Spider naevi—Their incidence in healthy school children. *Arch Dis Child.* 1963;38:286–288.
9. West TB, Alster TB. Comparison of the long-pulsed dye (590–595 nm) and KTP (532 nm) lasers in the treatment of facial and leg telangiectasias. *Dermatol Surg.* 1999;24:221–226.
10. Niamtu J. Common complications of laser resurfacing and their treatment. *Oral Maxillofac Surg Clin North Am.* 2000; 12:579–593.



The 532-nm wavelength is very effective for treating pigmented lesions such as the dermatosis papulosa nigra. This 50-year-old patient is shown before and 3 months after three treatments.